

Case Report

Schwannoma of Intercostal nerve- An Uncommon Localization

Dr.K.Senthil Kumar*, Dr.R.Anantharamkrishnan**

*Assistant Professor, **Associate Professor, Dept. of General Surgery, Chettinad Hospital and Research Institute, Chennai, India.



Dr.K.Senthil Kumar M.S., FMAS., FIAGES., Dip in Lap, is an Assistant Professor in the Department of Surgery, Chettinad Hospital and Research Institute. He did his M.B.B.S in PSG Institute of Medical Sciences and Research and postgraduation in Coimbatore Medical College. He joined Chettinad Hospital and Research Institute in 2009. He has done Fellowship in minimal access surgery. He has attended many state and national conferences and presented interesting clinical cases and case studies in surgery. He is a member of Asia Pacific Hernia Society and his fields of interest are Urology and minimal access Surgery.

Corresponding author - Dr. K.Senthil Kumar (drsenthil_psg@yahoo.co.in)

Abstract

Schwannomas are benign slow growing tumors arising from Schwann cells that sheath the nerves. They can occur anywhere in the body, but generally found arising from cranial or spinal nerve roots. A rare case of 32 year old man presenting with a swelling in the left costal region diagnosed clinically as a benign soft tissue swelling is reported here. A possibility of intercostal nerve schwannoma was suspected on imaging and confirmed by histopathology following surgical resection.

Key words : Schwannoma, Intercostal nerve, Peripheral nerves

Chettinad Health City Medical Journal 2013; 2(3): 92-93

Introduction

Schwannoma is the commonest type of intraneural tumour. It typically comes from a single bundle (fascicle) within the main nerve and displaces the rest of the nerve. Peripheral nerve involvement are rare, 25 to 45% occurring in the head and neck region¹. Involvement of chest wall is extremely rare of which less than 10% affects the intercostal nerve. Primary neural tumors of the chest mostly arise in the mediastinum, usually asymptomatic diagnosed incidentally on x-ray of chest².

Histologically two types of cellular pattern are noted. Antoni A, where there are well developed cylindrical structures which on cross section produce a palisading pattern of nuclei around a central mass of cytoplasm (Verocay body) and Antoni B, where there is a loosely arranged stroma in which the cells form no distinctive pattern.

Case Report

A 32 yr old male patient presented to the surgery outpatient department of a tertiary care hospital with complaints of a swelling in the left lateral chest wall for the past 10 years. The swelling gradually increased in size and was not associated with pain or fever. There was no history of trauma to the chest wall in the past. Clinical examination of the cardiovascular, respiratory, abdomen and nervous system were unremarkable. Local examination of the left chest wall revealed a subcutaneous swelling of 8cmx5cmx5cm dimensions over the regions of 9th and 10th ribs (Figure 1). It was not tender but firm in consistency with smooth surface and mobility was restricted in horizontal plane. His routine blood investigations were within normal limits.

Ultrasound revealed a large well defined 8x4.1x3.7cms size, mixed echogenic - predominantly hypo echoic mass along the lateral aspect of lower chest in the muscle plane and superficial to ribs suggestive of soft tissue tumor.

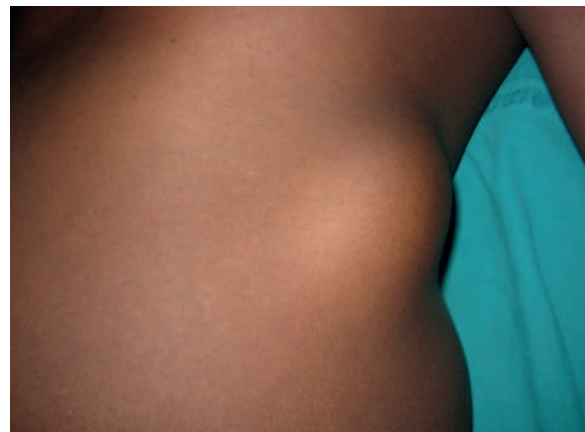

Fig1: Clinical picture of left chest wall swelling

CT scan of chest showed a 66mmx43mmx63mm (cc x rl x ap) well encapsulated, heterogeneously enhancing oval soft tissue density arising from lower left lateral chest within the intercostal muscle plane at level of lateral aspect of 9th and 10th ribs (Figure 2). Underlying bone and adjacent fat planes appeared normal. There was no evidence of intrathoracic or intra abdominal extension. Features suggestive of benign soft tissue tumor noted with possibility of intercostal nerve schwannoma was considered.

Under General anesthesia, skin incision was made and dissection was carried out. A single grey white soft tissue encapsulated mass measuring about 8x4x3.5cms was excised in toto (Figure 3) and sent for

histopathological analysis. Location of the lesion was consistent with the imaging studies. At one end of the lesion there was a small nerve tissue entering into the intercostal muscle plane. Suction drain was placed and removed during the third post op day. Post operative period was uneventful.

Histopathology examination of the specimen showed an encapsulated tumor composed of Antoni A and Antoni B areas consistent with Schwannoma. (Fig.4)

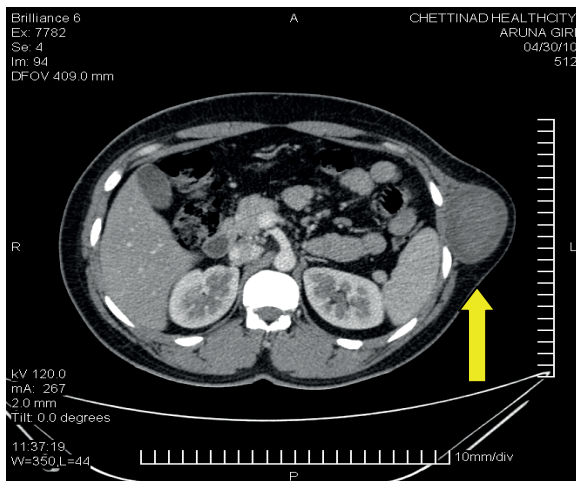
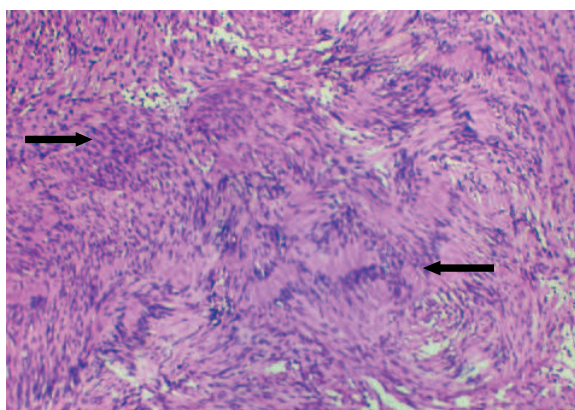


Fig 2: CT image showing a left extrathoracic swelling

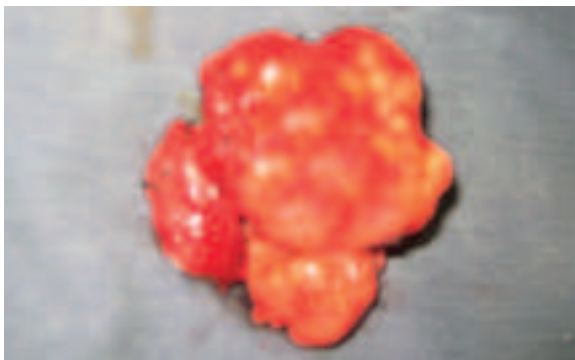

Fig 3: Gross specimen showing a well encapsulated mass



Microscopic picture of schwannoma showing prominent nuclear palisading (H&E, 100X)

Fig 4: Histopathology showing Antoni A (→) & Antoni B (←) Bodies

Discussion

Schwannomas are commonly found in adult in association with the vestibulocochlear nerve. Results from three large case series of 328 cases of thoracic neural tumours concluded that 90 % of thoracic neurogenic tumors originate in the mediastinum, especially in the posterior mediastinum and only 5% from intercostal nerves. Schwannomas are considered to be the second common intrathoracic neural tumour^{3,4}. However, in our case the lesion was presenting externally with no intrathoracic extension. Schwannomas are usually asymptomatic until they grow large enough to cause compressive lesions. When symptomatic, they cause pain along distribution of the nerve involved. In the present case discussed the tumour grew externally, hence remained asymptomatic and presented itself as a soft tissue swelling.

In conclusion, in patients presenting with a soft tissue swelling in the chest wall along the distribution of intercostal nerves, schwannoma should be considered as one of the differential diagnosis. Computed tomography to rule out or identify peripheral tumors of intercostal nerve should be considered when in doubt. Local excision is the treatment of choice in small lesions without internal extension³.

Acknowledgements

We gratefully acknowledge the departments of Pathology, Radiology & Anaesthesia for their contribution in diagnosis and treatment of the patient.

References

- 1) Colreavy MP, Lacy PD, Hughes J, et al. Head and neck schwannomas - a 10 year review. *Journal of Laryngology and Otology*. 2000; 114(2):119-124.
- 2) Homayoun Khanlou, Négar Khanlou, Glenn Eiger. Schwannoma of posterior mediastinum: A case report and concise review. *Heart and Lung The Journal of Acute and Critical Care* 1998; 27(5): 344-347 .
- 3) James H. McClenathan, MD, and Richard J. Bloom. Peripheral Tumours of the Intercostal Nerves. *Ann Thorac Surg* 2004; 78(2):713-714.
- 4) Fengshi Chen, MD, Ei Nakayama, MD, Kenichi Okubo, MD, Hiroshi Date, MD. Intrathoracic multiple schwannomas of a single intercostal nerve. *Ann Thorac Surg* 2008; 86(2):660-661 .