

Original Article

Endoscopic Posterior Nasal Neurectomy for Rhinorrhea

* Vinod Felix, Ammu Sreeparvathi, Narendrakumar V, Dhanya Vijayan

*Sree Uthradom Thirunal (SUT) Hospital, Pattom, Trivandrum, Kerala, India.



He currently works as the senior consultant in ENT Dept at SUT Hospital, Pattom, Trivandrum, Kerala. He is also a honorary consultant in aEndoscopic skull base surgery , at Sree chitra institute of Medical sciences. He passed his MBBS in 2003 from Madurai medical college and pursued his MS ENT, from Upgraded Institute of Otorhinolaryngology, Madras medical college in 2008. He later on got trained in Endoscopic skull base surgery, from Italy.

Corresponding author - Vinod Felix (dr.vinodfelix@gmail.com)

Chettinad Health City Medical Journal 2015; 4(4): 164 - 166

Abstract

Allergic rhinitis and vasomotor rhinitis are effectively treated by vidian neurectomy but it is presently seldom used because of its high incidence of complications like dry eye, cheek and gums, numbness and eye movement disturbances. This emergence the endoscopic posterior nasal neurectomy for rhinorrhea patients, in which resection of the postganglionic parasympathetic nerve fibres (posterior superior nasal nerve) are done under clear vision using aid of endoscope without any major complications. This technique gives equal effective result as of vidian neurectomy.

Key Words: Rhinorrhea, Allergic rhinitis, Vasomotor rhinitis, Posterior nasal

Introduction

Rhinorrhea occurs in allergic rhinitis and vasomotor rhinitis. Fortunately most of these patients respond well to medical treatment. Surgical treatment is needed only when medical treatment fails. Golding-Wood¹ first described Vidian neurectomy in the 1960s for the treatment of allergic and vasomotor rhinitis. Due to high incidence of complications like disturbed lacrimal secretion and numbness of the cheek and gums, this procedure is seldom used at present. So, alternative to this in 1983 Terao et al² described cryosurgery on the posterior superior nasal nerve at the sphenopalatine foramen and submucosal resection of the posterior superior nasal nerve and sphenopalatine artery using ultrasonic coagulation has been reported³. But intraoperative bleeding from the sphenopalatine foramen is a risk in these techniques because the artery is not resected under direct vision. Then Kikawada⁴ in 1997 successfully reported an endoscopic technique that resects the posterior nasal nerve near sphenopalatine artery at the sphenopalatine foramen and can control intraoperative bleeding under direct vision, which gives better results by avoiding the complications of vidian neurectomy.

The posterior nasal nerve is a peripheral branch of the vidian nerve, entering the nasal cavity through the sphenopalatine foramen after bifurcation of the nerve into the lacrimal gland.

The posterior superior nasal nerves divide further to become the lateral and the medial posterior superior nasal nerves. The lateral posterior superior nasal nerves innervate the superior, middle, and inferior conchae and the superior and middle meatus. Other parasympathetic nerve fibers of the nose branch off from the greater palatine nerve and enter the nasal cavity through the canaliculi of the perpendicular plate of the palatine bone as the posterior inferior nasal nerves.

These nerves innervate the inferior turbinate and the inferior meatus⁴.

Operative procedure.

Anesthesia - This procedure can be done either under general anesthesia or local anesthesia. But due to possibility of bleeding from sphenopalatine artery, general anesthesia is preferred at our center.

Positioning - Supine posture with reverse trendelenberg position, to decrease venous return. Endoscope- 'o' degree 4 mm rigid endoscope is used, along with a high definition camera.

Infiltration - 0.5 to 1 ml of 1: 2,00,000 adrenaline solution is injected in the lateral nasal wall, on the posterior part of middle meatus, just behind the posterior fontanalle ,using a 25 spinal needle.

Incision - 'L' shaped incision is made(Fig 1). The posterior end of posterior fontanalle is identified by palpation. Just behind this a vertical incision is made on the lateral nasal wall, running all the way down till the attachment of inferior turbinate. Horizontal incision of about 5 mm is made from the lower end of vertical incision, directed posteriorly. The incision can be made with 15 blade, or a flag knife used in micro ear surgery. However we prefer the needle tipped electrocautery/ colarado needle for the same, so that we can avoid the ooze from incision site.

Identifying posterior nasal nerve - The mucoperios-teum is raised gently using a cottle's septal elevator or a suction freer elevator, after making the incisions. Care must be taken not to injure the sphenopalatine vessel during flap elevation. The peripheral part of the posterior nasal nerve can be usually identified just behind the incision, about 5 mm anterior and inferior to sphenopalatine foramen(Fig 2). However it is always better to identify the main trunk or the proximal part of posterior nasal nerve at the sphenopalatine foramen, where the

nerve lies anterior to the vessel (Fig 3). We advocate this because; the nerve may divide further after its exit into nasal cavity, through the sphenopalatine foramen. The surgeon stands a chance of missing, a branch if the peripheral part of nerve is targeted instead of the proximal one near the sphenopalatine foramen. After identifying the nerve, they are cauterized using a bipolar cautery and cut using microscissors. It is essential to do this procedure on both sides.

Closure - The mucoperiosteal flaps are reapproximated, and covered with surgical. No nasal packing is done. Patients are discharged on the same day.

Complications

We did not encounter any complications in our series of 18 cases done, between 2012 to 2015.

Outcomes

All the 18 patients, who underwent this surgery in our centre had satisfactory relief of their rhinorrhea, over a follow up period of 15 months. This was evaluated with sinonasal outcome questionnaire. Sneezing also improved, but it recurred after 8 months though not worse as it was before surgery, and needed additional antihistamines or steroid sprays to control it better.

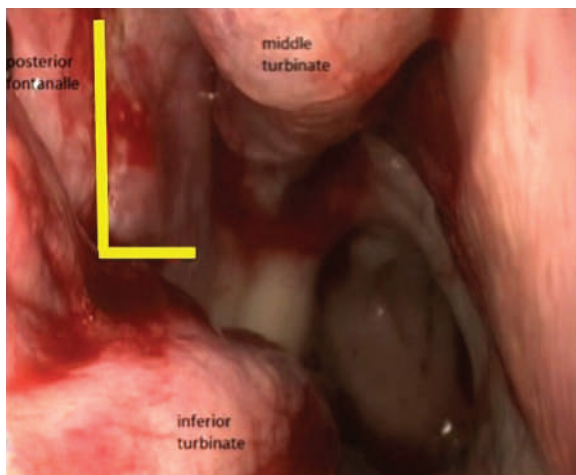


Fig 1 - Right Posterior Nasal Neurectomy- Incision

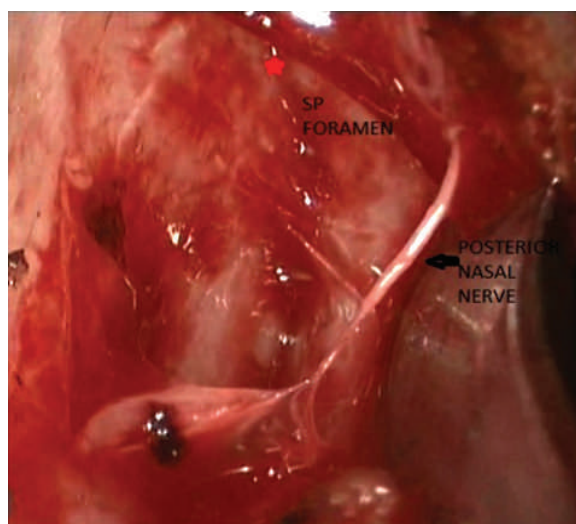


Fig 2 - Peripheral Part Of Posterior Nasal Nerve Identified On Raising The Mucosal Flap

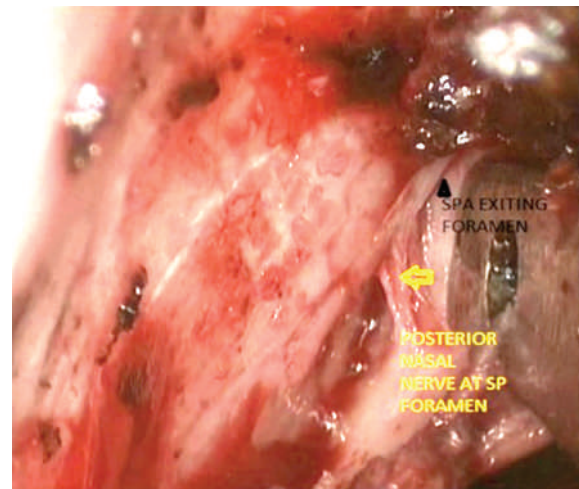


Fig 3 - Proximal Part Of Posterior Nasal Nerve At Sphenopalatine Foramen, Anterior To Sphenopalatine Artery

Discussion

Resection of the posterior nasal nerve is especially effective for severe rhinorrhea patients because the interruption of parasympathetic nerve fibers suppresses nasal secretion. As it also contains afferent sensory fiber supplying the posterior half of the mucosa in the nasal cavity, sneezing can be reduced, thus making this procedure superior to Vidian neurectomy⁶.

Malcomson⁷ showed conclusively that stimulation of the parasympathetic or interruption of the sympathetic nerve supply to the nasal mucous membrane caused vasodilatation, hypersecretion and sneezing, and hence it is reasonable to assume that under normal conditions there exists a balance between the two systems. The effectiveness of this technique is accompanied by decrease in local inflammatory cell infiltration and the related cytokine production⁸.

Conclusion

Endoscopic posterior nasal neurectomy is easy and less invasive procedure, which can reduce not only nasal obstruction but also sneezing and rhinorrhea⁶. The surgeon can have clear direct vision of the posterior nasal nerve and sphenopalatine artery during the operation, facilitating excellent safety, reliability and provides better result than vidian neurectomy⁹.

The authors declare no conflict of interest.

References

- 1) Golding-Wood PH: Observations on petrosal and vidianneurectomy in chronic vasomotor rhinitis. *J Laryngol Otol.* 75:232-247, 1961.
- 2) Terao A, Meshisuka K, Fukuda S: Cryosurgery on postganglionic fibers (posterior nasal branches) of the pterygopalatine ganglion for vasomotor rhinitis. *ActaOtolaryngol.* 96:139-148, 1983.
- 3) Ikeda K, Oshima T, Suzuki M, et al: Functional inferior turbinotomy for the treatment of resistant chronic rhinitis. *ActaOtolaryngol.* 126: 739-745, 2006.

- 4) Toru Kikawada. Endoscopic posterior nasal neurectomy: An alternative to vidian neurectomy. *Operative Techniques in Otolaryngology*. Vol 18, No 4, December 2007. 297-301.
- 5) SilviuAlbu et al. Endoscopic microdebrider-assisted inferior turbinoplasty with and without posterior nasal neurectomy. *AurisNasus Larynx*. 41 (2014) 273-277.
- 6) Taisuke Kobayashi. Resection of peripheral branches of the posterior nasal nerve compared to conventional posterior neurectomy in severe allergic rhinitis. *AurisNasus Larynx*. 39 (2012) 593-596.
- 7) Malcomson, K. G.: The vasomotor activities of the nasal mucous membrane. *J. Laryngol. and Otol.*, 73: 73-98, 1959.
- 8) Tomoyuki Ogawa. Submucousturbinectomy combined with posterior nasal neurectomy in the management of severe allergic rhinitis: Clinical outcomes and local cytokine changes. *AurisNasus Larynx*. 34 (2007) 319-326.
- 9) Kanaya, Kikawada. Endoscopic posterior nasal neurectomy: an alternative to Vidian neurectomy. *Clinical and Experimental Allergy Reviews*. 2009, 9, 24-27.

Dark chocolate

Because of their high fat and sugar content, the prevailing wisdom about chocolates is that they should be enjoyed only now and then; a more frequent consumption might bring on tooth decay and obesity. But chocoholics are not deterred by such considerations and they may turn out to be right. Daily consumption of moderate amounts of chocolate (around 25 grams), particularly of dark variety, appears to lower the insulin resistance and improve the levels of liver enzymes, thus lowering the risk for the development of type 2 diabetes and heart disease. The dark chocolate is rich in cocoa which is full of flavonoids with powerful antioxidant property. The effect apparently seems to be directly related to the amount of chocolate consumed. Besides, this effect is consistent enough to raise the prospect of using dark chocolate in near future as a prescriptive drug! Rejoice, chocoholics! (*British Journal of Nutrition*, doi: <http://dx.doi.org/10.1017/S0007114516000702>, published online 17 March 2016)

- Dr. K. Ramesh Rao