

Case Report

Hypogonadotropic Hypogonadism – Canary in a Coal Mine?

Kanchana Devi B*, Bharath R**, Gayathri Devi S S*, Pandiyan N***

*Consultant, **Consultant Endocrinologist, ARKA Centre for Hormonal Health, Chennai ***Prof. & HOD, Dept. of Reproductive Medicine, Chettinad Super Speciality Hospital, Chennai, India.



Dr. Kanchana Devi did her graduation and post graduation from Madras Medical College. Further finished Fellowship in Reproductive Medicine from CMC Vellore. She is currently working as a Consultant in the Department of Reproductive Medicine, Chettinad Super Speciality Hospital. She is highly active in presenting papers at National and International conferences and is also a resource person in various academic forums.

Corresponding author - Dr. Kanchana Devi (kanchanadevi2001@yahoo.co.in)

Key Words: Hemochromatosis, Hypogonadotropic hypogonadism

Chettinad Health City Medical Journal 2014; 3(4): 167 - 169

Introduction

Hypogonadotropic hypogonadism contributes to 15% of anovulatory infertility¹. Hypogonadotropic hypogonadism is encountered rarely in routine clinical practice and leads to surprises at times as in this case.

Case report

24 yrs female, reported to the Reproductive Medicine Out Patient Department with history of involuntary childlessness for 3 yrs. She attained spontaneous menarche at 13 yrs. Initial cycles were regular, later it became irregular with a cycle length of 60-90 days. Since three years she had withdrawal cycles with combined pills. She was a known case of diabetes mellitus diagnosed one year ago for which she was on oral hypoglycaemic agent and insulin. Glycaemic control was suboptimal despite compliance to medication. No significant parental/sibling history.

Laparoscopy of pelvis done elsewhere showed a small uterus with bilateral patent tubes. Ovaries were reported as small and atrophic. No further comments about the pelvic findings were available. Her investigations done 12 months before presentation to us were supportive of hypogonadotropic hypogonadism with low levels of serum FSH (0.2mIU/mL) and LH(0.3mIU/mL). Thyroid status was reported as normal. Cytogenetic analysis revealed a normal karyotype. Her male partner was normozoospermic.

On examination, her height was 153 cm and weight was 52 kg with a BMI of 22. General examination and other systems examination were normal. Secondary sexual characters were as follows- Axillary hair –Tanner's stage 1, Pubic hair –Tanner's 3, Breast –Tanner's 4. On pelvic examination a small uterus and cervix was palpable through a narrow vagina. USG pelvis confirmed a hypoplastic uterus with an endometrial thickness of 2.8 mm. Right ovary measured 13x12mm, no antral follicles, left ovary measured 16x18mm with 1-2 antral follicles.

With the diagnosis of anovulation secondary to hypogonadotropic hypogonadism, ovulation induction with gonadotrophins was considered. Investigations were repeated at our centre before ovarian stimulation on 17.11.2013 (Table 1).

Hb	11 gms%	(12-16gm/dL)
PCV	33.27%	(36-47%)
Blood Sugar		
Fasting	202 mg%,	(70-105mg/dL)
Postprandial	306mg%	(<140mg/dL)
HbA _{1c}	9.1%	(4.7-8.5%)
TSH	1.21 mIU/ml	(0.5 – 5mIU/mL)
Prolactin	11.4 µg/ml	(<20 µg/L)
Serum FSH	0.23mIU/ml	(5-20mIU/mL)
Serum LH	0.27mIU/ml	(5-22 mIU/mL)
Estradiol level	50pmol/L	(50-100pmol/L)

Viral Screening for HIV, HbsAg, Hep C-Negative, Rubella – Protected. Gonadotropins were started in a low dose step up fashion for ovulation induction after confirmation of diagnosis. As the risk of hyperstimulation is high in these women, human menopausal gonadotropin 37.5 IU was started and stepped up to 75 units. The dosage was further increased to 150IU and was abandoned after 39 days due to non responding ovaries.

On further work up, she had an MRI pituitary fossa which showed a hypoplastic anterior pituitary (fig 1&2). There was diffuse hypointensity on GRE images in choroid plexus of bilateral lateral ventricles, foramen of Luschka and Magendie, suggestive of haemosiderin deposits, differential diagnosis being-Haemosiderosis which could be secondary to Thalassaemia, Wilsons disease, Amiodarone or colloidal gold administration.

Her liver enzymes were elevated. Serum iron, ferritin, transferrin saturation were very high (table 2). Her ceruloplasmin levels were normal and there was no history of administration of Amiodarone or colloidal gold. All these features were suggestive of primary haemochromatosis with secondary hypogonadism and diabetes. Mutation analysis was inconclusive (Table-2).

Literature review

There are several case reports and case series about haemochromatosis²⁻³ but majority of the reports are on male hypogonadism associated with haemochromatosis. Haemochromatosis occurs due to a defective control of iron absorption leading to excessive iron stores in the body. Surplus iron that is deposited in the organs lead to increased intracellular

iron leading to oxidative damage and impaired membrane dependent functions of organelles like mitochondria, microsomes and lysosomes⁴. Manifestations can range from simple fatigue to diabetes mellitus, hepatic failure, sexual dysfunction, infertility etc, depending on the site and extent of the iron deposit.

Table 2 - Blood parameters

Investigation	Values
Serum Ferritin	2236ng/ml (15-200ng/mL)
Serum Transferrin	211 mg/dL (212 -360mg/dL)
Serum iron	262µg/dL (60-160µg/dL)
TIBC	262µg/dL (250-460µg/dL)
C- peptide	0.368 ng/mL (0.9 -43ng/mL)
Ceruloplasmin	655 mg/L (250-430mg/L)
Hb	11.4gm% (12-16gm/dL)
HbA1c	10.7%(4.7 -8.5%)
Serum Magnesium	2.52 (1.5-2.4mg/dL)
Electrolytes	Na 135mEq/L (136-145mEq/L) K 4.3mEq/L (3.5-5mEq/L) HCO 28mEq/L (23-28mEq/L)
Serum FSH	0.106 mIU/ml (5-20mIU/mL)
LH	0.208 mIU/ml (5-22 mIU/mL)
TSH	1.699 mIU/ml (0.5 – 5mIU/mL)
FTC	1.12 µg/dL 4-11µg/dL
Prolactin	8.7 µg/L (<20 µg/L)
Cortisol	10.55 µg/dL (8-20µg/dL)
Mutation analysis for HFE,HFE2,HAMP in 6p22.1,1q21.1,9q13.1	No mutations in direct sequencing

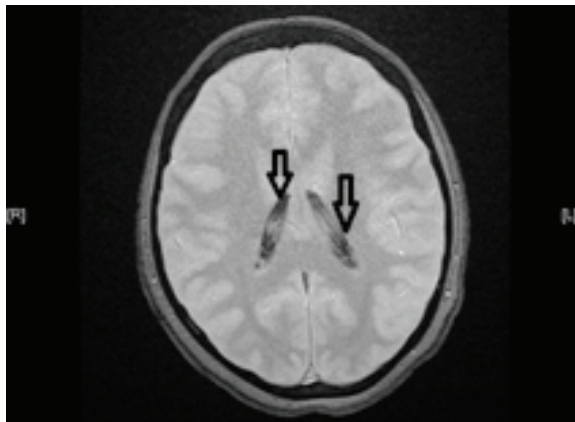


Fig 1 - MRI picture, GRE image showing lateral ventricles with hypointensity

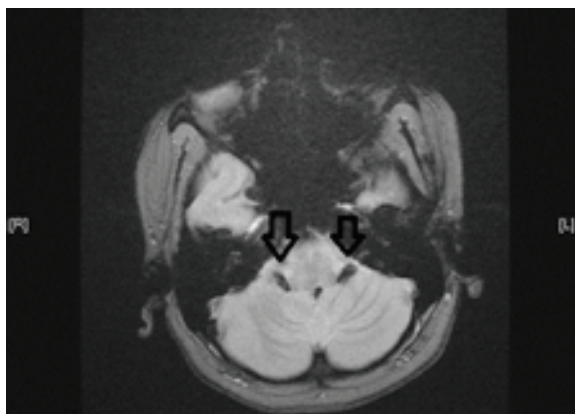

Fig 2 - MRI Brain – GRE image showing hypointensity of Foramen of Luschka

Haemochromatosis can be of two types Primary or Hereditary Haemochromatosis(HH) which is due to a HFE gene defect or a non-HFE mutation like haemojuvelin, Hepsidin, Transferrin receptor mutations. In secondary haemochromatosis the iron excess is due to conditions like congenital haemolytic anaemias, environmental and lifestyle factors.

Classical HH is more common in Europeans with a prevalence of 1/200. Reports from Asian continent has identified non HFE^{3,5} gene defects.

Hereditary haemochromatosis usually presents in the third or fourth decade of life and usually is an incidental finding. It is more prevalent in male than in female(25:1)⁶ Patients may present with a myriad of symptoms depending on the organ involved.

Unless there is high degree of suspicion the diagnosis of haemochromatosis is elusive. Apart from the clinical manifestations and family history, increased serum ferritin level and transferrin saturation of >45% will help in clinching the diagnosis. In early stages the ferritin levels may not be high and in Asian subjects, the co existing anaemia and iron deficiency or co existing thalassaemia may complicate the picture.

Among the imaging modalities, MRI is the most sensitive to pick up the haemosiderin deposits of the pituitary, pancreas. Dual energy CT is helpful in quantifying the deposits. A biopsy of the liver will show the evidence of iron deposits in the cells. Currently the availability of MRI has replaced the need for liver biopsies to diagnose haemochromatosis. Current recommendation for liver biopsy is to assess the hepatic fibrosis to prognosticate the patient outcome⁴. Early diagnosis and treatment has the potential to prevent damage to liver, heart and other organs. With treatment, total reversal of hypogonadism and return of normal sexual function and fertility in men have been reported⁷.

Reports on hypogonadism in women are few and majority are about late onset hypogonadism i.e. at fourth or fifth decade of life⁶.

Treatment is usually prolonged. Periodic venesections are performed to reduce the iron overload. This may take upto 24 months to bring down the serum Ferritin level to the recommended 50µg/l⁸. Later the level is maintained by venesections done at more infrequent intervals i.e. 2-3 months once. Chelating agents like Desferrioxamine is used in secondary haemochromatosis.

Modification in diet is advised to reduce the intake of iron. Patients are also encouraged to take chelating agents along with food (eg dairy products) to reduce the iron absorption.

Mutation analysis is important to map the gene defect in families and to offer counseling⁹. Even if the patient is cured and fertility concern is answered, it is important to monitor on a long term basis as the risk of hepatocellular carcinoma is high.

Treatment in fertility clinic

Patients often present with sexual infantilism or infertility in both genders. Treatment to reduce iron overload and carefully tailored treatment with Testosterone supplements, hCG and gonadotropins will help improving libido, correcting erectile dysfunction and semen parameters in men.

In women, gonadotropin administration will help to induce ovulation and to achieve fertility. The addition of IUI or IVF to ovulation induction depends on the other co-existing causes of infertility.

Genetic counselling prior to treatment of infertility is a must. Prenatal mutation analysis is available but not commonly done⁸.

Discussion

Our patient had certain unusual features which need to be explored further.

Presentation at the second decade as in this patient is not common in primary haemochromatosis. Reports on juvenile type HH discuss about the mutations in haemojuvelin gene (HFE2) and hepcidin gene (HAMP gene –HFE2B) presenting in second or third decade of life. Here both these mutations are not seen. Though the mutation analysis for TFR2 (Transferrin Receptor) and FPN1 (Ferroportin 1) have not been ruled out, the possibilities of these are very limited.

Her response to gonadotropins could be due to initial low dosage. But complete absence of response despite increasing the dosage to 150IU is intriguing. Whether the resistance to stimulation is directly related to the haemosiderin deposit in the ovary is unclear.

The take home message is that the primary diagnosis can be easily missed in any patient and it is advisable to involve multi disciplines. This goes a long way in not only treating their infertility but also improving their life expectancy.

Identification of regions with high incidence of haemochromatosis, gene mapping and maintaining a registry will enhance awareness and early diagnosis. Creating a support group will improve their coping up skills.

Acknowledgement

We thank the Dept. of Radiology Chettinad Hospital & Research Institute and the Dept. of Haematology, Christian Medical College, Vellore for the valuable inputs and their contribution for images and mutation analysis.

References

- 1) Yen & Jaffe's Reproductive Endocrinology. Eds. Strauss JF, Barbierl. 6th edition, 2009 Elseviers Inc.
- 2) Kanwar PS Metal Storage Disorders- Wilson Disease and Hemochromatosis , , Med Clin N Am 2014;98:87-102
- 3) Panigrahi I, Ahmad. F et al, Evidence for non-HFE linked haemochromatosis in Asian Indians, Indian Journal of Medical Sciences, 2006;160(12):491–495.
- 4) Bruce R Bacon, Paul C Adams, Kris V Kowdley Lawrie W Powell and Anthony S Tavill Diagnosis and Management of Hemochromatosis: 2011 Practice Guideline by the American Association- for the Study of Liver Diseases, Hepatology, 54
- 5) Chin yu hok et al, Iron overload in the Asian community. Blood Journal 2009; 114:20-25
- 6) Romain Moirand, Paul C Adams. Clinical features of Genetic Haemochromatosis in Women compared with men. Ann Intern Med 1997; 127(2): 105-110.
- 7) Michael J Tweed, Jonathan M Roland, Haemochromatosis as an endocrine cause of subfertility: BMJ 1998;316(7135):915-916.
- 8) W Yen. Andrew, Revisiting Hereditary Hemochromatosis: Current Concepts and Progress. The American Journal of Medicine 2006; 119: 391-399
- 9) Stuhmann M, Graf N, Dörk T, Schmidtke J. Mutation screening for prenatal and presymptomatic diagnosis: cystic fibrosis and haemochromatosis. Eur J Pediatr. 2000 Dec; 159(3) : 186-91