

Case Report

An Interesting Case of Hereditary Haemorrhagic Telangiectasia with Chronic Parenchymal Liver Disease

Noorul Ameen S*, Samhitha Reddy A**, Sakuntala SR***, Rajasekaran D****

*Assistant Professor, **Postgraduate student, ***Professor, ****Prof. & HOD, Department of General Medicine, Chettinad Hospital & Research Institute, Chennai, India.



Dr.Noorul Ameen.S MD, FCD, is working as an Assistant Professor in Department of General Medicine, Chettinad Hospital and Research Institute since June 2011. He graduated from Madras Medical College in 2007, and did his Post Graduation in Kilpauk Medical College. His areas of interest in Medicine are Diabetology and Cardiology.

Corresponding author - Samhitha Reddy A (samhithareddy.dr@gmail.com)

Abstract

Hereditary haemorrhagic telangiectasia(HHT) also known as Osler-Weber-Rendu disease is a rare autosomal dominant disorder that causes vascular dysplasias of all the blood vessels and results in a tendency for bleeding. It has a triad of mucocutaneous telangiectasiae, recurrent epistaxis, positive family history. We report a case of HHT in a 60 yr old male who was admitted with recurrent epistaxis, multiple mucosal and skin lesions, strong family history associated with chronic parenchymal liver disease which is a rare association.

Key Words: Hereditary Hemorrhagic Telangiectasia, Epistaxis.

Chettinad Health City Medical Journal 2014; 3(4): 189 - 191

Introduction

Hereditary haemorrhagic telangiectasia(HHT) is a rare genetic disorder having a prevalence of approximately 1 in 8000 people. It is manifested by vascular lesions like mucocutaneous telangiectasis and arteriovenous malformations (AVMs) which are a potential source of serious morbidity and mortality¹. The diagnosis of HHT is made clinically on the basis of the Curaçao criteria², which includes : a) Epistaxis b) Telangiectasias c) Visceral lesions d) Family history (a first-degree relative with HHT). Three out of the four criteria is diagnostic of HHT. Our present case met all the four criteria for HHT; recurrent epistaxis, telangiectasiae of the fingertips and tongue, GI bleeding from multiple vascular ectasias, and positive first-degree family history. Further our patient also had features of chronic parenchymal liver disease which is very rarely associated with HHT.

Case Report

A 60 year old male presented with history of breathlessness of NYHA Class II, abdominal distention, bilateral leg swelling for 6 months. He had recurrent epistaxis since the age of 13, last episode being 1 week back. There was no history of haemoptysis, fever, abdominal pain, vomiting, or jaundice.

Patient had recurrent blood transfusions in the past for anaemia, was also treated for TB lymphadenitis in 1991 and for jaundice in 2003. Argon plasma coagulation was done for gastrointestinal vascular ectasias. Patient had undergone diagnostic laproscopy for an evaluation for ascites and treated for TB peritonitis in 2014. He is a known diabetic, non smoker and non alcoholic. There is family history of epistaxis and his grand mother died because of UGI bleed (Fig 1).

At the time of admission patient was severely anaemic with bilateral pitting pedal edema with a pulse rate 100/min and respiratory rate 24/min. Purpuric, punctuate tiny macules, blanching with pressure were noticed on fingertips (Fig 2), soft palate and tongue (Fig 3). Systemic examination revealed free fluid in the abdomen and hepatic bruit over liver. Cardiac auscultation revealed an ejection systolic murmur in pulmonary area.

His investigations revealed Hb-2.4 g/dL, ESR-150 mm/hr, Stool occult blood- Positive. HbsAg, anti-HCV, ANA were negative. UGI scopy and colonoscopy revealed gastric, duodenal, caecal and colonic angioectasias (Fig 4). USG abdomen was suggestive of chronic parenchymal liver disease with ascites. CT abdomen confirmed the features of chronic parenchymal liver disease in addition to the tortuous hepatic artery. Contrast echocardiogram with saline showed mild pulmonary hypertension without any pulmonary A-V malformation. Fundus- Roth spots in Lt eye probably due to severe anaemia. CT Brain was negative for A-V malformation.

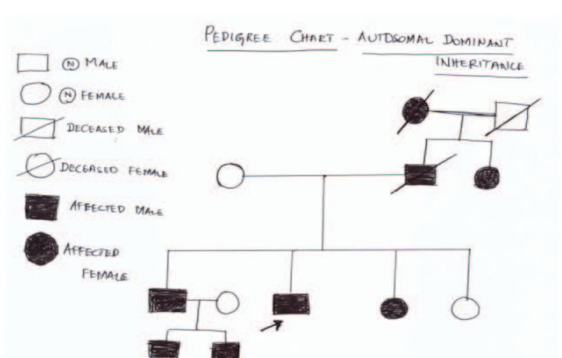


Fig. 1 - Pedigree Chart

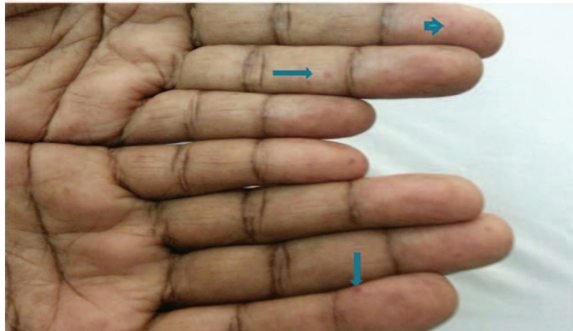


Fig. 2 - Telangiectasia on finger tips

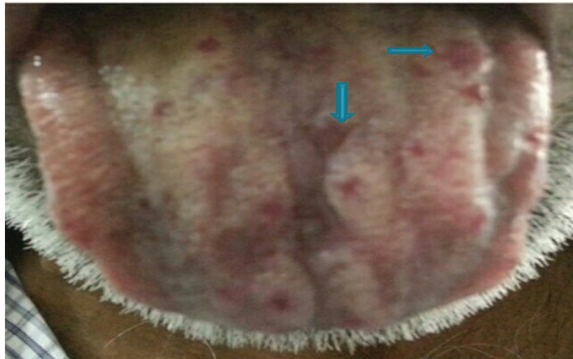

Fig. 3 - Tongue Telangiectasias

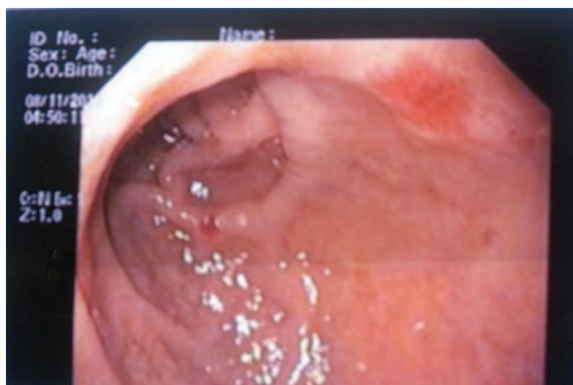

Fig. 4 - Gastric Vascular Ectasia

Discussion

HHT was first recognized in the 19th century as a familial disorder with abnormal vascular structures causing bleeding from the nose and gastrointestinal tract. HHT is characterized by telangiectatic lesions in nose, lips, finger tips and visceral organs like liver, spleen, GI tract, genitourinary tract, lungs, brain, spinal cord. The most common clinical presentation is recurrent and severe epistaxis leading to severe anaemia which frequently requires transfusion³.

HHT is classified into four types genetically⁴. Out of the two major types of HHT (HHT₁ and HHT₂) disease severity is more in HHT₁ than HHT₂, with an earlier age of onset for epistaxis, mucocutaneous telangiectasias, and a higher incidence of pulmonary AVMs. HHT₁ can be induced by mutations in the gene, ENG (endoglin), encoding endoglin on chromosome 9q. HHT₂ can be induced by mutations in the gene, ALK-1 (activin receptor-like kinase 1), encoding activin receptor-like kinase 1 on chromosome 12q13^{5,6}. They cause alteration in the elastic and muscle layers of vessel

walls, leads to spontaneous rupture and injuries⁷. Further, other minor types are associated with mutations in *madh4* gene (HHT with juvenile polyposis) and unidentified gene in chromosome 5 (HHT₃). The clinical manifestations vary among families and sometimes may vary within the same family. Common clinical manifestations are shown in Table 1.

Table 1 - Common Clinical Manifestations

Epistaxis (90%) – most common
Skin and mucosal lesions (75%)
Pulmonary involvement (30%) – AV Malformations
Hepatic involvement (30%) - Jaundice, variceal bleed or atypical cirrhosis
GI bleeding (15%)
CNS involvement – Cerebral AVMs, Spinal AVMs

Management options are very limited. There is no definitive treatment for HHT as of now. Epistaxis could be treated with packing, aminocaproic acid, estrogen, argon beam ablation. Cutaneous lesions may be treated with electrocauterization with diathermy, hypertonic saline sclerotherapy, or laser therapy. Recently, limelight has been on Bivacizumab, a humanised monoclonal anti-VEGF antibody. It is given in the dose of 5 mg/kg as IV infusion for 4 weeks for reducing GI blood loss and epistaxis. Our patient was treated for chronic parenchymal liver disease with diuretics and symptomatically for epistaxis. To summarise, ours is a case of Hereditary Haemorrhagic Telangiectasia with a rare association of chronic parenchymal liver disease.

Acknowledgement

We thank the Department of Medical Gastroenterology of Chettinad Hospital & Research Institute for helping us in diagnosing vascular ectasia by doing the endoscopy procedures.

References

- 1) Giordano P, Lenato GM, Suppressa P, Lastella P, Dicuonzo F, Chiumarulo L, et al. Hereditary hemorrhagic telangiectasia: arteriovenous malformations in children. *J Pediatr.* Jul 2013;163(1):179-86.e1-3.
- 2) Shovlin CL, Guttmacher AE, Buscarini E, et al. Diagnostic criteria for hereditary hemorrhagic telangiectasia (Rendu-Osler-Weber syndrome). *Am J Med Genet.* Mar 6 2000;91(1):66-7.
- 3) Franchini M, Frattini F, Crestani S, Bonfanti C. Novel treatments for epistaxis in hereditary hemorrhagic telangiectasia: a systematic review of the clinical experience with thalidomide. *J Thromb Thrombolysis.* Oct 2013;36(3):355-7.
- 4) Bayrak-Toydemir P, McDonald J, Akarsu N, Toydemir RM, Calderon F, Tunculi T, Tang W, Miller F, Mao R. A fourth locus for hereditary hemorrhagic telangiectasia maps to chromosome

Am J Med Genet A 2006;140:2155-2162. J Med Genet 2011;48:73-87.

- 5) Franchini M, Frattini F, Crestani S, Bonfanti C. Novel treatments for epistaxis in hereditary hemorrhagic telangiectasia: a systematic review of the clinical experience with thalidomide. J Thromb Thrombolysis. Oct 2013;36(3):355-7.
- 6) Abdalla SA, Letarte M. Hereditary haemorrhagic telangiectasia: current views on genetics and mechanisms of disease. J Med Genet. 2006;43:97-110. [PMC free article] [PubMed]
- 7) Juares AJ, Dell'Aringa AR, Nardi JC, Kobari K, Gradim Moron Rodrigues VL, Perches Filho RM. Rendu-Osler-Weber Syndrome: case report and literature review. Braz J Otorhinolaryngol. 2008;74:452-457. [PubMed]

For obese people, size does not matter

To keep a check on how much we eat is not all that easy. One stratagem commonly employed by those who are keen to eat less, is to eat from a smaller plate, bowing to conventional knowledge that smaller plates carry smaller portions. But these acts of self-deception do not work for all. Particularly, it does not work for those who desperately need to eat less – obese teenagers. In a new study carried out at UConn Health Alcohol Research Center on teenage girls, the researchers discovered that the overweight subjects paid very little attention to the size of the plate or the container. Undistracted by the trick, they consumed until they felt full. They also failed to pay much attention to the detailed dietary charts. The only way to curb their appetite is to subject them to simple, clear, interesting and repetitive diet education. The study was presented at the Annual Meeting of American Psychosomatic Society.

[University of Connecticut. "Smaller plates, smaller portions? Not always." Science Daily. Science Daily, 27 March 2015]

- Dr. K. Ramesh Rao