

Review Article

Cerebral Aneurysms

Roopesh Kumar

Professor & Head, Dept of Neurosurgery, JIPMER, Pondicherry



Having Completed MCh (Neurosurgery) training from NIMHANS, Bangalore in the year 2004, he started the department of Neurosurgery at JIPMER in the year 2006. He has special interest in cerebrovascular surgery, skull base surgery, Craniovertebral junction anomalies and minimally invasive cranial & spinal surgeries. He has published more than 25 papers in various peer reviewed national & international journals and presented various papers in CMEs and Conferences at national level. He has been the invited faculty for World federation of Neurosurgeons meeting held at Seoul, South Korea, in September 8-12, 2013. He has delivered various Health awareness programmes for Doordarshan, Podhigai and All India Radio since 2010. He has received several various prestigious awards for excellence in medical field. He is the Vice president of JIPMER scientific society and secretary of Pondicherry association of Neuroscientists.

Corresponding author - Dr. Roopesh Kumar (roops1975@gmail.com)

Abstract

Intra cranial aneurysms are abnormal outpouchings of vessel wall occurring at major vessel bifurcations. Majority of them occur in the anterior circulation and most commonly present with sub arachnoid hemorrhage. Various radiological investigations are presently available to accurately localize the aneurysm and identify the morphology. The 2 major treatment modalities are surgical clipping and endovascular coiling and each have their own merits and demerits. While the treatment mainly focuses on exclusion of the aneurysm from the circulation to prevent recurrent bleed, the other major goal of management is treatment of cerebral vasospasm associated with subarachnoid hemorrhage. Little is known about the pathophysiology of vasospasm and thus the treatment remains mainly symptomatic by raising the blood pressure and adequately hydrating the patient during the peak period of vasospasm. While the surgical clipping of aneurysms is standardized, the endovascular coiling techniques continue to evolve and may be the mainstay of management in the future. Microsurgery would be restricted to a small cohort of patients requiring vascular bypasses. The long term outcome of coiling is a matter of concern as recanalization of previously coiled aneurysms is an issue which has to be worked upon.

Key Words: Aneurysm, Clipping, Endovascular coiling, Vasospasm, Sub arachnoid hemorrhage, Vasospasm

Chettinad Health City Medical Journal 2014; 3(2): 65 - 73

Introduction

Cerebral aneurysm is defined as an abnormal focal dilatation of a cerebral artery with attenuation of the vessel wall¹. Intracranial aneurysms are generally classified according to their shape as saccular (berry shaped) and fusiform (dissecting, infectious, atherosclerotic and traumatic) aneurysms. They can be solitary or multiple (Fig 1). Saccular aneurysms constitute 90% of all cerebral aneurysms and are located at the major branch points of large arteries². Fusiform aneurysms are elongated outpouchings of arteries and account for 7% of all cerebral aneurysms. Mycotic aneurysms are found peripherally and comprise 0.5% of all cerebral aneurysms.

Aneurysms arising from anterior circulation constitute 85%. Multiple aneurysms are noted in 20-30% of patients³ (Fig 1b). They present most commonly with subarachnoid haemorrhage (SAH). They may also cause intraparenchymal, intraventricular, or subdural haemorrhage. Giant aneurysms (Figure 2) (size greater than 25 mm in diameter) represent 3-5% of all intracranial aneurysms and present with mass effect and distal thromboembolism (Fig 1a).

Pathogenesis

The basic pathology of aneurysmal formation is defect in the internal elastic lamina with associated elastic

defects in the adjacent layers of the tunica media and adventitia. As such, intra cranial vessels lack external elastic lamina which may account for the higher prevalence of aneurysms in this region. Focal turbulence and discontinuity of the normal architecture at vessel bifurcations contribute to occurrence of aneurysms at these locations. Recent evidence suggests that arterial wall proteolysis by matrix metalloproteinases, apoptosis, and chronic inflammation play a key role in the pathogenesis and disease progression of intracranial aneurysms^{4,5}.

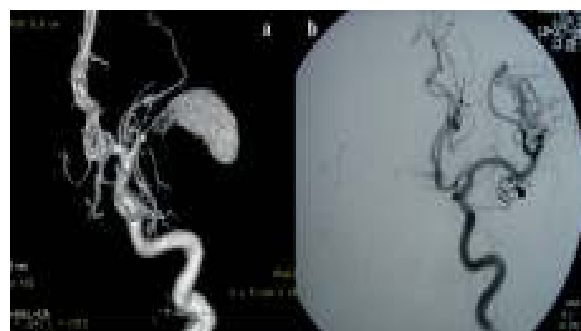


Figure 1 :

a – Large single middle cerebral artery aneurysm seen on a 3D reconstructed CT angiogram image.

b – Multiple aneurysms. The thin arrow points to a distal anterior cerebral artery aneurysm and the short thick arrow points to a left middle cerebral artery aneurysm.

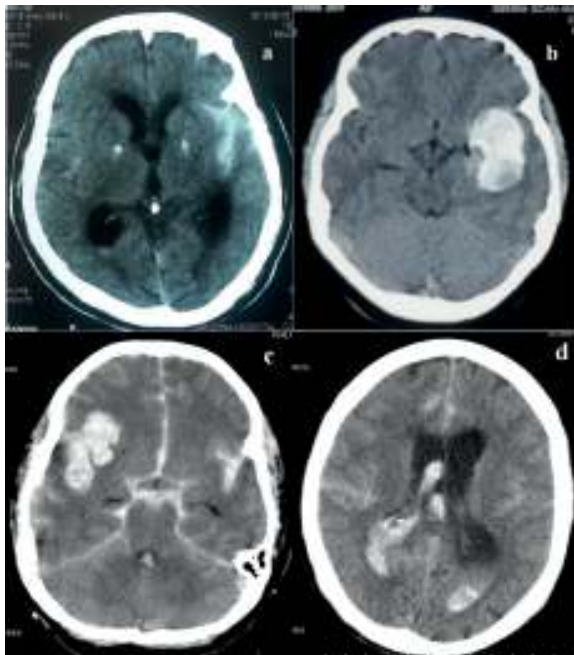


Figure 2 : Subarachnoid hemorrhage.

a – Plain CT showing localized SAH in the left Sylvian fissure.

b – A large intraparenchymal hematoma in the left temporal lobe, caused by a left middle cerebral artery aneurysm.

c – A combination of subarachnoid hemorrhage and intraparenchymal hematoma arising from a single right middle cerebral artery aneurysm.

d – Intraventricular hemorrhage arising from rupture of an anterior communicating artery aneurysm.

Most aneurysms are developmental and the major contributory factors are atherosclerosis and hypertension. Rarely, aneurysms may be congenital due to collagen deficiency such as seen in fibro muscular dysplasia, Marfan syndrome, Ehlers-Danlos syndrome etc. Adult polycystic kidney disease is one of the co-existing lesion in intra cranial aneurysms⁶. Cigarette smoking increases the ratio of elastase to alpha 1 - antitrypsin levels in cerebral arterial walls, which may contribute to formation or rupture of aneurysm in smokers^{7,8}.

Mycotic aneurysms are of infective etiology and are most often encountered in infective endocarditis⁹. The seedling of infective vegetation containing pathogens like *Staphylococcus aureus* results in degradation of vessel wall resulting in aneurysmal formation. They are mostly seen in peripheral branches of middle cerebral artery and may be multiple. They have high propensity to bleed due to thin and friable wall than the saccular aneurysms⁹.

Other rare causes of aneurysms are trauma, tumor emboli, high flow state like arteriovenous malformation, Moya Moya disease etc.

Risk factors for rupture of aneurysm

The treatment of an unruptured intracranial aneurysm is based on the likelihood of its rupture during the patient's lifetime. The risk factors associated with rupture of aneurysm are aneurysmal size, location, shape, significant family history, multiple aneurysms

and prior history of aneurysmal subarachnoid hemorrhage⁸.

Aneurysms are historically classified as small (<10 mm), large (10–24 mm), and giant (≥ 25 mm). Studies have concluded that there is a correlation between aneurysm size and risk of rupture. ISUIA (International Study of Unruptured Intracranial Aneurysms) I 1998 and ISUIA II 2003 have studied the relationship between aneurysm size and risk of rupture and showed that rupture rates are high with larger sizes^{10,11}. Clinical and autopsy studies have shown that, aneurysms between 7 and 10 mm size are more likely to bleed, but many are smaller than 7 mm in size; the exact size beyond which an aneurysm becomes "dangerous" is unclear.

Rinkel and colleagues showed that the relative risk for aneurysm rupture was higher for posterior circulation aneurysms like basilar tip, vertebrobasilar and posterior cerebral compared to anterior circulation aneurysms with a relative risk of 4.1%^{12,13}. ISUIA studies showed that posterior circulation aneurysms, especially basilar apex aneurysms and posterior communicating (Pcom) artery aneurysms from anterior circulation have a higher relative rupture rate compared to those at other sites (Fig 3).

Studies suggest that aneurysms with irregular morphology, particularly those that are multilobed with daughter domes, are more likely to bleed compared to smooth-walled lesions. Several studies suggest that ruptured aneurysms have higher aspect ratios (aneurysm height/neck width) compared to unruptured aneurysms^{13,14}.

The aneurysm's risk of rupture is higher and may occur at an earlier age in individuals who have multiple family members with intracranial aneurysms, compared to aneurysms that arise in individuals with no known family history¹⁵.

Several studies showed that multiple unruptured intracranial aneurysms are associated with a higher risk for hemorrhage than solitary lesion¹⁴. Yasui et al demonstrated an annual rupture rate of 6.8% and Rinkel et al found that the relative risk for rupture is 1.7 in patients with multiple lesions compared to single unruptured intracranial aneurysm^{16,17}.

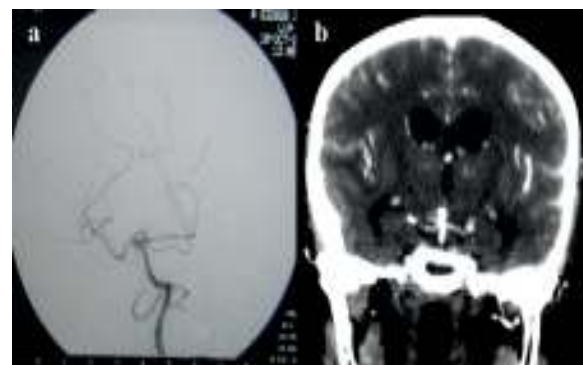


Figure 3 : Posterior circulation aneurysms

a – Digital subtraction angiogram of a right superior cerebellar artery aneurysm.

b – CT angiogram (coronal) of a basilar apex aneurysm.

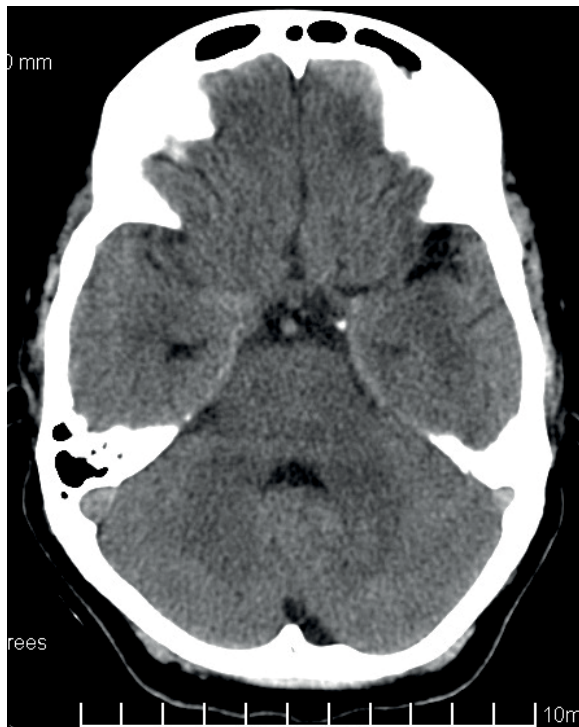

Figure 4:
Very small quantity of SAH seen in the left sylvian fissure. LP was positive for SAH in this case, with crenated RBCs and supernatant xanthochromia.

ISUIA showed that patient with a history of subarachnoid hemorrhage from a different aneurysm had a tenfold increase in the risk of rupture from a small unruptured aneurysm, compared to a patient with no history of subarachnoid hemorrhage^{10,11}.

The reported mortality of patients in whom subarachnoid hemorrhage is diagnosed is about 40% within the first 30 days. Among those who survive, less than 25% have a good functional outcome^{18,19}.

The volume of blood escaping during rupture of an aneurysm varies from a negligible amount constituting a "warning leak" to massive amounts (≥ 150 mL) associated with immediate death (Fig 2c). When the intra cranial pressure equals the mean arterial pressure, temporary circulatory arrest occurs which stops the aneurysmal bleeding. This transient global ischemia causes loss of consciousness as seen in most patients with acute sub arachnoid haemorrhage. Because many patients do not lose consciousness, normal clotting mechanisms may probably also contribute to arrest of the haemorrhage²⁰.

Clinical presentation

The characteristic presentation of SAH is a sudden, severe headache, as seen in more than 80% of patients, which often is described by the patient as the "worst headache of my life"²¹. Headache is usually associated with vomiting and followed by loss of consciousness. Patients might deteriorate rapidly resulting in death or continue to have altered sensorium. The rapidity of the clinical deterioration and resulting death depends on the severity of the bleed. Patients with minor bleed the sensorium can even improve to normal following the

brief episode of loss of consciousness. Other symptoms include seizures, dysphasia, limb weakness, vision loss and double vision²².

The associated symptoms may give a clue to the location of aneurysms. Bilateral lower limb weakness may be due to aneurysm in the anterior cerebral artery territory. Middle cerebral artery aneurysm may be associated with hemiparesis or dysphasia. Ptosis is seen with aneurysms in the posterior communicating artery or rarely superior cerebellar artery due to direct compression of cisternal part of third nerve by the aneurysm fundus.

Large unruptured aneurysms can cause symptoms due to local mass effect and embolic episodes due to dislodgement of thrombi from the aneurysm. Giant middle cerebral artery aneurysm may cause limb weakness due to embolic infarct in the motor area or internal capsule. Large vertebro-basilar thrombosed aneurysms can present with lower cranial nerve palsy and brain stem symptoms due to direct compression or due to brain stem infarcts.

Fusiform aneurysms mostly arise due to atherosclerotic aetiology⁸. They are most commonly seen in posterior circulation. The entire vessel wall becomes dilated and do not have the neck or fundus as seen in saccular aneurysms. They contain laminated thrombus which may result in thrombo embolic stroke. They rarely cause subarachnoid haemorrhage and typically present with mass effect on brainstem and cranial nerves.

On examination meningismus along with altered sensorium and focal deficits are commonly noted among patients with aneurysmal rupture. Funduscopy might reveal subhyaloid haemorrhage and vitreous haemorrhage (Terson syndrome)²³. Depending on the GCS and the presence of focal deficits, patients with aneurysmal SAH are graded by WFNS (World federation of Neurological surgeons) grading system and modified Hunt and Hess clinical grading system. The higher the grade, poorer is the prognosis.

Investigations

A plain cranial CT is the investigation of choice in patients with suspected SAH. It has a high sensitivity and can be positive in 92% of the cases, if done on the day of ictus. The sensitivity gradually decreases in the subsequent days due to clearance of blood in the subarachnoid spaces by the CSF. After 1 week, the sensitivity drops to less than 5%²⁴. In addition to subarachnoid blood, CT scan can detect intra parenchymal haemorrhage, intra ventricular haemorrhage, cerebral edema, hydrocephalus and infarcts in the parent vessel territory (Fig 2).Fischer's grading helps to estimate the amount of blood in the subarachnoid space and is thus of prognostic value in predicting vasospasm, one of the most adverse side effects of sub arachnoid haemorrhage²⁵. Recent studies suggest that the rate of clearance of blood is more important than the amount of blood in subarachnoid space for predicting vasospasm.

Lumbar puncture is indicated if there is strong suspicion of sub arachnoid haemorrhage and Cranial CT is

normal (Fig 4). This can happen when the bleed is negligible or when the patient presents to physician at a later date. Supernatant xanthochromia and presence of crenated RBCs are very reliable signs of sub arachnoid haemorrhage²⁶. Uniform blood staining of CSF helps to differentiate sub arachnoid haemorrhage from traumatic tap in which CSF clears in serial drainage.

CT Angiography

CT angiography (CTA) has sensitivities of 77% to 97% and specificities of 87% to 100% for detection of intracranial aneurysms larger than 3mm in maximal diameter²⁷ (Fig 3a, b). 3D TOF MRA has sensitivity of 87% and specificity of 95%. CTA is less time consuming and provides additional information on the 3-D anatomy of the vessel with respect to the adjacent bony structures. MRA is superior than CTA in follow up imaging of aneurysms treated with coiling due to lesser artefacts. MRI is also essential in imaging large thrombosed aneurysms²⁸ (Fig 5).

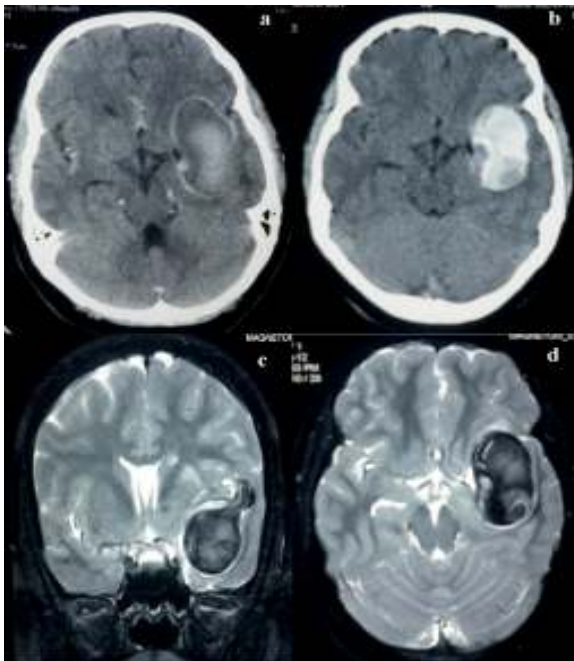


Figure 5 : Posterior circulation aneurysms

a – Plain CT scan outlining the giant left middle cerebral artery aneurysm.

b – CT showing the hematoma within the aneurysm after it bled.

MRI of the same aneurysm, T2 coronal (c) and axial (d) images, showing the hypointense hematoma within the large fundus.

Digital subtraction angiography (DSA)

DSA is still considered to be the gold standard for detecting intracranial aneurysms and defining its anatomy despite its invasiveness. The risk for permanent and transient neurological complication associated with DSA during the diagnosis of unruptured and ruptured aneurysms is 0.3% and 1.8%, respectively. DSA is sensitive for even aneurysms smaller than 3mm²⁹ (Fig 6c & d). It can provide information about the cross circulation across different

arterial territories. The greatest advantage of DSA at present day scenario is the possibility of simultaneous endovascular intervention whenever feasible.

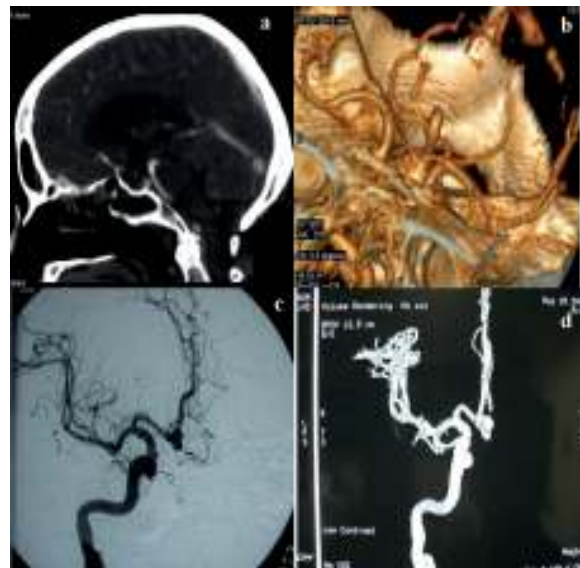

Figure 6: - Imaging modalities for aneurysms.

a – CT angio sagittal image showing a basilar apex aneurysm.

b – 3D reconstruction of the same image, showing the aneurysm and its relationship to the surrounding vessels.

c - Digital subtraction angiogram showing an anterior communicating artery aneurysm.

d – 3D reconstruction of the same aneurysm.

Surgical management

The main goal of surgical management of aneurysm is to exclude it from circulation thereby preventing rebleed and at the same time preserve the continuity of the parent vessel and its branches. This can be accomplished by passing a clip across the aneurysm neck (Fig 7). For aneurysms in inaccessible locations or for those lesions, whose morphology prevent passing of clip, alternative strategies have to be done. These include proximal or Hunterian ligation, wrapping the aneurysm, and trapping (combined proximal and distal vessel occlusion). For giant aneurysms, in addition to exclusion from circulation, the other goal is to reduce the mass effect by opening the fundus, remove the thrombus and decompress it from surrounding neurovascular structures.

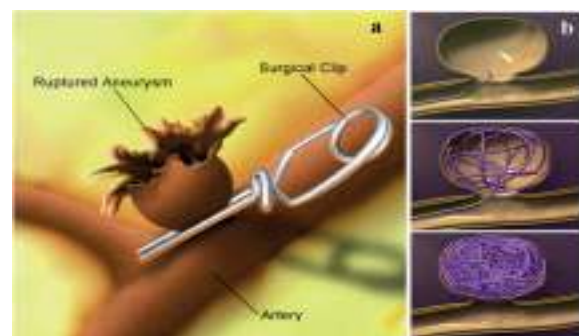


Figure 7 : Techniques of eliminating an aneurysm from the circulation.

a – Schematic of aneurysm clipping.

b – Schematic of aneurysm coiling.

Principles of Aneurysm surgery

Anaesthesia: The main goal of anaesthesia for aneurysm surgery is cerebral protection during temporary clipping. The other goal is maintain normotension, euvolemia and adequate analgesia throughout the surgery to prevent intra operative aneurysm rupture. It is of paramount importance that the brain is lax during surgery by giving osmotic diuretics and hyperventilation.

Positioning: The goal is to position the head such that the operative site is above the level of the cardia and avoiding flexion of the neck thereby reducing venous congestion. In basal approaches, a good extension can enable the cerebrum to fall with gravity thereby eliminating manual retraction. This is especially important while operating on acute SAH (Fig 8).

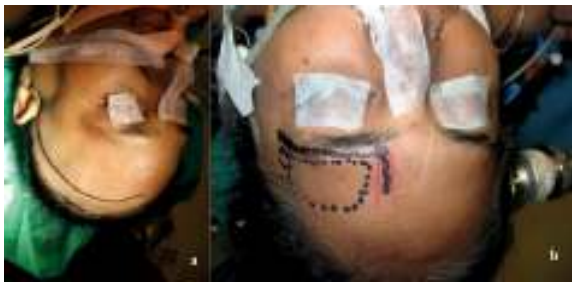

Figure 8 : Positioning a patient for aneurysm surgery.

a – Position for a conventional pterional craniotomy.

b – Position and incision for a suprabrow mini-craniotomy approach.

Craniotomy: The selection of craniotomy depends on the location of aneurysm. Most anterior circulation aneurysms are operated upon by using pterional craniotomy as described by Yasargil. With this approach, majority of the aneurysms along internal carotid artery, Posterior communicating artery, anterior communicating artery, middle cerebral artery can be clipped. The essential steps include removal of small portion of bone centring pterion, removal of the lateral sphenoid ridge adequately to expose 5*5 cm dura overlying sylvian fissure. After dural opening, the frontal lobe is retracted in the long axis of optic nerve initially to release CSF from carotico optic cistern. This will ensure laxity of the brain for further dissection.

Then a self-retaining Retractor is placed on the basal part of frontal lobe to stretch the sylvian fissure. Opening of the sylvian fissure is done from lateral to medial direction by meticulous technique under high magnification. Once the fissure opening is completed, the axis of retraction is changed and the retractor is placed along long axis of the internal carotid artery. The mainstay of aneurysm surgery is extensive arachnoid opening to clear all the subarachnoid clots and inspecting the arteries related to the aneurysm location.

Further dissection depends on the location of aneurysm. The general principles are proper exposure of the parent vessel to aid placement of temporary clip if necessary, dissecting the neck of the aneurysm (the fundus region is not usually dissected to avoid premature rupture), identification of all the perforating

branches in close vicinity of the neck and the major branching vessels beyond the aneurysm. Sharp dissection using micro scissors is preferred over blunt dissection throughout exposure of the aneurysm. Once the neck of the aneurysm is exposed, the appropriate clip is selected which can slide along with ease and does not compromise the lumen of parent vessel. Various shapes of clips like straight, curved, right angled, left or right curve etc, are available and have to be chosen accordingly. Fenestrated clips are sometimes used in specific situations when a major artery is in the axis of neck precluding safe placement. In such instances, the fenestration can be used around the artery and clip blades across the neck. Various clipping techniques are described which are to be tailored according to the morphology of the aneurysm (Fig 9).

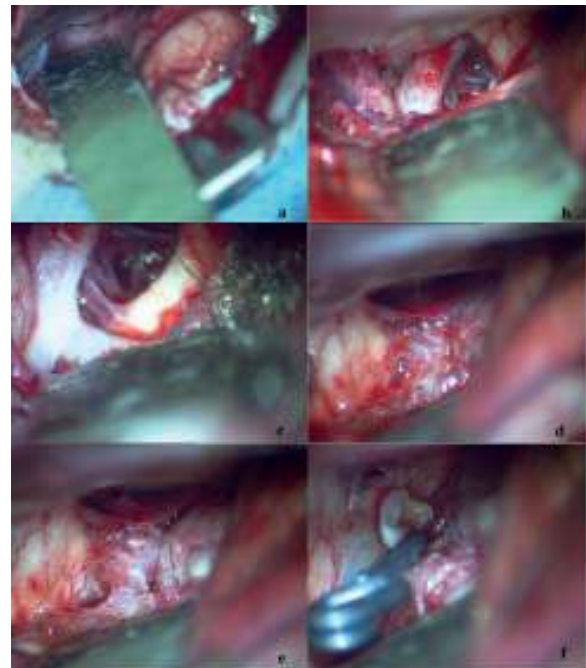

Figure 9 : - Steps in clipping an anterior communicating artery aneurysm.

a - Intra operative picture showing retraction of basifrontal lobe exposing optic nerve and ICA

b - Showing exposure of optic nerve and ICA

c - Showing exposure of ICA bifurcation

d - Showing exposure of Acom aneurysm covered by arachnoid

e - Showing exposure of neck of Acom aneurysm after opening the arachnoid

f - Showing the clip across the neck.

It is important to confirm the complete exclusion of aneurysm and the patency of parent vessel before closing the dura. Various techniques are described from microsurgical inspection of the pulsation, puncturing the fundus etc. These are crude methods and the better way to do is using micro Doppler probe which can signal the presence of flow. Latest in technology is Indo cyanine green angiography (ICG) which can intra operatively visualize the vessels in the field and can be used with high precision³⁰. The difficulty is to make sure that perforators are not caught in the clip on the back wall of the aneurysm neck. Both ICG angiography and Micro Doppler are not less useful in this situation.

Using a 30 degree endoscope can inspect the back wall of neck to identify patency of the perforators which are not visualized by microscope angle.

Following clipping, the subarachnoid clots are cleared by using copious saline irrigation and the lamina terminalis is opened to establish communication of third ventricle to basal cisterns. This may obviate the need of CSF diversion at later date in some patients and also accelerate the clearance of subarachnoid clots thereby preventing vasospasm.

Specific circumstances - Skull base approaches: While most anterior circulation aneurysms can be dealt with pterional craniotomy, some aneurysms close to the base of skull requires removal of the portions of basal bones to enhance exposure as in paraclinoid ICA aneurysms and carotico- ophthalmic aneurysms. These aneurysms can be safely clipped following removal of anterior clinoid process.

Posterior circulation aneurysms: Basilar bifurcation aneurysms are better approached by pterional approach if they lie in the normal plane (Opposite dorsum sella). A high bifurcation usually requires orbito zygomatic approach and a low bifurcation is better dealt via sub-temporal trans tentorial approach.

Vertebral-PICA aneurysms can be operated through far lateral, retro sigmoid or midline occipital approaches depending on the location of the aneurysms.

Complications

Vasospasm: The major complication of subarachnoid haemorrhage is vasospasm (also called delayed ischemic neurological deficit)³¹. The onset of vasospasm starts 3 days following SAH and peaks during 7-9 days. Thereafter, the risk gradually reduces until about 3 weeks. Angiographic vasospasm is seen on vascular imaging and is high in incidence (60-70%). Clinical vasospasm is seen in roughly half of these patients. The risk is directly proportional to the amount of blood clots in the sub arachnoid cisterns. The exact pathogenesis is unclear and various hypothesis relate to imbalance between nitric oxide synthase (potential vasodilator) and Endothelin I (vasoconstrictor). While angiography can exactly identify the vasospasm, it can also be reasonably diagnosed with good precision by trans cranial Doppler, a non-invasive tool used more frequently nowadays.

The mainstay of preventing vasospasm is hydrating the patient adequately and maintaining a high blood pressure with the help of inotropic agents³². Reducing the viscosity of blood by administering low molecular weight dextran may also help perfuse the brain through narrow perforator vessels by improving the rheology. These three measures together constitutes the HHH regime (Hypertension, Hypervolemia & Haemodilution) and the most important component is hypertension. Generally, a target of 160-180 mmHg of systolic pressure, 110-120 mmHg of diastolic pressure, central venous pressure of 8-10 mmHg and a haematocrit of 10 is achieved to prevent vasospasm.

The main pharmacological agent used for vasospasm is Nimodipine, a calcium channel blocker which has selective action on intra cranial vessels with no peripheral action³³. Though the exact mechanism by which it acts is unknown, the speculation is that it acts as a cerebral protectant by preventing neuronal intra cellular calcium influx rather than by vasodilatation. It is administered orally as 60 mg 4th hourly. It can also be administered intra venously in severe cases of vasospasm.

Endovascular treatment of Vasospasm: If conservative measures fail to improve the vasospasm within 12 hours, one should resort to emergency endovascular procedures. Balloon angioplasty is ideally performed if proximal major vessels(ACA, MCA and PCA) are involved³⁴. The complications are minimal if carefully performed but occasionally can cause rupture of the vessel. If distal vessels are involved in spasm, then balloon angioplasty is not advocated and chemical angioplasty can be performed by injecting papaverine (1 in 10 dilution) or Nimodipine. The effects are however short lasting (maximum of 6 hours) and may have to leave the intra-arterial catheter in situ for repeat injections with the potential risks of thromboembolism if anticoagulation is not effectively used.

Hydrocephalus: Ventricular dilatation warranting CSF diversion can be seen upto 15-20% of patients following sub arachnoid haemorrhage. It is seen after 4-6 weeks and is due to blockade of arachnoid villi by the degradation products of haemoglobin. Patients with intra ventricular blood has a higher chance of developing hydrocephalus. Opening of lamina terminalis and adequate washing of sub arachnoid blood clots intra operatively may help in reducing the incidence of hydrocephalus³⁵ (Fig 10).

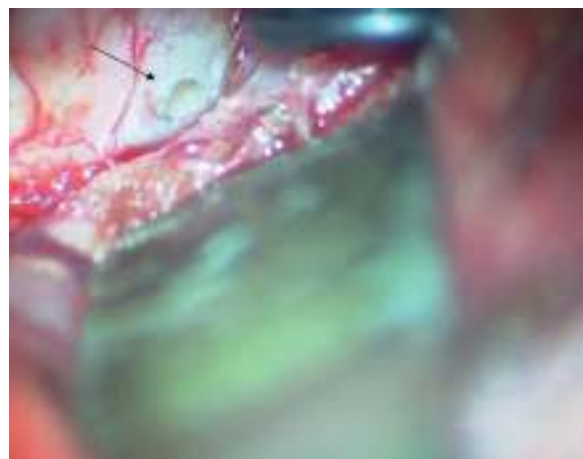


Figure 10 : - Opening of lamina terminalis after clipping to prevent hydrocephalus.

Seizures: Seizures can occur in 20% of patients following sub arachnoid haemorrhage³⁶. Patients with middle cerebral artery aneurysms have a higher tendency to develop seizures. Early prevention of seizures by pharmacological measures may reduce the risk for developing late seizures by preventing kindling.

Fluid and electrolyte disturbances: The most frequent electrolyte abnormality seen following sub arachnoid haemorrhage is hyponatremia (up to 40%)³⁷. This is

also called cerebral salt wasting, which occurs due to release of cerebral atrial natriuretic peptide resulting in loss of both sodium and water in urine. The treatment is by replacing both water and sodium (ideally hypertonic saline). In refractory cases, a mineralocorticoid like fludrocortisone is administered orally in 0.1-0.15 mg twice a day³⁸.

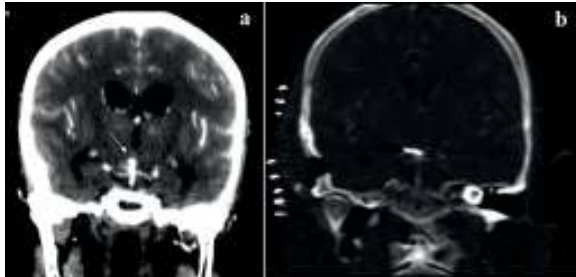


Figure 11 : - Complete aneurysm obliteration by clipping

a – Coronal image CT angiogram showing a basilar apex aneurysm

b – Postop coronal image showing a clip across the aneurysm neck and complete obliteration of the aneurysm.

Controversies

Timing of Surgery: In the past, there was a great controversy regarding the timing of surgical intervention. One school of thought was to perform delayed surgery after 2-3 weeks of subarachnoid haemorrhage so that the cerebral edema subsides and the subarachnoid cisterns are clear of blood thereby facilitating surgical clipping. But, the major drawback was the high rebleed rate and inadequate measures to combat vasospasm. According to the international co-operative study on Timing of aneurysm surgery, the peak risk of rebleed was within 24 hours (4%). The subsequent risk is 1.5% per day with a cumulative risk of 19% in the first 2 weeks. Rebleed was associated with mortality of more than 75%. Thus, by delaying the surgery for 2 weeks, the patients are deprived of their protection against rebleed and hence the evidence is in favour of early surgery³⁹. Some studies even advocate ultra-early surgery (within 6 hours of SAH) to improve the final outcome.

Microsurgery Versus Endovascular surgery: The other major controversy is whether to subject the patient for surgical clipping or endovascular coiling (Fig 7). The International Sub arachnoid aneurysm trial (ISAT) which randomised patients to clipping versus coiling in situations where both management modalities deemed appropriate, demonstrated a marginal benefit of cognitive outcome in patients who had undergone coiling at 1 year follow up⁴⁰. However, the long term outcome in subsequent studies revealed that the rate of recanalization and recurrence of aneurysm formation is between 15-50% when the patients were followed up several years after treatment⁴¹. On the contrary, more than 90% of patients who had undergone microsurgical clipping showed complete occlusion of aneurysms in the long term follow up (Fig 11). Thus, though the mortality is slightly higher in the surgical group, the combined mortality and severe morbidity is equivalent in both clipping and coiling group⁴². To summarise, endovascular coiling is an attractive option in acutely ruptured aneurysms with poor grade, especially in the

older age group. Posterior circulation aneurysms are preferred for coiling than clipping.

Conclusion

The management of intra cranial aneurysm can be complex and challenging. Various factors have to be considered before contemplating the ideal treatment. Good knowledge of the anatomy and pathophysiology guides the accurate line of management. While the technology of managing these complex lesions are still evolving, a major insight into the pathophysiology and management of cerebral vasospasm still needs to be identified. As the technology of endovascular treatment is rapidly progressing, majority of the aneurysms would be managed with this modality in the future and microsurgery would be restricted to cases with previously failed coiling and vascular bypasses for giant and complex aneurysms.

References

- 1) Meyers PM, Schumacher HC, Higashida RT, Derdeyn CP, Nesbit GM, Sacks D, Wechsler LR, Bederson JB, Lavine SD, Rasmussen P. Reporting standards for endovascular repair of saccular intracranial cerebral aneurysms. *Stroke*. 2009 May;40(5):e366-79.
- 2) Parlea L, Fahrig R, Holdsworth DW, Lownie SP. An analysis of the geometry of saccular intracranial aneurysms. *AJNR Am J Neuroradiol*. 1999 Jun-Jul;20(6):1079-89.
- 3) Wiebers DO, Whisnant JP, Sundt TM Jr, et al.: The significance of unruptured intracranial saccular aneurysms. *J Neurosurg*. 1987 Jan;66(1):23-29.
- 4) Drăghia F, Drăghia AC, Onicescu D. Electron microscopic study of the arterial wall in the cerebral aneurysms. *Rom J Morphol Embryol*. 2008; 49(1):101-3.
- 5) Santiago-Sim T, Kim DH. Pathobiology of intracranial aneurysms Youmans Neurological Surgery (Winn HR, ed), 6th ed. Vol. 4 Philadelphia, PA: Elsevier, Saunders; 2011:3747-3755.
- 6) Schievink WI. Genetics of intracranial aneurysms. *Neurosurgery*. 1997 Apr;40(4):651-62.
- 7) Baker CJ, Fiore A, Connolly ES Jr, Baker KZ, Solomon RA. Serum elastase and alpha-1-antitrypsin levels in patients with ruptured and unruptured cerebral aneurysms. *Neurosurgery*. 1995;37:56-62.
- 8) Juvela S, Poussa K, Porras M. Factors affecting formation and growth of intracranial aneurysms: a long-term follow-up study. *Stroke*. 2001 Feb;32(2):485-91.
- 9) Masuda J, Yutani C, Waki R, Ogata J, Kuriyama Y,

- Yamaguchi T. Histopathological analysis of the mechanisms of intracranial hemorrhage complicating infective endocarditis. *Stroke*. 1992;23:843-850.
- 10) International Study of Unruptured Intracranial Aneurysms Investigators: Unruptured intracranial aneurysms—risk of rupture and risks of surgical intervention. *N Engl J Med*. 1998;339:1725-1733.
 - 11) Wiebers DO, Whisnant JP, Huston J 3rd, Meissner I, Brown RD Jr, Piepgras DG, Forbes GS, Thielen K, Nichols D, O'Fallon WM, Peacock J, Jaeger L, Kassell NF, Kongable-Beckman GL, Torner JC; International Study of Unruptured Intracranial Aneurysms Investigators. Unruptured intracranial aneurysms: natural history, clinical outcome, and risks of surgical and endovascular treatment. *Lancet*. 2003 Jul 12;362(9378):103-10.
 - 12) Bromberg JE, Rinkel GJ, Algra A, et al. Subarachnoid haemorrhage in first and second degree relatives of patients with subarachnoid haemorrhage. *BMJ*. 1995;311:288-289.
 - 13) Juvela S, Porras M, Poussa K. Natural history of unruptured intracranial aneurysms: probability of and risk factors for aneurysm rupture. *J Neurosurg*. 2000;93:379-387.
 - 14) Lall RR, Eddleman CS, Bendok BR, et al. Unruptured intracranial aneurysms and the assessment of rupture risk based on anatomical and morphological factors: sifting through the sands of data. *Neurosurg Focus*. 2009;26(E2):1-7.
 - 15) Broderick JP, Brown RD, Sauerbeck L, et al. Greater rupture risk for familial as compared to sporadic unruptured intracranial aneurysms. *Stroke*. 2009;40:1952-1957.
 - 16) Yasui N, Suzuki A, Nishimura H, et al.: Long-term follow-up study of unruptured intracranial aneurysms. *Neurosurgery*. 1997;40:1155-1159.
 - 17) Rinkel GJ, Djibuti M, Algra A, et al.: Prevalence and risk of rupture of intracranial aneurysms: a systematic review. *Stroke*. 1998;29:251-256.
 - 18) Risselada R, Lingsma HF, Bauer-Mehren A, Friedrich CM, Molyneux AJ, Kerr RS, Yarnold J, Sneade M, Steyerberg EW, Sturkenboom MC. Prediction of 60 day case-fatality after aneurysmal subarachnoid haemorrhage: results from the International Subarachnoid Aneurysm Trial (ISAT). *Eur J Epidemiol*. 2010 Apr;25(4):261-6.
 - 19) Hop JW, Rinkel GJ, Algra A, et al. Case-fatality rates and functional outcome after subarachnoid hemorrhage: a systematic review. *Stroke*. 1997;28:660-664.
 - 20) Lee VH, Oh JK, Mulvagh SL, Wijidicks EF. Mechanisms in neurogenic stress cardiomyopathy after aneurysmal subarachnoid hemorrhage. *Neurocrit Care*. 2006;5(3):243-9.
 - 21) Bassi P, Bandera R, Loiero M, Tognoni G, Mangoni A. Warning signs in subarachnoid hemorrhage: a cooperative study. *Acta Neurol Scand*. 1991; 84: 277-281.
 - 22) Fontanarosa PB. Recognition of subarachnoid hemorrhage. *Ann Emerg Med*. 1989; 18: 1199-1205.
 - 23) McCarron MO, Alberts MJ, McCarron P. A systematic review of Terson's syndrome: frequency and prognosis after subarachnoid haemorrhage. *J Neurol Neurosurg Psychiatry*. 2004;75:491-493.
 - 24) Brown SC, Brew S, Madigan J. Investigating suspected subarachnoid haemorrhage in adults. *BMJ*. 2011;342:d2644.
 - 25) Frontera JA, Claassen J, Schmidt JM, Wartenberg KE, Temes R, Connolly ES Jr, MacDonald RL, Mayer SA. Prediction of symptomatic vasospasm after subarachnoid hemorrhage: the modified fisher scale. *Neurosurgery*. 2006 Jul;59(1):21-7; discussion 21-7.
 - 26) Jonathan A. Edlow, Louis R. Caplan. Avoiding pitfalls in the diagnosis of subarachnoid haemorrhage. *N Engl J Med*, 2000; 342:29-36
 - 27) Westerlaan HE, van Dijk JM, Jansen-van der Weide MC, de Groot JC, Groen RJ, Mooij JJ, Oudkerk M. Intracranial aneurysms in patients with subarachnoid hemorrhage: CT angiography as a primary examination tool for diagnosis: systematic review and meta-analysis. *Radiology*. 2011; 258: 134-145.
 - 28) White PM, Teasdale EM, Wardlaw JM, Easton V. Intracranial aneurysms: CT angiography and MR angiography for detection prospective blinded comparison in a large patient cohort. *Radiology*. 2001; 219(3): p. 739-49.
 - 29) Ishihara H, Kato S, Akimura T, Suehiro E, Oku T, Suzuki M. Angiogram-negative subarachnoid hemorrhage in the era of three dimensional rotational angiography. *J ClinNeurosci*.2007; 14: 252-255.
 - 30) Hardesty DA, Thind H, Zabramski JM, Spetzler RF, Nakaji P. Safety, efficacy, and cost of intraoperative indocyanine green angiography compared to intraoperative catheter angiography in cerebral aneurysm surgery. *J ClinNeurosci*. 2014 Aug;21(8):1377-82.
 - 31) Vergouwen MD, Vermeulen M, van Gijn J, Rinkel GJ, Wijidicks EF, Muizelaar JP, Mendelow AD, Juvela S, Yonas H, Terbrugge KG, Macdonald RL, Diringner MN, Broderick JP, Dreier JP, Roos YB. Definition of delayed cerebral ischemia after aneurysmal subarachnoid hemorrhage as an outcome event in clinical trials and observational studies: proposal of a multidisciplinary research group. *Stroke*.2010; 41: 2391-2395.

- 32) Lennihan L, Mayer SA, Fink ME, Beckford A, Paik MC, Zhang H, Wu YC, Klebanoff LM, Raps EC, Solomon RA. Effect of hypervolemic therapy on cerebral blood flow after subarachnoid hemorrhage: a randomized controlled trial. *Stroke*.2000; 31: 383–391.
- 33) DorhoutMees SM, Rinkel GJ, Feigin VL, Algra A, van den Bergh WM, Vermeulen M, van Gijn J. Calcium antagonists for aneurysmal subarachnoid haemorrhage. *Cochrane Database Syst Rev*. 2007 Jul 18;(3):CD000277.
- 34) Zwienenberg-Lee M, Hartman J, Rudisill N, Madden LK, Smith K, Eskridge J, Newell D, Verweij B, Bullock MR, Baker A, Coplin W, Mericle R, Dai J, Rocke D, Muizelaar JP; Balloon Prophylaxis for Aneurysmal Vasospasm (BPAV) Study Group. Effect of prophylactic transluminal balloon angioplasty on cerebral vasospasm and outcome in patients with Fisher grade III subarachnoid hemorrhage: results of a phase II multicenter, randomized, clinical trial. *Stroke*.2008; 39: 1759–1765.
- 35) Komotar RJ, Hahn DK, Kim GH, Khandji J, Mocco J, Mayer SA, Connolly ES Jr..The impact of microsurgical fenestration of the lamina terminalis on shunt-dependent hydrocephalus and vasospasm after aneurysmal subarachnoid hemorrhage.*Neurosurgery*.2008; 62: 123–132.
- 36) Choi KS, Chun HJ, Yi HJ, Ko Y, Kim YS, Kim JM. Seizures and epilepsy following aneurysmal subarachnoid hemorrhage: incidence and risk factors. *J Korean Neurosurg Soc*. 2009; 46: 93–98.
- 37) Disney L, Weir B, Grace M, Roberts P. Trends in blood pressure, osmolality and electrolytes after subarachnoid hemorrhage from aneurysms. *Can J Neurol Sci*. 1989; 16: 299–304.
- 38) Mori T, Katayama Y, Kawamata T, Hirayama T. Improved efficiency of hypervolemic therapy with inhibition of natriuresis by fludrocortisone in patients with aneurysmal subarachnoid hemorrhage. *J Neurosurg*.1999; 91: 947–952.
- 39) Whitfield PC, Kirkpatrick PJ. Timing of surgery for aneurysmal subarachnoid haemorrhage. *Cochrane Database Syst Rev*. 2001;(2):CD001697.
- 40) Molyneux AJ, Kerr RS, Yu LM, Clarke M, Sneade M, Yarnold JA, Sandercock P; International Subarachnoid Aneurysm Trial (ISAT) Collaborative Group. International Subarachnoid Aneurysm Trial (ISAT) of neurosurgical clipping versus endovascular coiling in 2143 patients with ruptured intracranial aneurysms: a randomised comparison of effects on survival, dependency, seizures, rebleeding, subgroups, and aneurysm occlusion. *Lancet*.2005; 366: 809–817.
- 41) Uda K, Murayama Y, Gobin YP, Duckwiler GR, Viñuela F. Endovascular treatment of basilar artery trunk aneurysms with Guglielmi detachable coils: clinical experience with 41 aneurysms in 39 patients. *J Neurosurg*.2001; 95: 624–632.
- 42) Bakker NA, Metzemaekers JD, Groen RJ, Mooij JJ, Van Dijk JM. International Subarachnoid Aneurysm Trial 2009: endovascular coiling of ruptured intracranial aneurysms has no significant advantage over neurosurgical clipping. *Neurosurgery*.2010; 66: 961–962.

No Link between Sleep Apnoea and Cancer

Several studies have claimed that obstructive sleep apnoea (OSA) influences cancer progression. As 2 – 10% of the population worldwide is afflicted with sleep apnoea, this claimed association assumes clinical and epidemiological significance. However, a new study carried out on 10,149 apnoea patients over a period of 16 years (1994-2010), failed to find any association between OSA & Cancer (Tetyana Kendzerska, et al., Obstructive sleep apnoea and the prevalence and incidence of cancer, *CMAJ*, DOI:10.1503/cmaj.140238, published online 5 August 2014). The patients were followed up for an average period of 7.8 years. During that period, 6.5% developed cancer (lung, prostate, breast or colorectal). But when all the known risk factors were accounted for, there was no causal link between sleep apnoea & cancer. The authors are confident that their results are correct as the earlier studies were done on very small number of subjects. It is also likely that profound hypoxia (a known promoter of growth) in earlier studies might have skewed the results.

- Dr. K. Ramesh Rao