

Class Room

Surgeries for End Stage Heart Failure

Praveen Kerala Varma*, Neetu Krishna**

*Consultant Cardiac Surgeon, **Research Co-ordinator, Division of Cardiac Surgery, Amrita Institute of Medical Sciences, Kerala, India



Dr. Neetu Krishna is currently working as Research Coordinator in Cardio-Vascular and Thoracic Surgery (CVTS) at Amrita Institute of Medical Sciences, Kochi from March 2012 till date. She graduated in Zoology from Mahatma Gandhi University in 2005 and further did her Masters in Hospital Administration (MHA) from Amrita Viswavidhyapeetham in 2007. She has successfully completed the Internal Auditor Training Programmes for Integrated Management System (ISO 9001 and 14001) and NABH-AHPI. She is actively involved in various departmental research activities, assist in the preparation of research papers and manuscripts for publication and in the writing of project reports, articles and other documents.

Corresponding author - Praveen Kerala Varma (varmapk@gmail.com)

Chettinad Health City Medical Journal 2015; 4(1): 36 - 39

Introduction

Heart failure (HF) is a leading cause of death nowadays. Heart failure is a pathophysiologic condition that leads to inadequate cardiac performance and is responsible for the heart's inability to increase output. The myocardium responds to the reduced output by compensatory mechanisms of the Frank-Starling relationship¹, ventricular wall thickness, ventricular geometry, and neurohormonal activation. The neurohormonal system stimulates a cascade of hemodynamic alterations that adversely affect outcome².

Neurohormonal system activation leads to further cardio myocyte dysfunction and endothelial dysfunction that leads to abnormal hemodynamics. Neurohormonal activation leads to hypertrophy and remodeling of the ventricular chamber resulting in the progression of the HF³.

When myocardium is damaged, its ability to maintain adequate cardiac output decreases. A subnormal heart leads to sluggish circulation (congestion) and results in fatigue, shortness of breath, pedal oedema and irregular heart-beats. Common causes of heart failure are ischemic heart disease, myocardial infarction, hypertension, valve disease, muscular dysfunction and arrhythmias.

After myocardial injury the heart remodels and dilates, an increase in wall tension occur secondary to increased radius of curvature, as per Laplace's law leading to increased myocardial oxygen consumption, decreased sub-endocardial blood flow, impaired energetic, and increased arrhythmias. Poor prognosis directly correlates with the degree of remodeling. Pharmacologic therapy leads to some improvements to ventricular function and long term results, however the improvement in frequently inadequate⁴.

Heart failure is associated with long hospital stay, multiple readmissions, and reduced quality of life. In patients with HF secondary to systolic dysfunction, the primary objectives of therapy are to improve survival, alter disease progression, and reduce symptoms. Pharmacologic treatment include the blocking of neurohormonal responses. Pharmacologic therapy results in improved left ventricular (LV) function¹.

Surgical management of patients with end-stage, refractory systolic HF are limited. Heart transplantation remains the optimal treatment for end-stage HF. Contraindications due to recipient co morbidities, and transplant complications preclude routine use. Heart transplantation is not an option for majority of patients.

Other surgical approaches to end-stage HF includes:

- Coronary Revascularization with ischemic cardio myopathy.
- DOR Procedure (Fig 1).
- Mitral valve repair (Mitral Regurgitation correction) with dilated cardiomyopathy.
- Left ventricular assist devices (LVADs) (Fig 2).

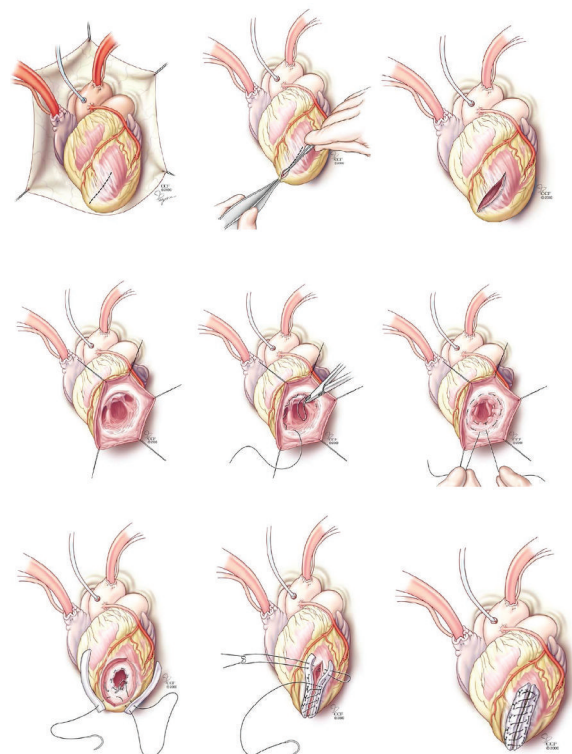


Fig 1 - DOR Procedure

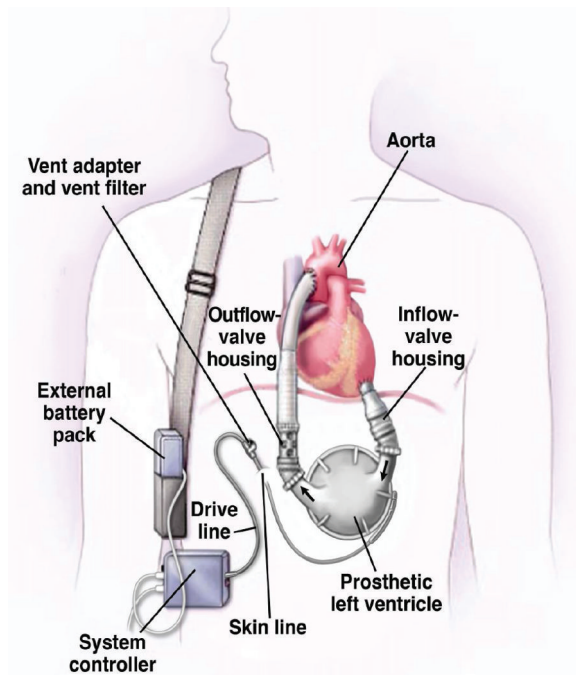


Fig 2 - Schematic view of a cardiovascular system with an LVAD

A. Coronary Revascularization with ischemic cardiomyopathy

Ischemic cardiomyopathy is significantly impaired left ventricular function (left ventricular ejection fraction \leq 35 to 40 percent) that results from ischemic heart disease.

Ischemic cardiomyopathy is a condition initiated by primary events in the coronary circulation that lead to myocyte loss, scarring, and ventricular failure. Cell loss occurs as a result of narrowing or occlusion of coronary arteries by atherosclerosis, spasm of major arterial branches of the coronary vasculature, or alterations of the microcirculation, which, alone or in combination, produce varying degrees of ischemia and myocardial injury⁵.

The clinical spectrum ranges from myocardial infarction to chronic ischemic cardiomyopathy. The latter is a form of dilated ischemic myopathy characterized by multiple focal sites of myocardial damage in the ventricular wall⁶.

Patients with HF who are at risk for ischemic heart disease should be screened for myocardial ischemia. Revascularization, through either percutaneous or a bypass surgery, often improves symptoms, improves cardiac performance, and reduces the risk of sudden death⁷.

Viability testing has a role in identifying patients who are unlikely to benefit from revascularization⁸. Revascularization was proposed as the treatment of choice in the advanced HF patients with ischemic cardiomyopathy, a LVEF below 35%, viable myocardium and vessels suitable for grafting⁹.

CABG has good long-term outcome in angina free patients with ischemic cardiomyopathy and heart

failure who have residual viability. However, associated diastolic impairment, reflected by elevated left ventricular end-diastolic pressure (LVEDP), predicts reduced long-term survival despite myocardial viability⁸.

Patients with ischemic cardiomyopathy and viable myocardium, revascularization surgery is not a new but an established treatment concept. Concerning the assessment of viability, it is of utmost importance to predict regional functional recovery. Patients with ischemic cardiomyopathy will remain the recipients of on- and off-pump CABG as surgical techniques and medical therapies continue to improve¹⁰.

The future of revascularization in these patients will focus on improving results and making CABG for elective revascularization less invasive and safer.

B. DOR Procedure

LV aneurysmectomy has been offered as an option for the patients with symptomatic aneurysms that have been defined as including those associated with HF, angina pectoris, systemic embolization, and/or malignant ventricular tachyarrhythmias. The Dor procedure, also called endoventricular circular patch plasty (EVCPP) or endoventricular patch reconstruction, is an approach to surgical reconstruction in the setting of post-infarction aneurysm formation¹¹.

A dilated left ventricle is generally due to remodeling secondary to myocardial infarction. Occlusion, results in either akinetic (non-beating) or dyskinetic tissue. This tissue is virtually useless. However, the end-diastolic volume, remains constant, so the tissue that still functions has to do more work to eject the blood.

If the cardiologist determines that the Dor procedure is necessary, then the patient must have symptoms to show that they would be a good candidate, either, angina, heart failure, arrhythmias or a combination of the three, areas of akinesis or dyskinesis and ejection fraction of $<40\%$. This surgery is performed following a coronary artery bypass graft (CABG)¹².

Contraindications include impaired right ventricular function, pulmonary hypertension, basal dysfunction, systolic pulmonary artery pressure greater than 60mmHg¹².

Dor procedure overcomes the problems related to linear suture excluding the septal extension of myocardial scar from the ventricular chamber, diverting myocardial fibers toward the apex, decreasing the tension on the transitional zone, and aiding the revascularization of the LAD. In a study done by Di Mattie DG et al., concluded that functional and clinical status is improved late after operation in the majority of patients where endoventriculoplasty of LV aneurysm and coronary grafting was done. Patients who benefit most from the operation were those with a normal postoperative contraction pattern, where ejection fraction improved¹³.

C. Mitral Regurgitation Correction

Another harmful effect of remodeling is mitral regurgitation. Mitral re-gurgitation (MR) frequently complicates cardiomyopathy (CM) and results in congestive symptoms¹⁴. Severe mitral regurgitation is a complication of end-stage cardiomyopathy that predicts poor survival⁹.

As the left ventricle dilates the heart assumes a globular shape, the papillary and mitral complex alters, causing restricted opening and due to tethering of the leaflets and distortion of the mitral apparatus. Increasing ventricular dilation results in mitral annulus dilatation. Mitral regurgitation causes a volume overload of the left ventricle that contributes to remodeling and progression of disease. Correction of mitral regurgitation is recommended⁷.

The basic principle of the surgical treatment of functional MR is to restore coaptation of the mitral leaflets by reshaping the mitral annulus with reduction of the septolateral distance, so that the anterior mitral leaflet covers the complete orifice of the mitral valve¹⁵. The complete and rigid annuloplasty rings ensure better outcomes than partial and flexible rings^{16,17}.

Ischemic MR is associated with a poor prognosis, but there is no substantive evidence that the regurgitant lesion per se causes the poor outcomes and surgical correction of MR at the time of coronary artery bypass grafting has little effect on survival¹⁸. Treatment of chronic ischemic MR includes medical therapy for heart failure, cardiac resynchronization therapy and possibly mitral valve surgery or heart transplantation.

D. Heart transplantation

Heart transplant is curative for chronic HF, the survival rate is approximately 50% at 10 years¹⁹.

Indication for heart transplantation are HF, angina and arrhythmias refractory to medical therapy. Severe angina in the absence of HF is not a indication for transplantation. Intractable ventricular arrhythmia are often urgent listing for mechanical support or transplant²⁰.

Contraindications for transplantation are medical or psychological. Most of these are relative contraindication and are considered with relation to the HF. The medical contraindications are age, obesity, malignancy, pulmonary hyper-tension, diabetes, renal dysfunction, peripheral vascular disease and infection. Timing of transplant referral is the greatest challenge for a cardiologist²⁰.

E. Left ventricular assist devices - LVADs

A left ventricular assist device (VAD, also called ventricular assist system or VAS) is a type of mechanical circulatory support device (MCS). It is a mechanical pump that is implanted in patients who have heart failure to help the heart's weakened left ventricle (major pumping chamber of the heart) pump blood throughout the body.

The evolution of mechanical circulatory assist devices,

aimed to bridge the heart to transplantation, or to myocardial recovery, has helped many of patients. Nowadays, these devices are even implanted for long-term support (Destination Therapy), particularly in elderly patients and in those with contraindications to heart transplantation. This may even be the best and the optimal solution to treat heart failure patients in the future²¹. The LVAD will provide blood pressure support; and improve organ function by increasing blood flow.

In unstable patients with end stage HF who are unsuitable for LVAD, a total artificial heart can be used as a bridge to transplantation and this improves survival to transplant and post transplant²². Elective bridge to transplantation was found to be associated with better survival than emergency implantation of assist devices²².

This has become essential in the face of the increasing donor organ shortage, with many patients receiving permanent assist devices and fewer receiving heart transplants. Various assist systems are now able to improve physical conditions and offer the patient good quality of life for several years. This is also true for patients with contraindications for heart transplantation²¹.

Authors declare no conflict of interest.

References

- 1) Moss RL, Fitzsimons DP Frank-Starling Relationship Long on Importance, Short on Mechanism. *Circ Res.* 2002; 90:11-13.
- 2) El-Zaru M, DeNofrio D. End-stage Heart Failure: Surgical Therapy and Implantable Devices. *Curr Treat Options Cardiovasc Med.* 2002, 4:511-520.
- 3) Patten RD, Udelson JE, Konstam MA. Ventricular remodeling and its prevention in the treatment of heart failure. *Curr Opin Cardiol* 1998, 13:162-167.
- 4) Blom AS, Acker MA. The Surgical Treatment of End-Stage Heart Failure. *Curr Probl Cardiol.* 2007; 32(10):553-99.
- 5) Beltrami CA Finato N, Rocom et al. Structural Basis of End-Stage Failure in Ischemic Cardiomyopathy in Humans. *Circulation.* 1994; 89:151-163
- 6) Anversa P, Li P, Zhang X, Olivetti G, Capasso JM. Ischemic myocardial injury and ventricular remodeling. *Cardiovasc Res.* 1993; 27:145-157.
- 7) Jessup M, Brozena S. Heart Failure. *N Engl J Med* 2003; 348:2007-18.
- 8) Pocar M, Moneta A, Grossi A, Donatelli F. Coronary Artery Bypass for Heart Failure in Ischemic Cardiomyopathy: 17-Year Follow-Up. *Ann Thorac Surg* 2007; 83:468-74.
- 9) Deng MC, Ascheim DD, Edwards NM, Naka Y. End-stage heart failure: which options? *Eur Heart*

- J Supplements 2002; 4 :D122-D130.
- 10) Ennker J, Bauer s, Ennker IC. Revascularization surgery as a treatment concept for heart failure. HSR Proc Intensive Care Cardiovasc Anesth. 2013; 5(2): 89-97.
 - 11) Dor V. Left ventricular aneurysms: the endoventricular circular patch plasty. Semin Thorac Cardiovasc Surg 1997; 9:123.
 - 12) Menicanti L, Di Donato M. The Dor procedure: what has changed after fifteen years of clinical practice? J Thorac. Cardiovasc. Surg. (2002); 124 (5): 886-90.
 - 13) Di Mattia DG Di Biasi P, Salati M et al. Surgical treatment of left ventricular post-infarction aneurysm with endoventriculoplasty: late clinical and functional results. Eur J Cardiothorac Surg. 1999;15 :413-418.
 - 14) Bach DS, Armstrong WF, Bolling SF. Early Improvement in Congestive Heart Failure Following Correction of Secondary Mitral Regurgitation in End-Stage Cardiomyopathy. J Am Coll Cardiol. 1995;25(251):23A-23A
 - 15) Starck CT, Schönrrath F, Scherman J, Caliskan E, Falk V. Surgical management of functional mitral regurgitation in heart failure patients. Cardiovasc Med 2013;16(3):82-86
 - 16) Spoor MT, Geltz A, Bolling SF. Flexible versus nonflexible mitral valve rings for congestive heart failure: differential durability of repair. Circulation. 2006; 114:167-171.
 - 17) Silberman S, Klutstein MW, Sabag T, Oren A, Fink D, Merin O, et al. Repair of ischemic mitral regurgitation: comparison between flexible and rigid annuloplasty rings. Ann Thorac Surg. 2009; 87:1721-6.
 - 18) Acker MA, Parides MK, Perrault LP, et al. Mitral-valve repair versus replacement for severe ischemic mitral regurgitation. N Engl J Med 2014; 370:23.
 - 19) Garbade J, Barter MJ, Bittner HB, Mohr FW. et al. Heart Transplantation and Left Ventricular Assist Device Therapy: Two Comparable Options in End-Stage Heart Failure? Clin. Cardiol. 2013; 36(7): 378-382.
 - 20) Kittleson MM, Kobashigawa JA. Management of Advanced Heart Failure: The Role of Heart Transplantation. Circulation. 2011; 123:1569-1574.
 - 21) Walter D, Hetzer R. Surgical treatment concepts for heart failure. HSR Proc Intensive Care Cardiovasc Anesth. 2013; 5(2): 69-75.
 - 22) Friedrich EB, Bohm M. Management of end stage heart failure. Heart 2007; 93:626-631.