

Review with Hypothesis

The Undescended Testis – A Review with Hypothesis

Shah Dupesh Khan*, Shiva Krishna**, Pandiyan N***

Fellow in Andrology, Dept. of Reproductive Medicine, Chettinad Super Speciality Hospital, **Jr. Embryologist, Gunasheela Hospital, Bangalore, *Prof. & HOD, Dept. of Reproductive Medicine, Chettinad Super Speciality Hospital, Chennai, India.



Dr Shah Dupesh Khan graduated in medicine from Chengalpattu, Government Medical College, Kancheepuram District in the year 2012. He finished his post graduation in Clinical Embryology and is currently pursuing Fellowship in Andrology at Chettinad Super Speciality. Dr Shah also provides medico-legal consulting services to international law firms through Medlicit Global. He was also a delegate at the ASPIRE² 2013 international conference on ART & Reproductive Medicine.

Corresponding author - Dr. Shah Dupesh Khan (drsdk123@gmail.com)

Abstract

Testicular Descent is enigmatic in the sense the exact interaction between anatomical, hormonal and molecular factors coordinating the various phases of descent remains to be elucidated. This review explores testicular descent in various species along with anatomical and hormonal factors regulating descent. But why does the testis not descend? Both bilateral and unilateral undescended testis has an effect on the individual's future fertility. We have reviewed the literature and presented briefly on the various causes that could lead to testicular undescend. Lastly we have also given a hypothesis that could account for testicular undescend.

Key Words: AMH, Gubernaculum, INSL3, Cryptorchidism

Chettinad Health City Medical Journal 2014; 3(4): 161 - 166

Descent of the testes is a complex multistep event well orchestrated in time and space descent. It is a process during which the testes move from a high abdominal pararenal position to an extra-abdominal position. Despite our excellent understanding about the mammalian testis and its function, the complex interplay between anatomical, hormonal, genetic and mechanical factors involved in descent of testes remains to be elucidated.

A. Testes Descent in Various Species

Testes descent does not take place uniformly across all mammalian species. Absence of descent also is seen among the ancient evolutionary mammalian species of Monotremata, Edentata, the aquatic species of Cetaceans and of Peningulata (Elephant and Hyrax). In Cetaceans, secondary; as an adaption to aquatic environments, whereas in species of Peningulata, it is primary¹. Progressively through evolution however the testis has acquired a position lower and lower, finally coming to be placed in a specialized sac called the scrotum which provides a temperature of 33 degree Celsius which is lower than the rest of the body² (34 – 37°C). The high temperature sensitivity of the testes and its effect on the germ cell development and Sertoli cell function is well documented in the literature through experiments on various animal models; however, the exact genetic basis of this regulation is yet unknown^{3, 4}. The most interesting question to ask though is, 'Why does the testis descend at all in man?' Descent does not seem to offer any particular advantage, but rather puts the testis in a vulnerable position; does the testes search out and seek a lower temperature?

The timing of testes decent varies considerably among mammals. At birth testes descent is generally complete in humans, pigs, rabbits and horses. In cattle and deer, descent is complete early in gestation, whereas in mouse and dogs, the descent takes place after birth⁵. Across most of these species, two phases of testicular descent namely, an abdominal phase and an inguino- scrotal phase are distinctly observed.

B. Timeline of Testis Development

During fetal life, the formation of the bipotential gonad takes place between the 5th and 6th week. At this point of time, primordial germ cells (PGC) arising from the endoderm of the yolk sac migrate to genital ridge that is present medial to the mesonephros. The PGC differentiate into gonocytes. Activation of the SRY gene along with *wt1*, *sox9*, *fgf9* and *sf1*, leads to the formation of Sertoli cells from the coeloemic epithelium⁶. The Sertoli cells surround the gonocytes giving rise to testicular cords between 6 and 7 weeks, and this marks the first sign of sexual differentiation in the ambisexual gonad^{6,7,8}. By 9 weeks steroid secreting Leydig cells are formed. Antimullerian hormone (AMH) produced by the Sertoli cells causes the mullerian duct to regress which otherwise would lead to formation of female internal reproductive organs, while testosterone produced by the Leydig cells stabilizes the Wolffian duct and causes it to differentiate into male reproductive organs. Testosterone converted to Dihydrotestosterone (DHT) masculinizes the external genitalia. These events take place between weeks 8 and 12 of gestation⁹.

C. The Gubernaculum's role in testis descent – Anatomical factors

Between 7 and 9 weeks the connection between the mesonephros and testes disappears. The metanephros (final kidney) migrates from sacral to lumbar region causing a displacement of the gonad caudal to the kidney¹⁰. Testis descent in humans takes place in two phases, in the first phase the swollen gubernaculum anchors the testis to the inguinal region, while the abdomen is enlarging. This is the relative trans-abdominal phase of testis movement. The ovary on the other hand moves cranially, relatively speaking of course. Simultaneously, regression of the cranial suspensory ligament allows the testis to descend. In humans, the first phase of descent is usually complete by 15 weeks¹¹.

John Hunter and Von Haller first described the gubernaculum as a fibrous cord connecting the testis with the scrotum^{12,13}. The gubernaculum contains predominantly mesenchymal cells in man. Enlargement of the gubernaculum also termed, as the 'swelling reaction', is due to an increase in cell division and hyaluronic acid content¹⁴. During descent, the proximal portion of the gubernaculum incorporates into the bulb, thereby placing the testis at close proximity to the inguinal ring, following which an increase in the abdominal pressure may push the testis out of the abdomen^{15,16,17}. Studies in various animal models have shown the aforementioned mechanism of gubernacular shortening to be an important mechanism in testis descent, as transection of the cord leads to aberrant gonad position at various abdominal sites¹⁷. In mice with mutations of *hoxa10* gene, abnormally long gubernacular cords along with undescended testis are seen¹⁸. *hoxa10* is growth regulatory gene, expressed in developing limb buds¹⁹. The gubernaculum is likened to a limb bud that guides the testis to reach its position. Although the cranial suspensory ligament regresses to allow gonad descent, its role as the key factor in allowing descent is under dispute.

The second phase of descent, termed as the inguinoscrotal phase, requires the testis to be anchored near the internal inguinal ring, followed by active growth and enlargement of the gubernaculum with the processes vaginalis. An absolute increase in the wet mass of the gubernaculum, compared to testis is noted. This causes a dilatation of the inguinal canal, thereby allowing the testis, epididymis and gubernaculum to move as a single entity through the inguinal canal. This process is partly aided by an increase in abdominal pressure²⁰. Fibrosis and shrinkage of the gubernaculum may also contribute to passage of testis through the inguinal canal. After this phase, the peritoneum pouch of the processes vaginalis ensconces the testis, gubernaculum and epididymis. The gubernacular caudal end does not reach the bottom of the scrotum. Following testis descent to the bottom of the scrotum, the connection to the peritoneum involutes. The gubernaculum shrinks and persists as the scrotal ligament. The inguino-scrotal phase of descent is complete by 35 weeks²⁰ (Fig 1).

D. Hormonal Regulation of Testis Descent

1. Androgens: Androgens are not required for the first phase of testis descent. Even in patients with complete androgen insensitivity syndrome, in a significant number of patients the testis usually traverses the abdomen²¹. The gubernacular swelling reaction occurs in mouse and humans with complete androgen resistance and in rats that are prenatally exposed to Flutamide²². Androgens play an important role in the inguinoscrotal phase of descent. For both gubernacular migration and regression, numerous studies have shown that a high local level of androgens are required, although the exact site of androgen action on the gubernaculum remains to be identified²³.

In rodents, prenatally androgens may indirectly act on the gubernaculum by a yet unknown mechanism on the genito-femoral nerve nucleus (GFN) to induce a sexually dimorphic GFN nucleus²⁴. Since the GFN supplies the gubernaculum from its posterior and caudal surface, transection of the GFN in rodents leads to Cryptorchidism. The GFN along with the neurotransmitter calcitonin gene related peptide (CGRP), are implicated in rodent models of cryptorchidism. A rhythmic increase in Gubernacular contraction both in vivo and in vitro is documented in response to CGRP. Antiandrogen administration in rodents led to alternations in GFN nucleus along with testis maldescent^{24,25}. The role of CGRP and GFN in human models of cryptorchidism is less persuasive though. Although children with spina bifida have associated undescended testis, this example is too non-specific²⁶.

2. AMH: Antimullerian hormone (AMH) or Mullerian inhibiting substance (MIS) produced by Sertoli cells of the testis causes the regression of the embryonic Mullerian duct. In addition, numerous other functions such as the early differentiation of the testis, postnatal germ cell development and the important function of regulating the first phase of testicular descent have been postulated²². Evidence for AMH role in regulating the first phase of descent comes from studies in mice models with intra-abdominal testis; these animals have persistent Mullerian ducts. The next evidence comes from the finding that a proportion of retained Mullerian ducts are found associated with cryptorchidism in intersex as well as estrogen treated fetal mice²⁷. The third line of evidence comes from the finding that in patients with Persistent Mullerian Duct Syndrome (PMDS), a majority of them present with undescended testis, a long and thin Gubernacular cord and mutation of the MIS gene thereby suggesting that in these patients the Gubernacular swelling reaction failed to occur leading to undescended testis²⁸. Evidence against AMH comes from the fact that cultured fibroblasts from pig gubernaculum do not divide in the presence of AMH²⁹, raising the question – does AMH cause the Gubernacular swelling? Another important point going against AMH is that in patients with PMDS, non-descent of testis could be a result of anatomical blockade due to a connection between the Mullerian duct and undescended testis³⁰.

Furthermore, not all patients with undescended testis present with persistent Mullerian duct remnants.

3. INSL3: INSL3, a peptide, plays a crucial role in gubernacular swelling reaction in mice³¹. Disruption of the *insl3* gene leads to bilateral intrabdominal testis and malformed gubernaculum³². In female mice, ovaries descend to the inguinal region when INSL3 is over expressed³³. The role of INSL3 in human testis descent is not clear since only a small minority of patients presenting with unilateral or bilateral cryptorchidism harbor mutations in the *insl3* gene³⁴.

which also termed as mini-puberty stimulates the gonocytes to differentiate in to type A spermatogonium. Testosterone levels wane by 6 months; following which AMH levels rise and remain elevated until puberty, and then it falls⁴⁶. The regulation of this complex transformation and event is unknown⁴⁶.

The post-natal germ cell development is impaired in the undescended testis, leading to an increase in the

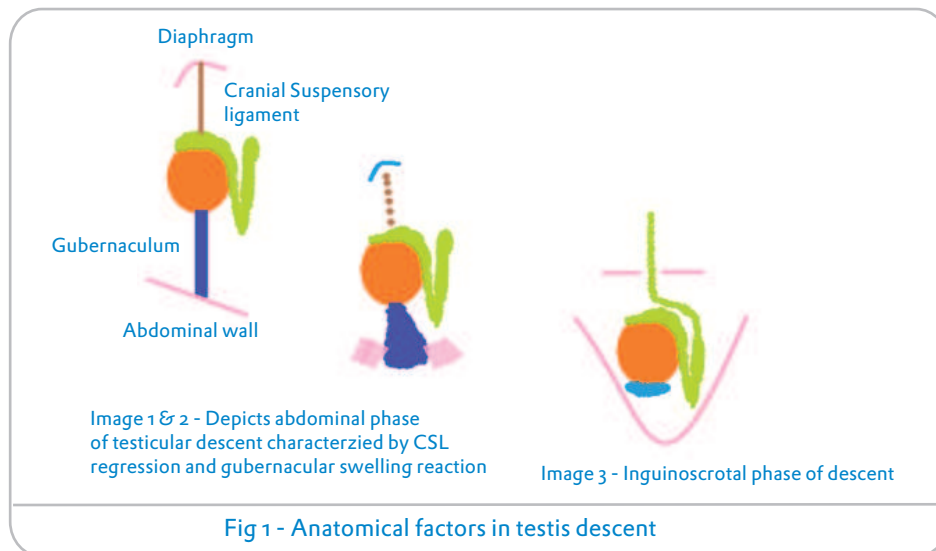


Fig 1 - Anatomical factors in testis descent

Phases of testis descent

E. Cryptorchidism: The incidence of isolated non syndromic congenital cryptorchidism; including only male babies born with a weight greater than 2500 gms in several large series has been estimated to be between 2.2 and 3.8%^{35,36}. Among full term males descent takes place spontaneously in 50 -70% usually in the age group of one to three months, although among premature neonates not only is the incidence of cryptorchidism higher, but also the presentation is bilateral with descent occurring at the end of one year³⁷. In humans, cryptorchidism occurs due to defects commonly in the inguinoscrotal phase of descent, and only 5% of undescended testes are in the abdominal position³⁸. Common causes of cryptorchidism include a defective androgen secretion prenatally, and defects in the placental or pituitary gonadotropin production. The abnormal androgen secretion could affect the development of the GFN nucleus and CGRP production leading to defective gubernacular migration resulting in impaired testicular descent³⁹. Infants presenting with urological disorders like prune belly syndrome, posterior urethral valves; abdominal wall defects and neural tube defects also frequently have undescended testis^{40,41,42,43}. Corbus reported cryptorchidism among six brothers in a family⁴⁴; Wiles has also reported cryptorchidism among three successive generations of a family⁴⁵, thereby suggesting a familial occurrence of cryptorchidism.

1. Post Natal Germ Cell Development: A surge in pituitary gonadotropin causes a sudden increase in testosterone at the age of 2 to 4 months; this process

number of gonocytes, which are pluripotent and may lead to Carcinoma in situ cells (CIS) and ultimately resulting in an increased risk of testicular cancer in the undescended testis⁴⁶. Cryptorchidism affects the germ cells, causing their degeneration and a reduction in their number; thus leading to infertility. A correlation between the numbers of dark type A spermatogonium at three to six months of age and sperm counts after puberty is seen among patients with undescended testis. In animal models, most authors suggest that there is a secondary degeneration of the germ cells owing to the higher intra-abdominal temperatures. In humans, a decrease in the androgen production could affect postnatal germ cell development and germ cell numbers⁴⁶ thus suggesting a primary testicular defect. Further serum androgen levels were not measurable in a group of infants with cryptorchidism at 3 months of age⁴⁷.

2. Histopathological finding in the undescended testis:

Histological findings of the undescended testis reveal varying patterns from Sertoli cell only to normal⁴⁸. This also depends on the extent of descent, age of biopsy or Orchidopexy and duration of cryptorchidism. A rapid decrease in the number of germ cells is found in patients with undescended testis; starting from 6 months until 2 years; further, only less than 10% of patients would have normal number of spermatogonium after 1.5 years of age^{10,48,49}. An increasing number of patients by 2 years of age would have essentially no germ cells on histological examinations. Another interesting finding is that, even in the normally descended contra lateral testis; germ cell numbers and testis differentiation is affected to a certain degree^{48,49}. The presence of dark

spermatogonium on histological examination is associated with future fertility. In bilateral cryptorchidism, if no germ cells are found there is a 78 – 100% risk of oligozoospermia (sperm count less than 5 million/ml) in adulthood⁴⁹. In cases of bilateral cryptorchidism, we postulate that; a congenital loss of germ cell has already occurred in utero, thereby suggesting a primary testicular defect.

3. Orchidopexy – is there a need? - The success of Orchidopexy can best be determined only in cases of bilateral cryptorchidism that are fixed followed by evaluation of the patient's future paternity.

Unfortunately, our literature search revealed only a few studies. Notable among them was a study by Gross and Jewett (1956). The Boston authors had reported that 30 of 38 men who underwent surgery for Bilateral cryptorchidism were fertile. The drawback of the study; was that there was no mention of the testicular position at the time of surgery⁵⁰. In patients presenting with unilateral undescended testis, a major impact on future paternity is not expected.

An increase in the number of cases undergoing an Orchidopexy in recent times is attributable to the retractile or ascending testis. Whether these two clinical entities are the same or different is to be elucidated. Although an impact on future paternity is not expected in either case, it is important to correctly differentiate both entities from true congenital Cryptorchidism⁵¹.

Hypothesis and conclusion

The exact mechanism behind the undescended testis is unknown. Animal models of Cryptorchidism cannot be extrapolated to human studies, due to key differences in the timing of development. From our literature review and personal experience, we would like to hypothesize that 'The reason the testis does not descend lies within the testis itself. It is not the undescended testis that is abnormal in its function; rather a testis that is functionally abnormal will not complete its descent'.

References

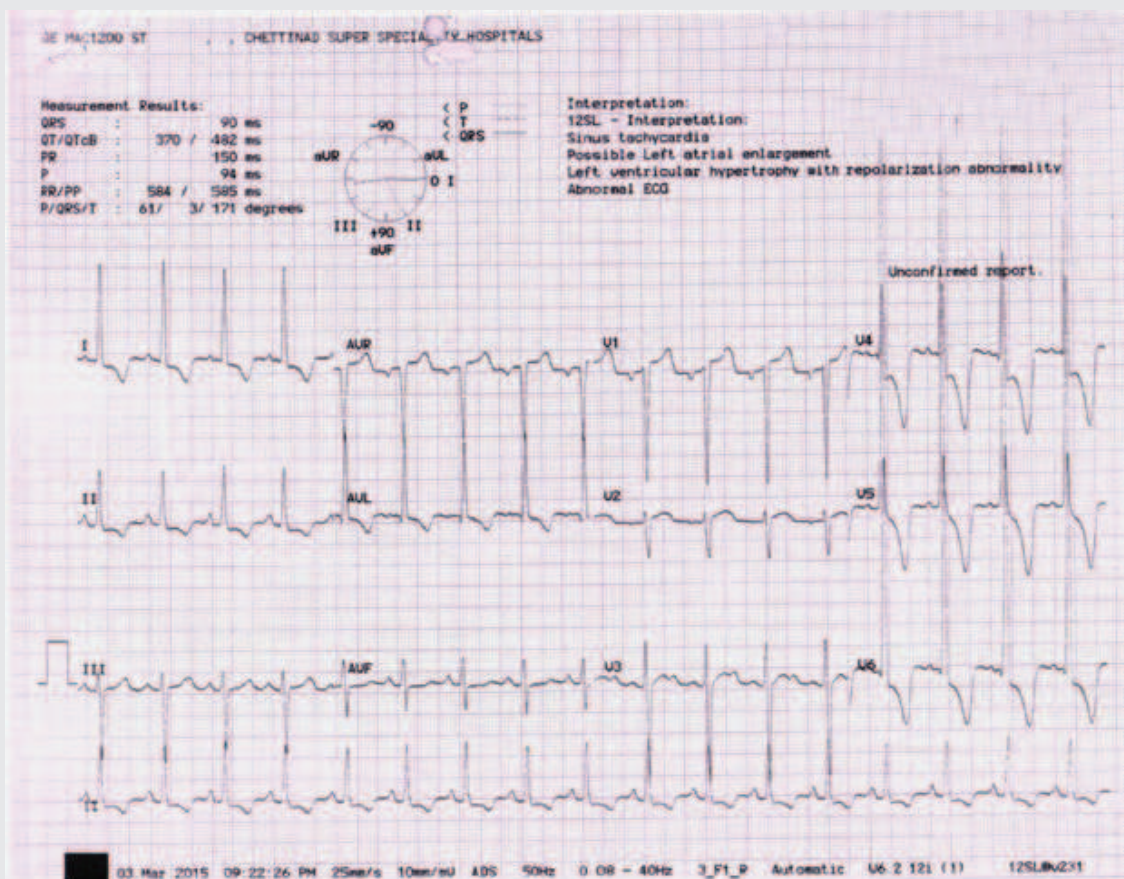
- 1) Freeman S. The evolution of the scrotum: a new hypothesis, *J Theor Biol* 1990; 145: 429–445.
- 2) Zorgniotti AW. Temperature and environmental effects On the Testis. New York: Plenum Press 1991.
- 3) Setchell BP. The Parkes Lecture Heat and the testis. *J Reprod Fertil* 1998; 114: 179–194.
- 4) Zini, A, Abitbol J, Schulsinger D, Goldstein M, and Schlegel PN. Restoration of spermatogenesis after scrotal replacement of experimentally cryptorchid rat testis: assessment of germ cell apoptosis and eNOS expression. *Urology* 1999; 53: 223–227.
- 5) Amann, RP and Veeramachaneni. Cryptorchidism in common eutherian mammals, *Reproduction* 2007; 133: 541–561.
- 6) Quigley CA. Genetic basis of gonadal and genital development 2006. *Endocrinology* 5th ed. Philadelphia: Elsevier Saunders.
- 7) Brennan J, Capel B. One tissue, two fates: molecular genetic events that underlie testis versus ovary development. *Nat Rev Genet* 2004; 5: 509–21.
- 8) Barteczko KJ and Jacob MI. The testicular descent in human. *Adv Anat Embryol Cell Biol* 2000; 156: 1–98.
- 9) Hughes IA. Mini review: sex differentiation. *Endocrinology* 2001; 142: 3281–7.
- 10) Cortes D. Cryptorchidism—aspects of pathogenesis, histology and treatment, *Scand J Urol Nephrol Suppl* 1998; 196: 1–54.
- 11) Hutson JM, Hasthorpe S. Abnormalities of testicular descent *Cell Tissue Res* 2005; 322: 155–8.
- 12) Hunter J. Observations on the state of the testis in the foetus and on the hernia congenital, In Hunter, W. *Medical Commentaries*, Part 1; 1762, p. 75.
- 13) Von Haller A, *Opuscula Pathologica* 1755; Bousquet, Lausanne.
- 14) Heyns CF, Human HJ, Werely CJ, De Klerk DP. The glycosaminoglycans of the gubernaculum during testicular descent in the fetus *J Urol* 1990; 143: 612–617
- 15) Husmann DA, Levy JB. Current concepts in the Pathophysiology of testicular descent *Urology* 1995; 46: 267–276
- 16) Attah AA, Hutson JM. The role of intra-abdominal pressure in Cryptorchidism *J Urol* 1993; 150: 994–99
- 17) Quinlan DM, Gearhart JP, Jeffs RD. Abdominal wall defects and cryptorchidism: an animal model *J Urol* 1988; 140: 1141–1144.
- 18) Rijli FM, Matyas R, Pellegrini M, Dierich A, Gruss P, Dolle P, Chambon P. Cryptorchidism and homeotic transformations of spinal nerves and vertebral in Hoxa-10 mutant mice *Proc Natl Acad Sci* 1995; 92: 8185–8189.
- 19) Ohuchi H, Nakagawa T, Yamamoto A, Araga A, Ohata T, Ishimaru Y, Yoshioka H, Kuwana T, Nohno T, Yamasaki M, Itoh N & Noji S. The mesenchymal factor, FGF10, initiates and maintains the outgrowth of the chick limb bud through interaction with FGF8, an apical ectodermal factor *Development* 1997; 124: 2235–2244.
- 20) Barteczko KJ and Jacob MI. The testicular descent in human, Origin, development and fate of the gubernaculum Hunteri, processus vaginalis peritonei, and gonadal ligaments. *Adv Anat Embryol Cell Biol* 2000; 156: 1–98

- 21) Hughes I and Acerini CL. Factors controlling testis descent. *Eur J Endocrinol* 2008; 159: Suppl : S75-82.
- 22) Hutson JM and Hasthorpe S. Anatomical and Functional Aspects of Testicular Descent and Cryptorchidism, 2014; 18(2): 259-280.
- 23) Elder JS, Isaacs JT, Walsh PC. Androgenic sensitivity of the gubernaculum testis: evidence for hormonal/mechanical interactions in testicular descent *J Urol* 1982; 127: 170-176.
- 24) Shono T, Suita S, Kai H and Yamaguchi Y. Short-time exposure to Vinclozolin in utero induces testicular maldescent associated with a spinal nucleus alteration of the genitofemoral nerve in rats. *Journal of Pediatric Surgery* 2004; 39: 217-219.
- 25) Shono T, Zakaria O, Imajima T and Suita S. Does proximal genito femoral nerve division induce testicular maldescent or ascent in the rat? *BJU International* 1999; 83: 323-326.
- 26) Hutson JM, Beasley SW, Bryan AD. Cryptorchidism in spina bifida and spinal cord transection: a clue to the mechanism of trans-inguinal descent of the testis. *J Pediatr Surg* 1994; 23: 275-277.
- 27) Abe T and Hutson JM. Gonadal migration in ambiguous genitalia. *Pediatr Surg Int.* 9; 547-550
- 28) Josso N, Fekete C, Cachin O, Nezelof C, Rappaport R. Persistence of Mullerian ducts in male pseudo-hermaphroditism, and its relationship to Cryptorchidism, *Clin Endocrinol (Oxf)* 1983; 19: 247-258.
- 29) Fentener Van Vlissingen JM, Van Zoelen EJJ, Ursem PJF, Wensing CJG. In vitro model of the first phase of testicular descent: identification of a low-molecular weight factor from fetal testis involved in proliferation of gubernaculum testis cells and distinct from specified polypeptide growth factors and fetal gonadal hormones. *Endocrinology* 1988; 123: 2868-2877.
- 30) Josso N, Cate RL, Picard JY, Vigier B, Di Clemente N, Wilson C, Imbreud S, Pepinsky RB, Guerrier D, Boussin L, Lageai L, Carre Eusebe D. Anti-Mullerian hormone: the Jost factor. *Recent Prog Horm Res* 1993; 49:1-59
- 31) Zimmermann S, Steding G, Emmen JM, Brinkmann AO, Nayernia K, Holstein AF, Engel W & Adham IM. Targeted disruption of the *Insl3* gene causes bilateral Cryptorchidism. *Molecular Endocrinology* 1999; 13: 681-691.
- 32) Overbeek PA, Gorlov IP, Sutherland RW, Houston JB, Harrison WR, Boettger Tong HL, Bishop CE and Agoulnik AI. A transgenic insertion causing cryptorchidism in mice. *Genesis* 2001; 30: 26-35.
- 33) Adham IM, Steding G, Thamm T, Bullesbach EE, Schwabe C, Paprotta I and Engel W. The overexpression of the *Insl3* in female mice causes descent of the ovaries. *Molecular Endocrinology* 2002; 16: 244-252.
- 34) Yamazawa K, Wada U, Sasagawa I, Aoki K, Katsuhiko U and Ogata T. Mutation and polymorphism analyses of *INSL3* and *LGR8/GREAT* in 62 Japanese patients with Cryptorchidism. *Hormone Research* 2007; 67: 73-76.
- 35) Cryptorchidism: a prospective study of 7500 consecutive male births, 1984-8, John Radcliffe Hospital Cryptorchidism Study Group. *Arch Dis Child* 1992; 67: 892.
- 36) Scorer CG, Descent of the testicle in the first year of life. *Brit J Urol* 1955; 27: 374
- 37) Beumann B, Henriksen H, Villumsen AL, Westh A and Zachau-Christiansen B. Incidence of undescended testis in the newborn. *Acta Chir Scand. suppl* 1961; 283-289.
- 38) Boisen KA, Kaleva M, Main KM, Virtanen HE, Haavisto AM, Schmidt IM. Difference in prevalence of congenital cryptorchidism in infants between two Nordic countries. *Lancet* 2004; 363: 1264-9.
- 39) Abney TO and Keel BA. *The Cryptorchid Testis*, CRC Press, Boca Raton 1989, FL, pp 1-176
- 40) Nunn IN and Stephens FD. The triad syndrome: a composite anomaly of the abdominal wall, urinary system and testes. *J Urol* 1961; 86: 782-794.
- 41) Kreuger RP, Hardy BE, and Churchill BM. Cryptorchidism in boys with posterior urethral valves. *J Urol* 1980; 124: 101-102
- 42) Kaplan LM, Koyle MA, Kaplan GW, Farrer JH and Rajfer J. Association between abdominal wall defects and Cryptorchidism. *J Urol* 1986; 136: 645-647
- 43) Kropp KA and Voeller KKA. Cryptorchidism in meningomyelocele. *J Pediatr* 1981; 99: 110-113.
- 44) Corbus BC and O' Connor V J. The familial occurrence of undescended testes. *Surg Gynec Obstet.* 1922; 34: 237
- 45) Wiles P. Family tree, showing hereditary undescended right testis and associated deformities. *Proc roy Soc Med* 1934; 28: 157.
- 46) Hutson JM, Li R, Southwell BR, Petersen BL, Thorup J, Cortes D. Germ cell development in the postnatal testis: the key to prevent malignancy in cryptorchidism? *Front Endocrinol* 2012; 3:176.
- 47) Raivio T, Toppari J, Kaleva M, Virtanen H, Haavisto AM, Dunkel L. Serum androgen bioactivity in cryptorchid and noncryptorchid boys during the postnatal reproductive hormone surge. *J Clin Endocrinol Metab* 2003; 88: 2597-9.

- 48) Cortes D, Thorup JM, Visfeldt J. Cryptorchidism: aspects of fertility and neoplasms, A study including data of 1,335 consecutive boys who underwent testicular biopsy simultaneously with surgery for Cryptorchidism. *Horm Res* 2001; 55: 21-7.
- 49) Cortes D, Thorup J, Petersen BL. Testicular histology in cryptorchid boys aspects of fertility. *J Ped Surg Special*, 2006; 1: 34-7.
- 50) Gross RE and Jewett TC. Surgical experiences from 1,222 operations for undescended testis. *J Amer med Ass* 1956; 160: 634.
- 51) Barthold JS and Gonza R. The epidemiology of congenital Cryptorchidism 2003; 170: 2396-2401.

Diagnose the condition

24 year old male presented with hypertension to the cardiac clinic.



Dr. M.Chokkalingam, Consultant Cardiology, CSSH.

Answer in page : 180