

# Case Report

## A Rare Presentation of Parapharyngeal Space Tumours: Pleomorphic Adenoma

K Priya\*, P Thirunavukarasu\*\*, S B Jothi Ramalingam\*\*\*, L Jagadeesh Marthandam\*\*\*\*, P Preethi\*\*\*\*  
S Prabakaran\*\*\*\*\*, S Sivakami\*\*\*\*\*, R B Namasivaya Navin\*\*\*\*\*

\*Assistant Professor, \*\*Associate Professor, \*\*\*Professor & HOD, \*\*\*\*Senior Resident, \*\*\*\*\*Post Graduate, Dept. of ENT, Chettinad Hospital & Research Institute, Chennai, India.



Dr. K. Priya did her graduation in MBBS from Rajah Muthiah Medical College & Hospital, Chidambaram & Postgraduation in Otorhinolaryngology and Head & Neck Surgery from Mahatma Gandhi Medical College and Research Institute, Pondicherry. Currently she is working as Assistant Professor at Chettinad Medical College & Research Institute. Her Areas of Interest Include Endoscopic Nasal Surgeries, Cochlear Implant and Head & Neck Surgical Oncology.

Corresponding author - Priya Kanagamuthu (catchpriya.29@gmail.com)

Chettinad Health City Medical Journal 2015; 4(4): 185 - 187

### Abstract

Parapharyngeal space tumors accounts for only 0.5% of Head & Neck Neoplasms. Parapharyngeal space tumors usually present with a neck mass or an intraorally submucosal mass displacing the lateral pharyngeal wall, tonsils and soft palate. CT & MRI predict the origin, location and size of tumors in parapharyngeal space. Surgery is the best treatment for parapharyngeal space tumors. Approach usually depends on the size of location of the mass. In our case we used combined transcervical and transoral approach. Transoral removal of the mass with Transoral Cervical-vascular control in the neck would be safer.

**Key Words:** Parapharyngeal space tumors, Pleomorphic adenoma, Head and Neck spaces.

### Introduction

Parapharyngeal space tumours account for only 0.5% of head and neck neoplasms<sup>1</sup>. Parapharyngeal space divides into prestyloid and post styloid compartments<sup>2</sup>. Parapharyngeal space is an inverted pyramid shaped space starting from the base of the skull to the greater cornu of hyoid bone<sup>3</sup>.

Prestyloid space has a portion of the parotid gland and its lymph nodes and the poststyloid space has internal carotid artery, the internal jugular vein, last four cranial nerves i.e; IX, X, XI and XII cranial nerves and the sympathetic chain<sup>4</sup>.

Tumours of the parapharyngeal space may originate from any of the above mentioned structures of which 70–80% are benign, and 20–30% are malignant. Most of the parapharyngeal space tumors are of salivary or neurogenic origin.

Parapharyngeal space tumours usually present with a neck mass or an intraorally submucosal mass displacing the lateral pharyngeal wall, tonsils and soft palate antero-medially. FNAC of the oral mass is accurate in 90% of cases; CT SCAN predict the nature of lesion and helps in planning the procedure for the surgeon; MRI predict the origin, location and size of tumours in the parapharyngeal space<sup>5</sup>.

Surgery is the best treatment for parapharyngeal space tumours<sup>6-8</sup>. Approaches can be transoral, transcervical, combined transoral and transcervical depends upon the size and location of the tumour in parapharyngeal space tumours<sup>9</sup>.

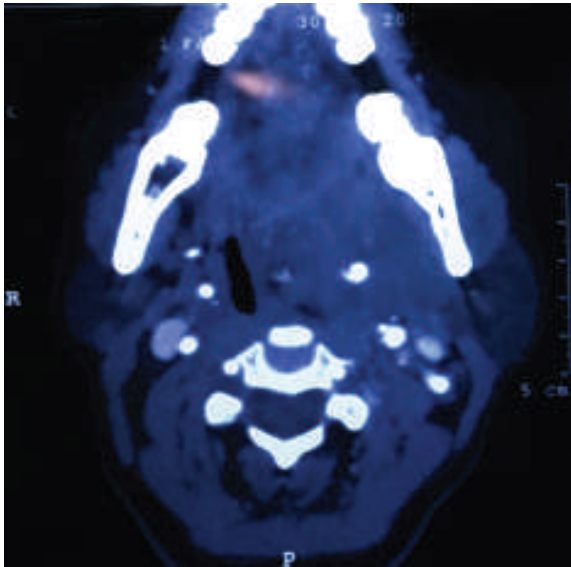
### Case Report

A 55year old female presented with complaints of change of voice on physical examination of oropharynx, a swelling was seen on the left tonsillar fossa of size approximately 4\*3cm which pushes the uvula, soft palate, tonsils medially (fig-1). There was no other symptoms related to pressure effect of the mass.

Patient was evaluated with CECT of Neck which revealed heterogeneously enhancing lobulated mass with internal calcifications measuring 41(AP)\*42(TR)\*45(CC)mm noted on the left parapharyngeal space (fig-2). The mass was seen obliterating to tonsillar fossa, causing of remodelling of left pterygoid plates anteriorly and medially the mass is pushing the pharynx laterally causing mass effect, inferiorly mass was seen extending upto C3 vertebrae. The mass was not encroaching surrounding carotid vessels.

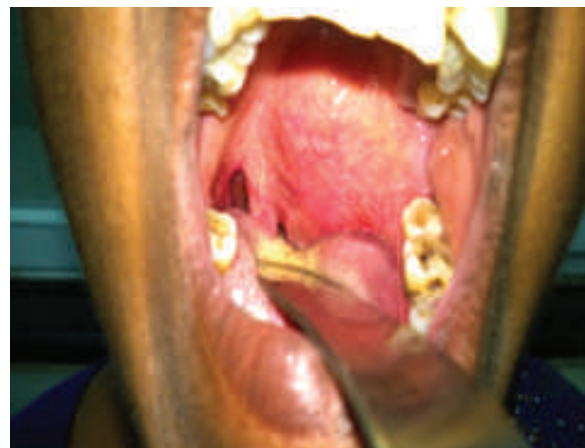

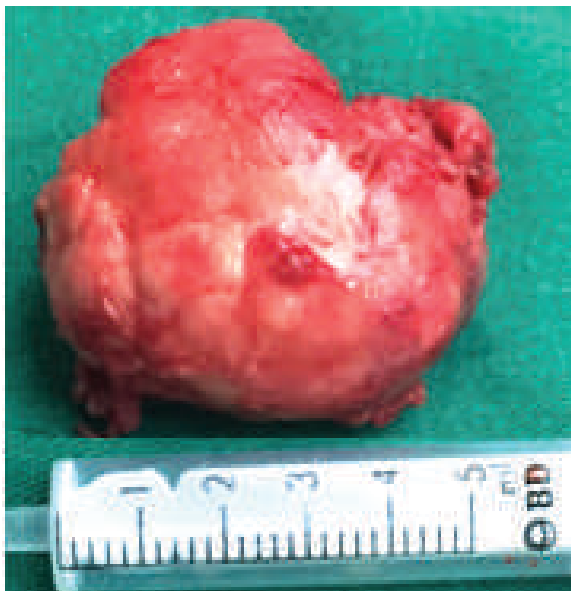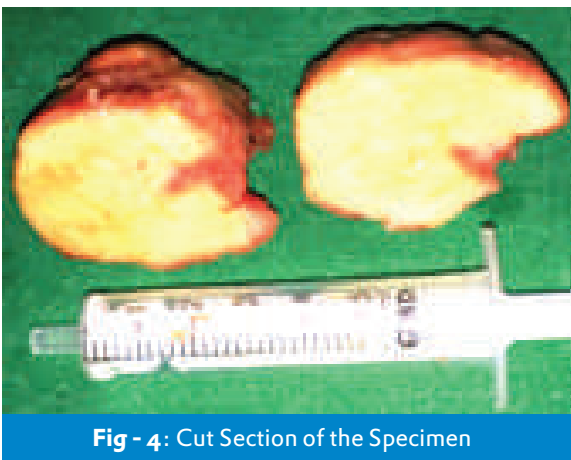
Fig - 1: Mass in Oropharynx



**Fig - 2:** Mass in Oropharynx

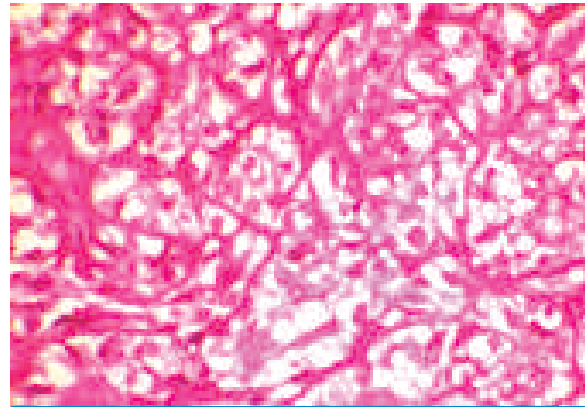


**Fig - 3:** Specimen Removed



**Fig - 4:** Cut Section of the Specimen

FNAC of the mass from oropharynx showed squamous epithelial cell and occasional lymphocytes on a haemorrhagic background. No atypical cells was seen and they suggested for excision biopsy.



**Fig - 5:** Showing clear cell Myoepithelial component

With the above investigations patient was taken up for excision biopsy, under general anaesthesia with a Transcervical approach left parapharyngeal space was reached and a mass which was hard in consistency was noted and the same was removed. The common carotid, external and internal carotid artery was identified and control was kept. Following that through Transoral approach the intraoral mass was excised by making a incision over the substance of mass. Transoral incision was closed with 2-0 chromic catgut and the Transcervical wound was closed in layers with 3-0 vicryl and skin was sutured 3-0 ethylon, after placing the suction drain in the neck. Specimen was sent for biopsy (fig-3 & 4). Post operative period was uneventful. Biopsy report revealed pleomorphic adenoma of minor salivary gland – parapharyngeal lesion(fig-5).

## Discussion

In total percentage of salivary gland tumours about 10% of tumours are minor salivary gland tumours, out of which about 40% are malignant<sup>10</sup>. Commonest sites for minor salivary gland tumours are lips, buccal mucosa, floor of mouth, palate, tongue, retromolar area and pharynx<sup>11</sup>. Prestyloid compartmental swelling are usually unnoticed before it reaches adequate size to produce discomfort in oral cavity which leads to dysphagia<sup>12</sup>. Chances of malignancy in parapharyngeal tumours are more when patients presents with pain, neuropathy and evidence of bony erosion in imaging studies; This was described by Prof Myers in their series of 157 patients<sup>13</sup>. Histopathological picture of pleomorphic adenoma shows epithelial and myoepithelial elements with chondromyxoid stroma<sup>14</sup>.

The approach usually depends on the size and location of the mass. In our case we used both transcervical and Transoral approach as we thought removal of the mass Transorally with a vascular control of the neck would be safer.

## Conclusion

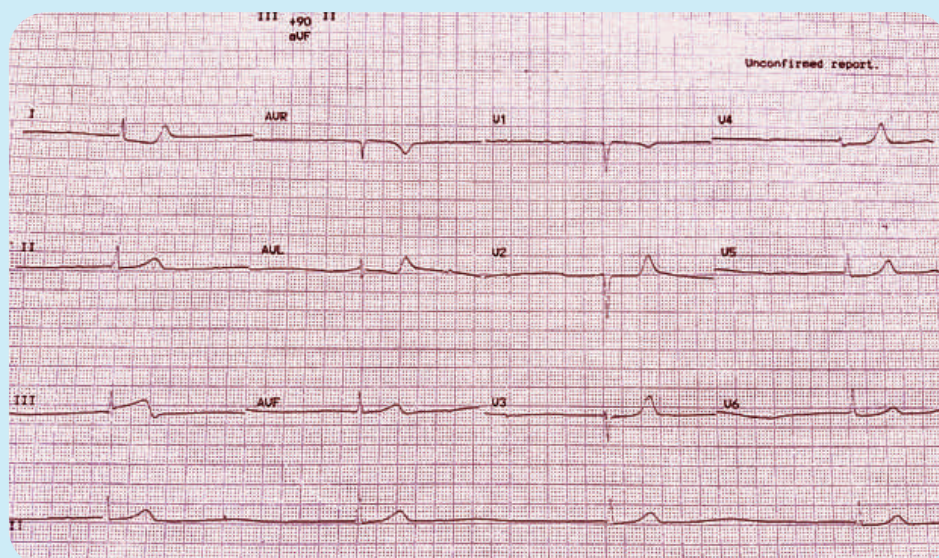
Parapharyngeal mass arising from the pre styloid compartment presenting as a bulge on the lateral wall of the oropharynx can be safely excised by a transoral approach. Considering the essentially blind dissection and possible injury to the internal carotid artery, it is recommended a vascular control of the great vessels of the neck is achieved transcervically prior to excision of mass.

## References

- 1) Khafif A, Segev Y, Kaplan DM, Gil Z, Fliss DM. Surgical management of parapharyngeal space tumours: a 10-year review. *Otolaryngol Head Neck Surg* 2005;132:401-6.
- 2) Attia A, El-Shafiey M, El-Shazly S, Shouman T, Zaky I. Management of parapharyngeal space tumors at the National Cancer Institute, Egypt. *J Egypt Natl Canc Ins* 2004;16:34-42.
- 3) Lombardi D, Nicolai P, Antonelli AR, Maroldi R, Farina D, Shaha AR. Parapharyngeal lymph node metastasis: an unusual presentation of papillary thyroid carcinoma. *Head Neck* 2004;26:190-6.
- 4) Carew JF, Spiro RH, Singh B, Shah JP. Recurrent pleomorphic adenoma of the parotid gland. *Otolaryngol Head Neck Surg* 1999;5:539-42.
- 5) Leonetti JP, Marzo SJ, Petruzzelli GJ, Herr B. Recurrent pleomorphic adenoma of the parotid gland. *Otolaryngol Head Neck Surg* 2005;133: 319-22.
- 6) Spiro RH, Gerold FP, Strong EW. Mandibular "swing" approach for oral and oropharyngeal tumors. *Head Neck Surg* 1981;3:371-8.
- 7) Seward GR. Tumors of the parapharyngeal space. *J R Coll Surg Edinb* 1989;34:111-2.
- 8) Teng MS, Gender EM, Buchbinder D, Urken ML. Subcutaneous mandibulotomy: a new surgical access for large tumors of the parapharyngeal space. *Laryngoscope* 2003;113:1893-7.
- 9) Ahmad F, Waqar-uddin, Khan MY, Khawar A, Bangush W, Aslam J. Management of parapharyngeal space tumours. *J Coll Physicians Surg Pak* 2006;16:7-10.
- 10) Patrick .J. Bradely . General epidemiology and statistics In a defined UK population , in Mcgurk M, Renehan (Ed), *Controversies in the management of salivary gland disease* ,Oxford University Press, Oxford, 2001 Chapter 1, 3-12.
- 11) Maya Ramesh, Ramesh Krishnan, and George Paul. Intraoral Minor Salivary Gland Tumours: A Retrospective Study from a Dental and Maxillofacial Surgery Centre in Salem, Tamil Nadu. *J Maxillofac Oral Surg.* 2014 Jun; 13(2): 104-108.
- 12) Som P M, Biller H F, Lawson W, Sacher M, Lanzieri C F. Parapharyngeal space masses. An updated protocol based upon 104 cases. *Radiology*; 153(1): 1984, 149-156.
- 13) Eugene M Myers. Management of parapharyngeal tumour, editor Chris de Souza , *Head and Neck Surgery*. Vol -2 , chapter 78, Jaypee brothers medical publishers private ltd. 2009; page 1131-1141
- 14) Heeneman H. Parapharyngeal space tumours. In Kerr AG (Ed). *Scott brown s otolaryngology 5th Edition*. Butterworth & co ltd; 1987. 380- 391 .

### Diagnose the condition

55 year old patient with syncope



Dr. M.Chokkalingam, Consultant Cardiology, CSSH.

Answer in page : 190