

Case Report

A Rare Combination of Aggressive Periodontitis with Multiple Impacted Supernumerary Teeth

Dr.M. Shanmugam*, Dr.V.Anitha**, Dr.V.Shivakumar*** Dr.B.Meena Priya****

* Reader, ** Professor, *** Professor & HOD, **** Lecturer, Dept. of Periodontics, Chettinad Dental College and Research Institute, Chennai, India.



Dr.M. Shanmugam M.D.S., is working as Reader in the Department of Periodontology in Chettinad Dental College & Research Institute for last 7 years. He graduated from Vinayaka Mission's Dental College, Salem and did his Masters in Periodontics, Ragas Dental College & Hospital, Chennai. He did MBA - Human Resource Management from Alagappa University. He has published widely in national and international journals. He has participated and delivered guest lectures in over 40 national and international conferences. He actively participates in community health services and research oriented programmes.

Corresponding author - Dr. M. Shanmugam (drshanmids@yahoo.co.in)

Abstract

Aggressive periodontitis (AgP) comprises a group of rare, often severe, rapidly progressive form of periodontitis mostly characterized by an early age of clinical manifestation and a distinctive tendency for cases to aggregate in families. Supernumerary teeth are an important cause of dental retention. Multiple supernumerary teeth without a syndrome is rare. Most of such cases are found in association with syndromes such as Gardner's syndrome, cleidocranial dysostosis and cleft lip and palate. It has been reported that the prevalence for non-syndrome multiple supernumerary teeth is less than 1%. We describe here, a case of a 20 year old patient presenting with multiple impacted supernumerary teeth with aggressive periodontitis, which is a unique presentation in the absence of any syndrome.

Key words : Supernumerary tooth, Impacted tooth; Aggressive Periodontitis.

Chettinad Health City Medical Journal 2013; 2(3): 96-98

Introduction

Aggressive periodontitis (AgP) comprises a group of rare, often severe, rapidly progressive form of periodontitis mostly characterized by an early age of clinical manifestation and a distinctive tendency for cases to aggregate in families. AgP was characterized by: (1) noncontributory medical history; (2) Rapid attachment loss and bone destruction; (3) familial aggregation of cases; (4) lack of consistency between clinically visible bacterial deposits and severity of periodontal breakdown¹. Based on specific clinical and laboratory features, special forms of AgP have been recognized: localized AgP (LAP) and generalized AgP (GAP). A diagnosis of LAP is done based on the evidence of circumpubertal onset and localized first molar/incisor presentation with interproximal attachment loss in at least two permanent teeth, one of which is a first molar and involving no more than two teeth other than first molars and incisors².

Supernumerary tooth is one of the developmental anomalies pertaining to the tooth morphology. A supernumerary tooth is that which is additional to the normal series and can be found in any region of the dental arch³. The occurrence of multiple Supernumerary teeth in a patient, in the absence of an associated systemic condition or syndrome is considered as a rare phenomenon. Wherever "multiple supernumerary teeth" is considered to mean five or more supernumerary teeth, the prevalence has been reported to be less than 1%⁴. Localized aggressive periodontitis has been associated with numerous dental anomalies such as fusion, talons cusp, root fusion, and developmental grooves⁵. Possible association of

AgP with supernumerary teeth has been reported in the literature^{6,7}. The purpose of this paper is to report a case of multiple impacted supernumerary teeth presenting with AgP in the absence of an associated systemic condition or syndrome and highlight the possibilities of a possible biological association.

Case Report

A female patient aged 20 years came to the Department of Periodontics, with the complaint of bleeding gums in the upper and lower arches since 6 months and mild pain in the left back teeth region. Family history and medical history were not significant. Hematological evaluation showed ESR (35mm/hr) and differential white blood cell count showed slight elevation in the percentage of neutrophils (77%). The systemic investigations were not suggestive of any disease or syndrome. Intraoral examination revealed clinical attachment loss of 5 to 6mm in all first molar region and around 6mm in upper incisors and lower anteriors, and generalized gingival inflammation with mild plaque and calculus present without gingival recession. Grade I mobility was seen in 31,32,41 and 42 region⁸. Subsequent radiological examination of the orthopantomogram [Fig.1] revealed multiple impacted supernumerary premolar teeth in relation to 14, 15, 24, 34, 44 and 45 region. The right maxillary and mandibular quadrant consisted of two impacted supernumerary teeth in the first and second premolar region whereas the left maxillary and mandibular quadrant consisted of one impacted supernumerary tooth in the first premolar region and all impacted supernumerary teeth mimicked the permanent teeth. The arc shaped bone loss seen in all

first molars and vertical bone loss in upper incisors was seen, whereas in mandibular anteriors, moderate horizontal bone loss was evident. The patient was educated about her oral condition and explained the treatment plan, which included thorough scaling and root planning (SRP) supplemented with antimicrobial agents. Systemic antibiotics (Doxycycline 100 mg once daily for 14 days after the initial loading dose of 200 mg on first day), were prescribed along with thorough SRP followed by a full mouth flap for access and osteoinductive bone grafting (Osseograft) was done in all first molars and no surgical removal of the multiple supernumerary impacted teeth was planned as it was clinically asymptomatic in nature. Post-operative instructions were given and the patient was advised for recall after 1 week, 2 weeks, 1 month and then every 3 months once.

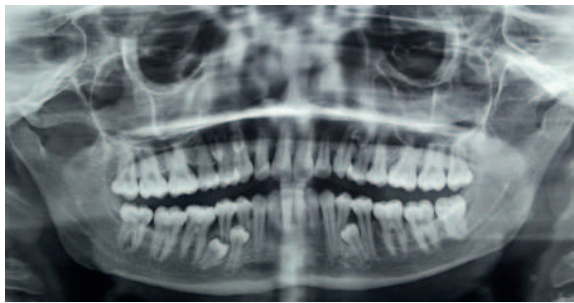


Fig 1. Orthopantomogram view

Discussion

The case described, represents unique characteristic of multiple impacted supernumerary teeth in a single patient with aggressive periodontitis. The supernumerary teeth present in various different forms mimic the permanent teeth. If they are similar to a natural tooth, they are called by the same name; for instance, supernumerary canine, otherwise, when its morphology is abnormal, it is just indicated as a supernumerary tooth located in a certain area. The presence of only one supernumerary tooth occurs in 76-86% of the cases, the presence of two in 12-23% and only 1% of the individuals have three or more supernumerary teeth⁴. Multiple supernumerary teeth can be associated with Gardner's syndrome, Fabry-Anderson syndrome, Ehlers-Danlos syndrome, or cleidocranial dysplasia^{9,10}. Supernumerary teeth may lead to various pathological conditions. These include delayed eruption or non-eruption, displacement of permanent teeth, resorption or malformation of the adjacent roots and cystic formation¹¹. The etiology of hyperdontia still remains unclear. Hattab et al⁴ described hyperdontia as "a multifactorial inheritance disorder which originates from the hyperactivity of the dental lamina", while others suggested that supernumerary teeth were formed due to the dichotomy of the tooth bud¹². Supernumerary teeth are generally thought to occur in the upper jaw ten times more frequently than in the lower jaw¹³. It is essential to enumerate and identify the teeth which are present clinically and/or radiographically, before a definitive diagnosis and proper treatment plan can be formulated, as supernumerary teeth can be an important cause of dental retention¹⁴. Localized aggressive periodontitis is characterized by severe attachment and angular

bone loss, particularly in incisors and molars. Aggressive periodontitis is reported in various study populations - 0.1%, by Odell and Hughes¹⁵; 0.32%, by Lopez et al¹⁶; and 0.76%, by Melvin et al¹⁷. So, both the entities, viz., aggressive periodontitis and supernumerary teeth, are uncommon conditions.

The first study recognizing the possible connection between supernumerary teeth and periodontitis was a case report by Eley in 1974¹⁸. In 1981, Rubin et al. described two identical Black twins with localized juvenile periodontitis, multiple supernumerary teeth and no dental caries. The authors hypothesized that all these three entities were due to genetic influence¹⁹. As Odell and Hughes reported in 1995, both aggressive periodontitis and supernumerary teeth are uncommon but have a familial tendency, and an association may be seen in a small minority of cases. Both entities show familial prevalence, but at the same time, both are consistent with multifactorial and multigenic etiology¹⁵.

But in a retrospective study done by Gokhanet al. (2004), the association between aggressive periodontitis and supernumerary teeth was suggested to be random rather than a biologic one⁷.

To conclude, one may think in terms of the correlation between aggressive periodontitis and multiple impacted supernumerary teeth as in this study. This does not mean that both entities have biological connection. However, association between these two entities is definitely a rare one. To prove such biological connection, further studies and genetic investigations are required to be carried out.

References

- 1) Tonetti MS, Mombelli A. Aggressive periodontitis. In: Clinical Periodontology and Implant dentistry. Lindhe J, Karring T, Lang NP, editors. 4th ed. USA: Blackwell Munksgaard; 2003. p. 216-42.
- 2) Lang N, Bartold PM, Cullinan M, Jeffcoat M, Mombelli A, Murakami S, et al. Ann Periodontol 1999;4:53.
- 3) Garvey MT, Barry HJ, Blake AM. Supernumerary teeth- An overview of classification, diagnosis and Management. J Can Dent Assoc 1999; 65:612-6.
- 4) Rajab LD, Hamdan MAM. Supernumerary teeth: review of the literature and a survey of 152 cases. Int J Pediatr Dent 2002; 12:244-254.
- 5) Hou GL, Lin CC, Tsai CC. Ectopic supernumerary teeth as a predisposing cause in localized periodontitis: Case report. Aust Dent J 1995; 40:226-8.
- 6) Odell EW, Hughes FJ. The possible association between localized juvenile periodontitis and supernumerary teeth. J Periodontol 1995; 66:449-51.

- 7) Açıkgöz G, Açıkgöz A, Keskiner I, Türk T, Otan F. Aggressive Periodontitis With Supernumerary Teeth: A Retrospective Study. *J Periodontol* 2004;75:1458-60.
- 8) Carranza, FA: Clinical Diagnosis. In Newman, MG; Takei, HH; Carranza FA, editors: Carranza's Clinical Periodontology, 9th Edition. Philadelphia: W.B. Saunders Company, 2002. page 439.
- 9) Mason C, Azam N, Holt R, Rule D. A retrospective study of unerupted maxillary incisors associated with supernumerary teeth. *Br J Oral Maxillofac Surg* 2000; 38:62-5.
- 10) McNamara CM, Foley TF, Wright GZ, Sandy JR. The management of premolar supernumeraries in three orthodontic cases. *J Clin Pediatr Dent* 1997; 22:15-8.
- 11) Mark A. Scheiner, Wayne J. Sampson. Supernumerary teeth: A review of the literature and four case reports. *Australian Dental Journal* 1997;42:(3):160-5
- 12) Yildirim D, Yilmaz H and Aydin U. Multiple impacted permanent and deciduous teeth. *Dentomaxillofacial Radiology*. 2004; 33, 133-135.
- 13) Acton CH. Multiple supernumerary teeth and possible implications. *Aust Dent J* 1987; 32: 48-49.
- 14) UmitKaracayli&NuketGocmen-Mas. Multiple Abnormal Unerupted Mandibular Permanent Molar Teeth: A Case Report. *Int. J. Morphol.* 2009; 27(1):65-68.
- 15) Odell EW, Hughes FJ. The possible association between localised juvenile periodontitis and supernumerary teeth. *J Periodontal* 1995;6:449-51.
- 16) Lopez NJ, Rios V, Pareja MA, Fernandez O. Prevalence of juvenile periodontitis in Chile. *J Clin Periodontal* 1991;18:529-33.
- 17) Melvin WL, Sandifer JB, Gray JL. The prevalence and sex ratio of juvenile periodontitis in a young racially mixed population. *J Periodontal* 1991;62:330-4.
- 18) Eley BM. Periodontics occurring with supernumerary molars. *J Dent* 1974;2:167-70.
- 19) Rubin MM, Nevins A, Berg M, Borden B. A comparison of identical twins in relation to three dental anomalies: Multiple supernumerary teeth, juvenile periodontosis, and zero caries incidence. *Oral Surg Oral Med Oral Pathol* 1981;52:391-4.

If it is afternoon, bye-bye ethics!

If you don't like being taken for a ride while making a purchase or a business transaction, remember to do it in the morning. It appears that the people in general are more likely to be honest in the early hours of a day. As the day progresses, even the ones who are morally inclined, are likely to lie and cheat. This is the conclusion of a study conducted by researchers from Harvard University and the University of Utah. In a series of cleverly designed simple experiments involving students and adults, the researchers demonstrated that the tendency to lie and indulge in unethical acts became stronger in the afternoon. The researchers have called this "morning morality effect". Why there is loss of moral sense and self-control as the day progresses is not clear. But this study has important implications for human activities that rely on trust and ethical behaviour. It appears that individuals involved in such transactions need to be supervised carefully during the later part of the day. The results are published in the online version of *Psychological Science*. (<http://pss.sagepub.com/content/early/2013/10/28/0956797613498099.abstract>)

- Dr. K. Ramesh Rao