

# Case Report

## Aesthetic Replacement of Missing Tooth Using Fiber Splint

Dr. Shanmugam.M,\* Dr.V.Shivakumar\*\* Dr.R.Saravana Kumar\*\*\*

Chettinad Health City Medical Journal 2012; 1(1): 31 - 33



Dr.M. Shanmugam M.D.S., is working as a Reader in the Department of Periodontology in Chettinad Dental College & Research Institute for past the 5 years. He graduated from Vinayaka Mission's Dental College, Salem and did his Masters in Periodontics, Ragas Dental College & Hospital, Chennai. He has published widely in national and international journals. He has participated and delivered guest lectures in over 40 national and international conferences. He actively participates in community health services and research oriented programmes.

\*Reader, \*\* HOD & Professor, \*\*\* Professor, Chettinad Dental College & Research Institute, Chennai-603103.

### Abstract

Missing anterior teeth is of serious concern in the social life of a patient in most of the societies. Conventional fixed partial dentures and implant-supported restorations may often be the treatment of choice. Fiber-reinforced composite (FRC) resins offer a conservative, fast, and cost-effective alternative for single and multiple teeth replacement and may prove to be a successful modality for aesthetic and functional replacement of missing teeth along with periodontally compromised abutments, which has always been a challenge for the dentist. The aim of the case report is to describe the clinical procedure in rehabilitation of edentulous space through fabrication of direct fiber-reinforced composite resin fixed partial denture with periodontal splinting of adjacent teeth.

**Key Words:** Missing tooth, Replacement, Fiber – reinforced composite splint, Periodontitis.

### Introduction

Over the last few years there has always been a challenge to the clinician in aesthetic and fixed replacement of missing anterior teeth, for those patients who cannot have either implant or conventional fixed prosthesis. Factors responsible for such may be abutment teeth prognosis, age and financial or time limitations. Initially, the use of steel wires<sup>1</sup> and wire mesh<sup>2</sup>, metal pins, fiber mesh<sup>3</sup> embedded into resins was recommended as more conservative single visit techniques. However these materials had no chemical interactions with composite resins, resulting in clinical failure due to stress concentration when subjected to masticatory forces. To overcome this problem, more resin was used over the reinforcement materials, leading to over contoured restorations which were associated with retention of food and plaque accumulation.

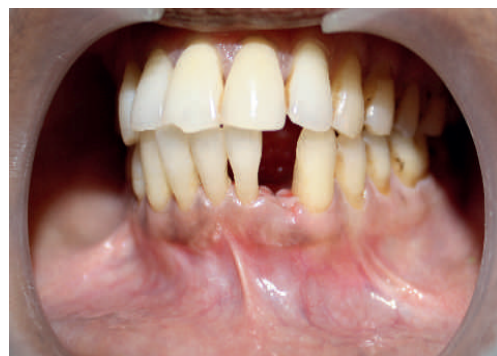The development of adhesive technique and fiber-reinforced composite (FRC) resins materials has thus provided the chair side approaches for stabilizing mobile teeth and replacing missing teeth conservatively and cost effectively.

When replacing missing anterior teeth, thorough treatment planning is essential. Correct choice of materials and bonding techniques are important factors to fulfill the need for durable restoration without compromising aesthetics of FRC-fixed partial denture. The FRC prosthesis fabricated using two approaches, the first approach is based on conventional tooth preparation and laboratory made restoration, second approach is based on using fibers in minimally invasive restoration by direct or indirect fabrication.

The aim of this case report is to illustrate a technique for aesthetic chair side replacement of missing mandibular tooth through the construction of direct polyethylene fiber reinforced composite fixed partial denture and functional rehabilitation of periodontally compromised abutment teeth.

### Case report

A 47 year old lady reported to the department of Periodontics, Chettinad Dental College & Research Institute Chennai, with the chief complaint of unaesthetic appearance and discomfort during function, associated with the mandibular anterior teeth. Patient had lost mandibular left lateral incisor due to advanced periodontal disease (Figure-1). Clinical and radiographic examination revealed that the patient had maximum intercuspal position, moderate bone loss with Grade I tooth mobility in mandibular anterior teeth (according to the Miller index for tooth mobility).




**Fig 1:** Preoperative view of missing left lateral incisor due to advanced periodontitis

The teeth were scaled and root-planed to assure that all calculus and stains were removed.

After phase-I periodontal treatment the use of direct fixed partial prosthesis with polypropylene fiber reinforced composite was proposed as a quick, economical and, non invasive procedure. This procedure is an alternative to the removable partial denture, resin retained prosthesis and conventional fixed partial denture to rehabilitate the prosthetic space and create a periodontal splint for the abutment teeth.

## Procedure

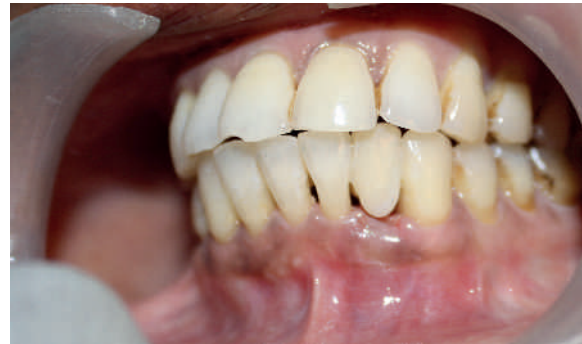The teeth were cleaned on the facial and lingual surfaces using a prophylaxis cup with a nonfluoridated pumice paste. The length of reinforced fiber (Interlig, angelus) (Figure-2) was determined by placing the dental floss on facial side of the mandibular anterior teeth from distal end of left canine to distal end of right canine. After the teeth were thoroughly rinsed and dried, the lingual surface of teeth to be splinted were etched with 37% phosphoric acid (Dentsply) for 30 seconds. The preparations were rinsed with water and dried leaving the etched surface slightly moist.



**Fig 2:** Fiber-reinforced composite mesh (Interlig)

A bonding agent (Dentsply) was applied on all the prepared abutments and fiber mesh. The excess bonding agent was removed, a thin layer of flowable composite was applied to the lingual surface of abutment, and the length of polyethylene fiber mesh was carefully placed on the lingual surface of the abutments just above the cingulum, composite was again applied over the fiber mesh. The restoration were polymerized for 30 seconds with light polymerizing unit at 420mw/cm<sup>2</sup> from lingual and facial surface of abutment and edentulous space.

Composite pontic was prepared on to the facial aspect of already cured fiber band in the edentulous space. Additional composite resin was applied to blend the FRC contours and light polymerized. Incisal adjustments were accomplished and final finishing and polishing done (Figure-3). Routine oral hygiene instructions were given, the patient was evaluated every 6 months for review and periodontal therapy was observed to be effective in obtaining optimal oral health. Periodontally compromised abutment teeth exhibited signs of periodontal health, patient was highly satisfied with aesthetic and functional outcome of the treatment.



**Fig 3:** Post operative facial view of rehabilitation of missing tooth with Periodontal splinting

## Discussion

This clinical report describes the aesthetic replacement of a missing mandibular left lateral incisor and splinting of periodontally compromised teeth adjacent to the prosthetic space with a conservative FRC-FPD resulting in success over a short-term follow up. This treatment option can be categorized as a periodontal prosthesis<sup>4</sup>. Direct technique is conservative, cost effective, eliminates laboratory procedure. The prosthesis can be placed in a single visit using natural teeth, acrylic tooth or composite resin teeth as a pontic. The aesthetics of the FRC-FPD was shown to be considerably better than the aesthetics of FPDs with metal frameworks, as subjectively determined by many observers<sup>5</sup>.

The development of dentin adhesive systems has also led to similar and minimally invasive preparations. But clinical longevity of these prosthesis was found to be poor due to lack of interaction between metals and composite resins, leading to detachment under occlusal forces<sup>6</sup>. In vitro studies have shown that FCR materials exhibit increased strength when compared to particulate resin alone and can withstand occlusal forces in load bearing situations. Vallittu and Sevelius<sup>7</sup> studied clinical success of FRCs and found 93% survival rate after 24 months follow up. In another study Vallittu et al,<sup>8</sup> showed success rate was to increase from 75% to 95% at 42 months.

Metal framework adhesive fixed prostheses in comparison were found to have 61% survival rate in long term follow up to 11 years. Corrente & Hoppner et al<sup>9</sup> studied resin-bonded fixed partial dentures and splints in periodontally compromised patients and the 20 year cumulative survival rate from life table analysis was 76.2% (70.6% for fixed partial denture and 80.7% for splints).

## Conclusion

The development of FRC has expanded the possibilities for conservative tooth replacement and tooth /teeth stabilization. This case report describes the clinical procedure using conservative, aesthetic and cost effective FRC-fixed partial denture which splinte the periodontally compromised teeth. Long term clinical studies will be required in the future to provide additional information on the survival and stabilization

of directly bonded fixed prostheses made with polyethylene fiber reinforced composite resin fixed partial denture.

## References:

- 1) Klassman B, Zucker HW. Combination wire composite intercoronal splinting rationale and technique. *J Periodontol* 1976;47:481-486.
- 2) Schmid MO, Lutz F, Imfeld T. A new reinforced intracoronal composite resin splint. Clinical result after 1 year. *J Periodontol* 1979; 50:441-444.
- 3) Miller TE. A new material for periodontal splinting and orthodontic retention. *Compend Contin Educ Dent* 1993; 14:800-812.
- 4) Miller TE, Hakimzadeh F, Rudo DN. Immediate and indirect woven polyethylene ribbon reinforced periodontal –prosthetic splint: A case report. *Quintessence Int* 1995; 26:267-271.
- 5) Vallittu PK, Sevelius C. Resin bonded, glass fiber reinforced composite fixed partial dentures: A clinical study. *J Prosthet Dent* 2000; 84:413-8.
- 6) Rudo DN, Karbhari VM. Physical behaviors of fiber reinforcement as applied to tooth stabilization. *Dent Clin North Am* 1999; 43:7-35.
- 7) Freilich MA, Meiers JC, Duncan JP. Fiber reinforced composites in clinical dentistry. Chicago: Quintessence; 2000. P. 9-21, 49-63.
- 8) Hoppner et al, Rehabilitation of periodontal compromised teeth with fiber reinforced composite resin- a case report. *Quintessence Int* 2011; 42: 113-120.
- 9) Corrente G, Vergnano L, Re S, et al. Resin-bonded fixed partial dentures and splints in periodontally compromised patients: a 10-year follow-up. *Int J Periodontics Restorative Dent* 2000 Dec; 20(6) :628-36

## FURTHER ATTEMPTS TO RESTORE THE DAMAGED HEART

Following myocardial infarction, the heart fails to regain its original functional capacity even after healing. This is because the cardiac muscle is incapable of regeneration. So, when healing occurs, the dead cardiac muscle fibres are replaced by supportive but non-functional scar. Numerous attempts are being made to restore the normal functionality to the damaged part of the heart. One popular experimental approach has been to use stem cells to replace the fibroblasts in the scar. But so far, no sustained benefit has been achieved with this approach. Another approach appears to be more promising. In a series of studies, Dr. Deepak Srivastava and his associates of Gladstone Institute of Cardiovascular Disease at San Francisco have managed to identify 3 genes (*Gata4*, *Mef2c*, and *Tbx5*) that can transform scar fibroblast into cardiac myocyte. In their latest experimental study in mice, they succeeded in transforming experimentally induced myocardial scar into cardiac muscle in a two-step process. Results of this study appear to hold a great promise for the future management of myocardial infarction. The latest developments were presented at Frontiers in CardioVascular Biology (FCVB) 2012 meeting, held 30 March to 1 April at the South Kensington Campus of Imperial College in London

- Dr. K. Ramesh Rao