

Case Report

An Interesting Case of Hemorrhagic Stroke with Absent Pulses

Ramcharan Reddy*, Vigneshwaran J**, Subramaniyan***, Rajasekaran D****

*Post Graduate student, **Associate Professor, Dept. of General Medicine, ***Associate Professor, Dept. of Neurology, ****Prof. & HOD, Dept. of General Medicine, Chettinad Hospital & Research Institute, Chennai, India.



Dr. Ramcharan Reddy is a Final year MD Post Graduate student in General Medicine, CHRI. His fields of interest include Nephrology and Infectious diseases.

Corresponding author - Ramcharan Reddy (rmcharan@gmail.com)

Abstract

Monckeberg's medial sclerosis is a degenerative disease of unknown etiology, characterised by dystrophic calcification of tunica media of small and medium sized arteries¹. It is a poorly understood condition which can be associated with generalised atherosclerosis, coronary artery disease and chronic kidney disease. We report a case of Hemorrhagic stroke with absent peripheral pulses and extensive arterial calcifications. On extensive evaluation and ruling out various other causes, a diagnosis of Monckeberg's medial sclerosis as the cause was made.

Key Words: Monckeberg's Medial Sclerosis.

Chettinad Health City Medical Journal 2014; 3(4): 195 - 197

Introduction

Monckeberg's Sclerosis was first described by Johann George Monckeberg in 1903^{1,2}. Because of calcification of tunica media, the blood vessel loses its elasticity and its capacity to dilate. The aetiology of this condition is not known. This condition is usually thought of as a benign condition. Here we report a case of Monckeberg's medial sclerosis presenting as hemorrhagic stroke.

Case Presentation

A 44 year old hypertensive male presented to us with acute stroke in the form of right sided hemiplegia. Except for high blood pressure there was no other contributory history.

On examination patient was conscious, oriented and afebrile. Pulse could not be felt in all four limbs while bilateral carotid pulses were very feeble. There was no evidence of limb ischemia. Blood pressure was not recordable by standard sphygmomanometer, and so it was measured by cardiac monitor which showed a blood pressure of 170/110mmhg. Neurological examination revealed a classical right sided hemiplegia with a spasticity of right upper and lower limb, with UMN type of right sided facial nerve palsy. Examination of other systems showed no abnormality.

Investigations

Emergency CT –Brain was taken which revealed hemorrhage in left lentiform nucleus and internal capsule with mild surrounding edema (Fig 1).

All routine biochemical investigations, ECG and chest X ray were within normal limits. To evaluate the absence of peripheral pulses Doppler Ultra Sonogram and X-ray of limbs were performed which revealed an extensive peri – arterial calcification (Fig 2).

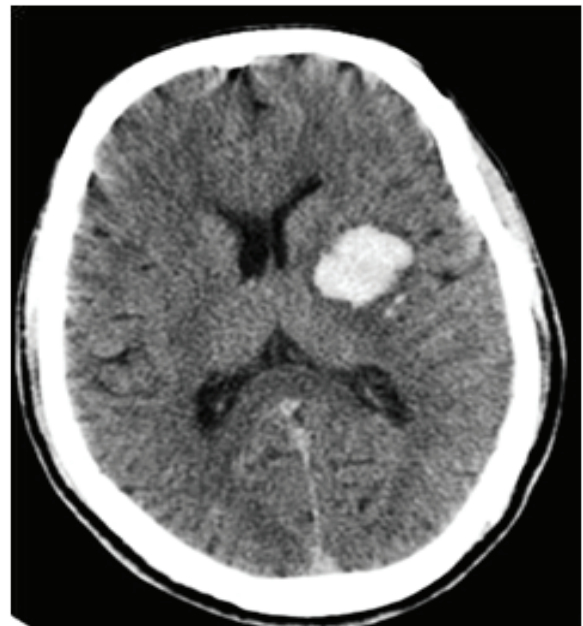


Fig 1 - CT – Brain revealing hemorrhage in left lentiform nucleus and internal capsule

His echocardiogram showed normal LV function (EF – 60%) with no regional wall motion abnormalities, normal cardiac valves & chambers. His renal functions were normal. His Calcium – 9.1 mg/dl (N – 8.5 TO 11), S.Phosphorus – 4.4 mg/dl (N – 2.5 to 4.9) were normal. ANA by immunofluorescence was negative.

Magnetic resonance angiography revealed a contracted right kidney with poor visualisation of right renal artery. Mild arterial wall abnormalities were present in distal abdominal aorta along with poor visualisation of bilateral internal and external iliac bifurcations (Fig-3). Bilateral post tibial arteries were not visualized. Multiple cork screw collaterals were seen in both thighs.

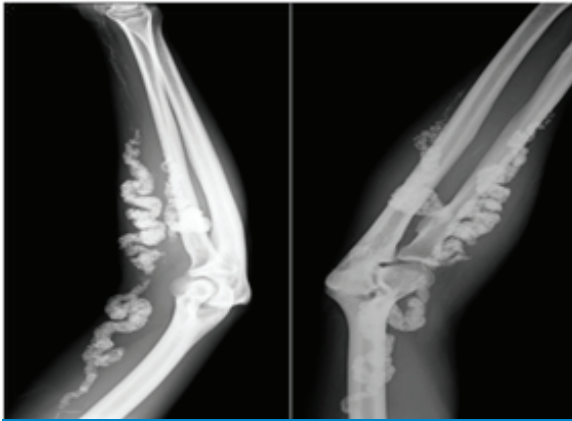


Fig 2 - X-ray limbs showing periarterial calcification

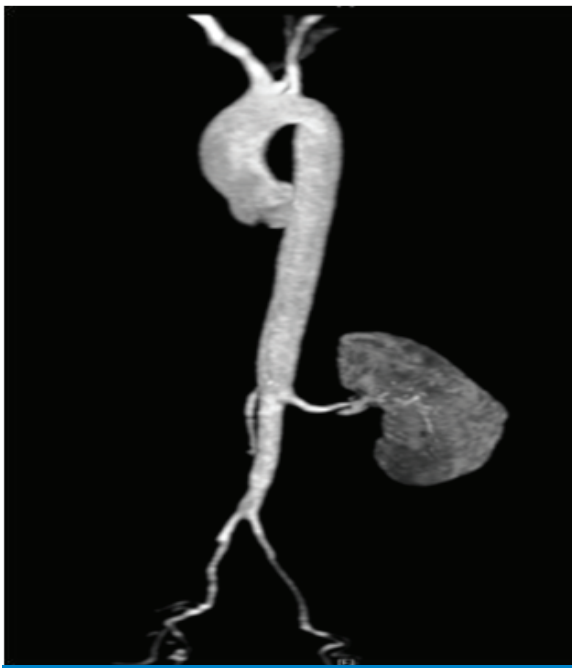

Fig 3 - MR Angiogram - Poor visualisation of bilateral internal & external iliac arteries

Treatment and follow-up

Since the patient did not have diabetes mellitus or chronic kidney disease or abnormal calcium and phosphate metabolism or suggestion for vasculitis, Monckeberg's medial sclerosis was considered as the reason for his arterial calcification. He was treated with antihypertensives and statins. Patient developed no further complications.

Discussion

Monckeberg's medial sclerosis is a degenerative, non-inflammatory disease of unknown etiology which is characterised by dystrophic calcification of tunica media of medium and small sized muscular arteries¹. Intimal layer of artery is spared and lumen is kept open by rigid calcified media, so there is no luminal narrowing³. Morphologically it typically affects arteries less prone for atherosclerosis. Arteries supplying lower extremities are more commonly affected⁴. Notably medial calcification has been reported to occur only rarely in coronary arteries⁵.

Usually it is an incidental finding in otherwise healthy elderly patients⁶. Plain x-ray radiograph may show pipe stem pattern and rail tracking⁷⁻⁹. Lumbar sympathectomy has been shown to promote occurrence of Monckeberg's sclerosis in lower limbs⁸. It's frequently associated with glucose intolerance, chronic kidney disease, old age, male gender and with autonomic neuropathy⁹.

It is postulated that such Monckeberg's medial calcification occurs due to loss of expression of certain proteins involved in inhibition of calcification like G1a protein, fibrillin 1, carbonic anhydrase etc triggered by a necrobiotic injury in vessel wall¹⁰. Other postulated mechanism being vascular smooth muscle cells having osteoblastic properties¹¹.

Immunohistochemistry and in situ hybridization revealed osteoprotegerin immunoreactivity and mRNA expression surrounding calcified areas in the medial layer (Mönckeberg's sclerosis), whereas osteoprotegerin was mainly expressed adjacent to calcified neointimal lesions in atherosclerosis¹².

Though coronary arteries are not commonly involved by this disease, there can be concomitant coronary atherosclerosis. Other investigations for diagnosis are ankle brachial pressure index and MR Angiogram or invasive carotid and peripheral vessel angiogram.

There is no treatment for Monckeberg's sclerosis. Trials with statins have failed to attenuate the rate of progressive vascular calcification. Trials with bisphosphonates are being tried¹². Antihypertensives and statins are given to prevent progression of concomitant atheromatous plaque which may result in prevention of coronary artery disease and chronic kidney disease.

References

- 1) Monckeberg JG. Ueber die reine Mediaverkalkung der Extremitätenarterien und ihr Verhalten zur Arteriosklerose. *Virchows Arch Pathol Anat* 1903;171:141-67
- 2) Silber S, Lippmann HI, Gordon E. Monckeberg's arteriosclerosis. *AMA Arch Intern Med* 1956;97:378-83.
- 3) Christina Dastamani, Evi Kairi, Vassilis Arapoglou, Emmanouela Vouza, Eleni Karvouni, and Agatha Kondi-Pafiti. Unusual presentation of Mönckeberg's sclerosis in the thyroid vessels of three female patients. *Int J Angiol.* 2010 Spring; 19(1): e45-e47. PMID: PMC2949989
- 4) Robert G Micheletti, Gregory A Fishbein, Judith S Currier, Elyse J Singer and Michael C Fishbein. Calcification of the internal elastic lamina of coronary arteries. *Modern Pathology* 2008;21:1019-1028; doi:10.1038/modpathol.2008.89; published online 6 June 2008
- 5) Carlos Eduardo Barra Couri, Geruza Alves da Silva, José Antônio Baddini Martinez, Francisco de Assis Pereira, and Francisco José Albuquerque de

- Paula .Mönckeberg's sclerosis – is the artery the only target of calcification? *BMC Cardiovasc Disord* 2005; 5: 34.
- 6) Lachman AS, Spray TL, Kerwin DM, Shugoll GI, Roberts WC. Medial Calcinosis of Mönckeberg. *Am J Med.* 1977;63:615–22. doi: 10.1016/0002-9343(77)90207-8.
 - 7) Goebel F, Fuessel H. Monckeberg's sclerosis after sympathetic denervation in diabetic and non-diabetic subjects. *Diabetologia* 1983;24347–50
 - 8) Amos RS, Wright V. Monckeberg's Arteriosclerosis and Metabolic Bone Disease. *Lancet.* 1980;2:248–9. doi: 10.1016/S0140-6736(80)90133-6.
 - 9) Silbert S, Lippmann HI. Mönckeberg's arteriosclerosis. *JAMA.* 1955;151:1176–79.
 - 10) Catherine M Shanahan, Nathaniel RB Cary, Jon R Salisbury, Diane Proudfoot, Peter L Weissberg, Mike E Edmonds Medial Localization of Mineralization-Regulating Proteins in Association With Monckeberg's Sclerosis Evidence for Smooth Muscle Cell-Mediated Vascular Calcification. *Circulation.* 1999;100:2168-2176.
 - 11) Naha K, Shetty RK, Vivek G, et al. *BMJ Case Reports* Published online: 4 December 2012 doi:10.1136/bcr-2012007376
 - 12) Ono K, Wada S. Regulation of calcification by bisphosphonates. *Clin Calcium.* 2004;14:60–63.

Vitamin D likes fair skin!

Worldwide, well over a billion people are deficient in vitamin D. As vitamin D directly influences muscle power, force of contraction and bone mass, it plays an important role in athletes' performance. However, until recently, no systematic study had been published regarding the prevalence of its deficiency in athletes. But now, researchers from University of Southern California have carried out a study in which vitamin D levels were measured in division I athletes. To their surprise, they found that nearly one third of those athletes had deficient levels of vitamin D (<32 ng/mL). The risk factors for the deficiency included male sex, Hispanic race, black race and dark skin tone. The deficiency appears to be 2.8 times more common in male athletes than in female athletes. However, after multivariate analysis, only dark skin remained as a significant predictor. The results of the study were presented at 2015 Annual Meeting of American Orthopaedics Association.

- Dr. K. Ramesh Rao