

Case Report

Clinical Role of Beta -Thalassemia Trait in Pathological Conditions: Report of Two Cases

Chidambharam Choccalingam*, Teena Eugene** , Vigneshwaran J***

* Assistant Professor, ** Post graduate, Department of Pathology, *** Associate Professor, Department of General Medicine, Chettinad Academy of Research & Education, Chennai, India.



Dr. C. Chidambharam did his graduation in MBBS from PSG Institute of Medical Sciences and Research, and postgraduation in Pathology from Kasturba Medical College, Manipal University. Further, he did his DNB in Pathology and M.Sc. in Molecular Diagnostics and Genetics from University of Nottingham, United Kingdom. He has worked as consultant pathologist at SRL Limited, Chennai. He is currently working as Assistant Professor in Pathology at Chettinad Hospital & Research Institute. His areas of interest include Oncopathology and Molecular Diagnostics.

Corresponding author - Dr. Teena Eugene - (teena.eugene19@gmail.com)

Chettinad Health City Medical Journal 2016; 5(4): 202 - 203

Abstract

Beta -Thalassemia (β -Thalassemia) trait is a heterozygous state for abnormal β gene and is clinically asymptomatic. Co-inheritance of β -Thalassemia trait with other abnormal globin gene or any other mutation may alter the course of disease in the subject. Here we report 2 cases, one with the co-inheritance of β -Thalassemia trait with haemoglobin S & the other with co-existence of iron deficiency anaemia and β -Thalassemia. In case 1, Thalassemia trait has ameliorated the clinical course of sickle cell disease & in case 2, β -Thalassemia trait has further aggravated the symptoms caused due to Iron deficiency anaemia. These two cases emphasize the need to search for additional clues if there is no complete correlation between diagnostic investigation results and clinical condition of patient.

Key Words: Beta -Thalassemia, Anemia, Iron deficiency, Sickle cell anemia, Hemoglobin electrophoresis

Introduction

Beta -Thalassaemias (β -Thalassemia) are a group of genetic disorders common in the Indian sub-continent and is characterized by reduced rate of synthesis of beta (β) globin chain of the haemoglobin. Though a variety of mutations in β globin gene are responsible for β -Thalassaemia, the β gene mutations are broadly categorized as beta zero (β^0) if there is no expression of the abnormal β gene and beta plus (β^+) if there is reduced expression of the abnormal β gene. As normal individuals have two allelic β globin gene, β -Thalassaemias can exist in homozygous state, heterozygous state, or compound heterozygous state with either any other β gene mutation or any other relevant mutation'. β -Thalassemia trait is a heterozygous state for abnormal β gene and the subject is clinically asymptomatic. However at times of haematopoietic stress, the subject may become anaemic. Co-inheritance of β -Thalassemia trait with other abnormal globin gene or any other mutation may alter the course of disease in the subject². Here we report 2 cases, one with the co-inheritance of β -Thalassemia trait with haemoglobin S and the other with co-existence of iron deficiency anaemia and β -Thalassemia trait, to highlight the clinical significance of β -Thalassemia trait in different pathological conditions.

Case Report 1

A 24 year old man from Chennai, Tamilnadu presented with abdominal fullness of 3 days duration. He did not have any other constitutional symptoms. On

examination he was conscious, oriented, and mildly icteric with mild pallor. His abdominal examination revealed mild splenomegaly. His complete blood count showed a haemoglobin (Hb) - 8.2g/dl; RBC count-3.01million/cu.mm; Mean corpuscular volume (MCV)-86.8fl; Red cell distribution width (RDW) - 15.4; normal leucocyte and platelet count. Peripheral smear showed microcytic hypochromic RBCs, elliptocytes, tear drop cells, target cells and occasional sickle cells (Figure 1A). Corrected reticulocyte count was 4.5%. His liver function test showed elevated total bilirubin (4.2mg/dl) and indirect bilirubin(3.9mg/dl). Sickling test was positive (Figure 1B). High pressure liquid chromatography(HPLC) done for this patient revealed: Hb S-74.9%; Hb A α -5%; Hb A β -4.3%; Hb F-12.6% (Figure 2A). Based on the HPLC findings a possible diagnosis of Sickle cell/ β Thalessemia+ was made.

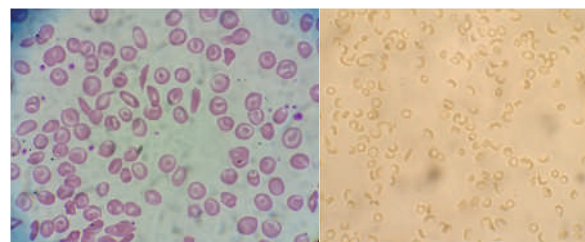


Figure 1: (A) High power magnification showing sickle cells, microcytic RBCs and target cells (Leishman stained peripheral smear) (B) Sickle cells seen in sickling test

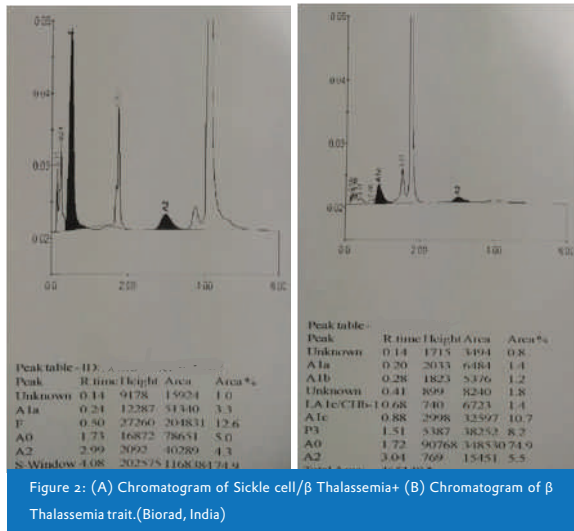


Figure 2: (A) Chromatogram of Sick cell/β Thalassemia+ (B) Chromatogram of β Thalassemia trait.(Biorad, India)

Case Report 2

A 66 year old female presented with long standing ulcerative lesion in the shin of right leg. On general examination, she had severe pallor. Her complete blood count showed a haemoglobin-2.9g/dl; RBC-2.01million/cu.mm;MCV-49.7fl; RDW-22.7; elevated leucocyte count and normal platelet count. Peripheral smear showed microcytic hypochromic RBCs, elliptocytes, target cells and occasional nucleated RBCs. Corrected reticulocyte count was 2.0%. Her liver function test was normal and serum iron profile showed iron-16μg/dl; total iron binding capacity-163μg/dl; ferritin-26.4ng/ml. HPLC revealed Hb A0-74.9%; Hb A2-5.5% (Figure 2B). Based on the serum iron and HPLC findings, a possible haematological diagnosis of co-existing iron deficiency erythropoiesis and β-Thalassemia trait was made. Blood transfusion was given and biopsy of the lesion was taken for histopathological diagnosis.

Although confirmation of diagnosis by molecular methods was suggested, due to financial constraints it was not done.

Discussion

In case 1, Hb S was more than 50% of total haemoglobin, along with mildly elevated Hb A2 and minimal Hb A0, which hints at a possible Sick cell/β Thalassemia². This patient had the first episode of hemolysis and crisis, with no history of crisis in the past. This amelioration of the natural course of sickle cell disease is because of the relatively smaller percentage of Hb S, presence of small amounts of Hb A, and higher percentage of Hb F, Hb A2 present in the abnormal haemoglobin^{2,3}.

In case 2, elevated Hb A2 in spite of iron deficiency erythropoiesis makes the diagnosis of β Thalassemia trait straightforward. Although Hb A2 levels have been reported to be lower in patients with co-existing iron deficiency and β Thalassemia trait leading to erroneous identification of β Thalassemia trait, our patient had an elevated Hb A2 which was instrumental in diagnosing β Thalassemia trait. However our patient, though had low serum iron, his total iron binding capacity and

serum ferritin was within normal range. The not so typical serum iron profile, would probably be the reason for elevated Hb A2. Our patient had a much lower haemoglobin and severe microcytosis compared to normal iron deficiency anaemia. The lack of haematopoietic nutrients in addition to abnormal globin chain synthesis results in further reduction of haemoglobin³. This reduced haemoglobin may cause severe anaemic symptoms^{2,4}.

In case 1, β Thalassemia trait has ameliorated the clinical course of sickle cell disease and in case 2, β Thalassemia trait has further aggravated the symptoms caused due to iron deficiency anaemia. These two cases explain the need to search for additional clues if there is no complete correlation between diagnostic investigation results and clinical condition of patient.

References

- 1) Muncie HL Jr, Campbell J. Alpha and beta thalassemia. *Am Family Physician*. 2009;80(4):339-344
- 2) Bain, Barbara. 2nd ed Haemoglobinopathy Diagnosis. Blackwell publishing Ltd.2006.
- 3) Niwas J, Reddy R, Udayashankar D, Durga K, Rajasekaran D. Sick cell Beta+ Thalassemia. *Chettinad Health City Medical Journal*.2014;3(3):133-135
- 4) Verma S, Gupta R, Kudesia M, Mathur A, Krishan G, Singh S. Coexisting Iron Deficiency and Beta Thalassemia Trait: Effect of Iron Therapy on Red cell parameters and Hemoglobin subtypes. *ISRN Hematology*. 2014:293216.