

Case Report

Microsurgical Aneurysm Clipping - Our Experience

Karthikeyan K V

Consultant Neurosurgeon, Chettinad Super Speciality Hospital, Chennai, India



Dr.K.V.Karthikeyan is currently working as Consultant Neurosurgeon at Chettinad Super Speciality Hospital since 2010. He completed his graduation in 2001 from the prestigious Madras Medical college and completed his MCH (Neurosurgery -5 yrs) from the Madras Institute of Neurology at Madras Medical college in 2007. He is very well trained in Micro neurosurgery and vascular neurosurgery. He has special interest in Vascular Neurosurgery and Endoscopic Neurosurgery.

Corresponding author - Dr. K.V.Karthikeyan (surgenn@gmail.com)

Abstract

Microsurgical clipping of aneurysms is a challenging procedure for any neurosurgeon. It requires in depth knowledge of microanatomy, microsurgical skills, experienced neuro anaesthetists and dedicated specialised postoperative care. We present our experience in aneurysmal clipping.

Key Words: Aneurysm, SAH, Giant, Clipping

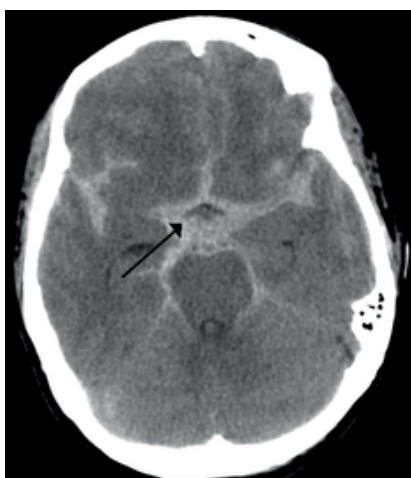Chettinad Health City Medical Journal 2014; 3(2): 74 - 76

Case Report

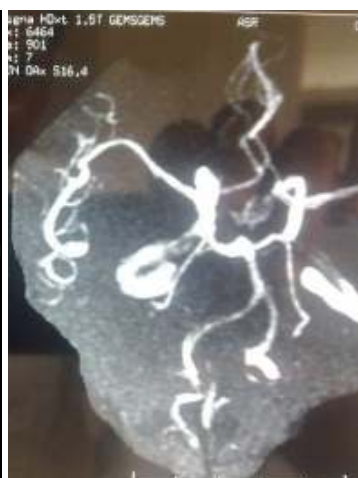We have limited experience in aneurysmal clipping since 2012 in our institute. During this period we successfully clipped 5 aneurysms in various locations and with different World Federation of Neurologists Societies(WFNS) grades.

Case 1: A 53 year old known non hypertensive lady presented with sudden onset headache followed by seizure and altered sensorium. On admission her GCS was 7/15 with and right hemiplegia. (WFNS Grade 5). CT Brain showed diffuse SAH in all basal cisterns with mild hydrocephalus(Hunt-Hess Grade IV) (Fig 1). MRI with MR Angio and CT Angio showed large saccular aneurysm in the left Internal Carotid Artery (ICA)

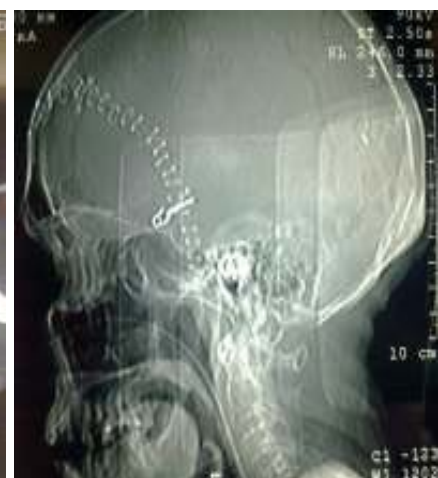bifurcation measuring 29mm with neck width of 7 mm (Fig 2). Patient underwent left pterional craniotomy and sphenoid wing was drilled to make it accessible with meticulous arachnoidal dissection and clearing the subarachnoidal clots, a giant saccular thin walled aneurysm at the Left ICA was identified. Neck was dissected all around and a 11 mm slightly curved clip was applied at the neck. During application the thin neck ruptured and second clip of 11mm straight was applied below the first one and augmented with muscle patch. The bleeding stopped. Postoperative patient had dense right hemiplegia and aphasia. Patient slowly improved over a period of 6 weeks with neuro rehabilitation. At the time of discharge patient was aphasic and walking with minimal support. At 3 months follow up patient's aphasia improved and was walking without support and doing her daily activities independently (Fig 3).



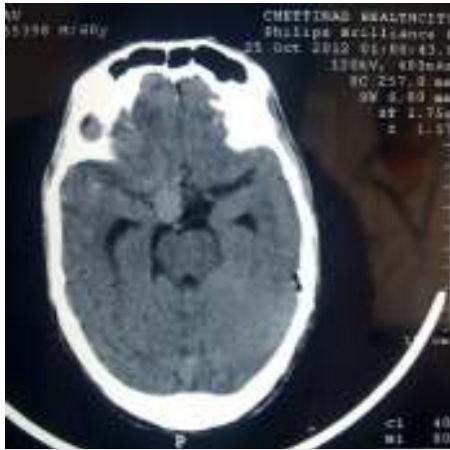Case 1 - Image 1
Preoperative CT brain showing diffuse SAH



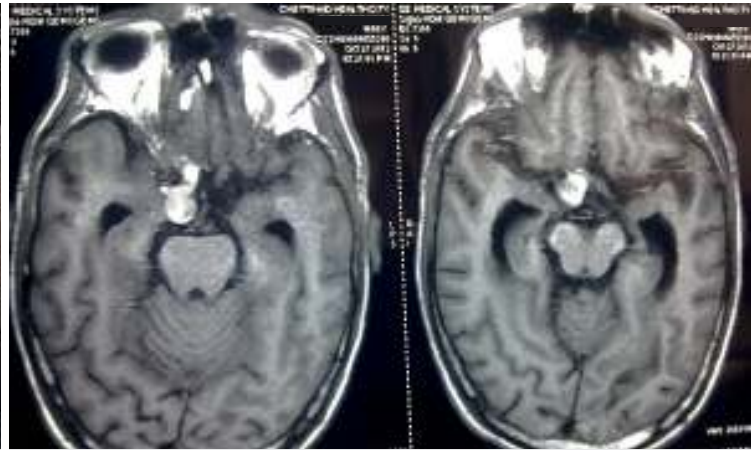
Case 1 - Image 2
Preoperative MRA showing left ICA bifurcation saccular



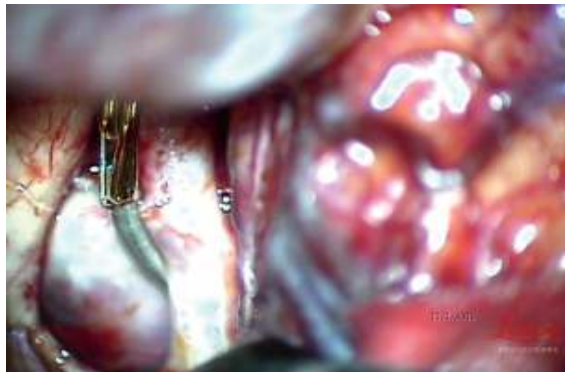
Case 1 - Image 3
Postoperative Xray showing clip in position aneurysm



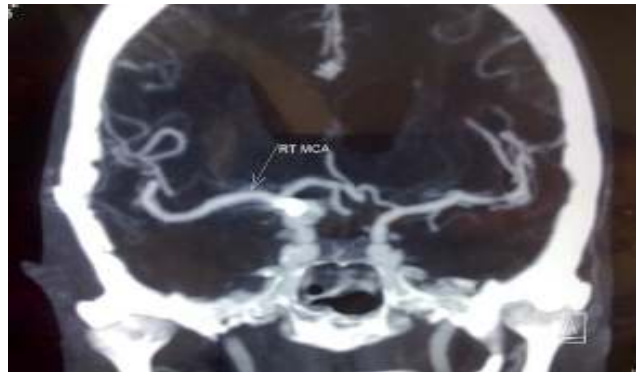
Case 2 - Image 1
Preoperative CT showing thrombosed
Right ICA bifurcation Aneurysm



Case 2 - Image 1
Preoperative MRI showing thrombosed aneurysm at Right ICA
bifurcation



Case 2 - Image 3
Intra operative image showing clipped aneurysm



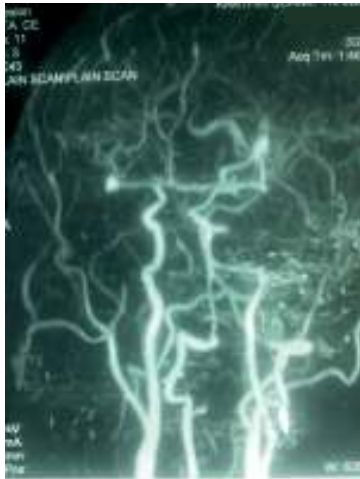Case 2 - Image 4
Post operative CT angio after 6 months showing clipped
aneurysm

Case 2: A 60 year old hypertensive patient presented with five days of headache and altered sensorium. On examination his GCS was 13/15 with minimal left hemiparesis. (WFNS grade 3). CT brain showed no SAH but there was a well circumscribed blobular lesion in right ICA bifurcation not enhancing with contrast, probably a thrombosed aneurysm noted (Fig 1). MR Angio also confirmed that the size is around 24mm with a neck width of 5mm (Fig 2). Patient underwent right pterional craniotomy and with meticulous microscopic arachnoidal dissection there was a large thrombosed hard aneurysmal sac at the right ICA bifurcation with relatively small neck. Neck was dissected all around and clipped with 8mm straight clip (Fig 3). Post operative period was uneventful and patient improved well and 6 weeks post operative CT angio showed satisfactory clipping and occlusion of the neck (Fig 4).

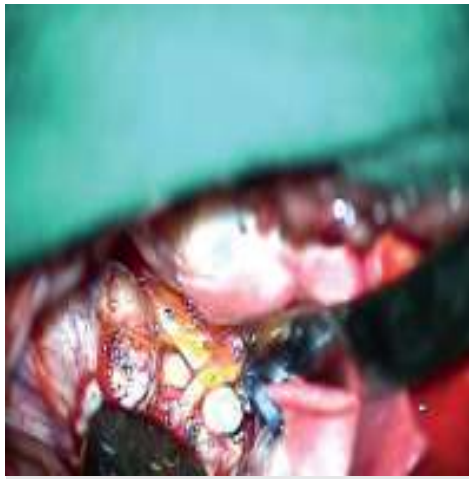Case 3: A 35 year old gentleman presented with one month old severe headache, vomiting for couple of days and he took symptomatic treatment. Then he was evaluated later and referred to us with CT angiogram which showed Right MCA bifurcation 5 mm aneurysm which was thrombosed (WFNS Grade 1) (Fig 5). Patient underwent right pterional craniotomy and clipping with 7mm straight clip (Fig 2). Post operative period was uneventful and follow up angiogram showed perfect occlusion (Fig 3).

Case 4: A 40 year old lady non hypertensive presented with sudden headache, seizure and unconsciousness, on examination her GCS was 10/15. CT brain showed diffuse SAH in suprasellar cistern and interhemispheric fissure and a small ICH in right frontal lobe with diffuse edema. (WFNS Grade 4) (Fig 1). MR angiogram showed ACOM (Anterior Communicating) aneurysm with the neck on left side and the fundus towards right frontal lobe (Fig 2). Patient underwent left pterional craniotomy and with meticulous arachnoidal dissection all the perforators around the neck were excluded and both A1 and A2 on both sides excluded and a 5mm straight clip was applied (Fig 3). Post operatively her recovery was slow and post op CT showed left side ACA partial infarct. After two weeks patient recovered well and on discharge patient GCS was 15 with no motor deficit but she had minimal behavioral disturbance. 3 months follow up CT angio showed clipping in situ (Fig 4).

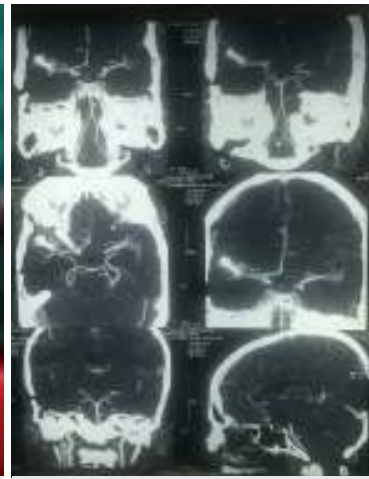Case 5: 48 year old hypertensive man referred to us as a case of ACOM (Anterior communicating artery) aneurysm (WFNS Grade 1). He had history of frequent headaches only. Neurologically his GCS was 15 and no deficit. CT angio showed a narrow necked ACOM aneurysm of 9 mm in size (Fig 1 & 2). He underwent conventional right pterional craniotomy and clipping. Post operative period was uneventful (Fig 3).



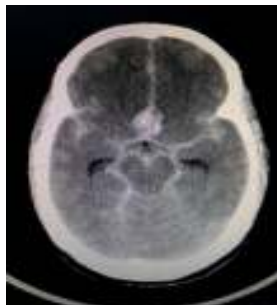
Case 3 - Image 1
Pre operative Angio showing Rt MCA bifurcation Aneurysm



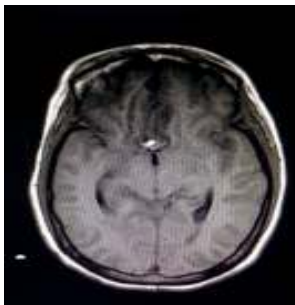
Case 3 - Image 2
Intra operative image showing clipped aneurysm



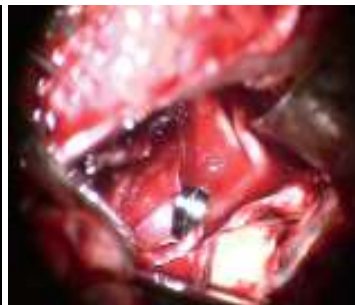Case 3 - Image 3
Postop CT angio showing clipped aneurysm



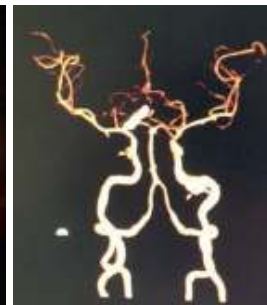
Case 4 - Image 1
CT Brain showing diffuse SAH with IVH and ICH



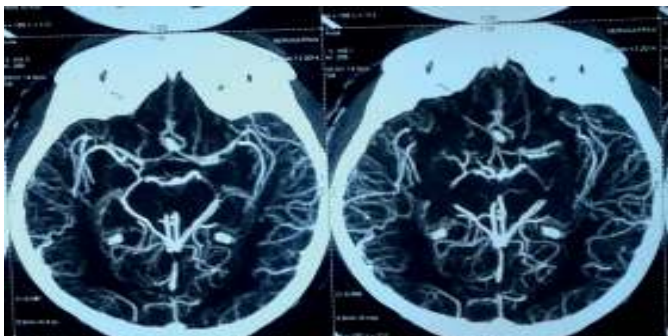
Case 4 - Image 2
Preoperative MR angio showing Narrow necked aneurysm at ACOM and CH



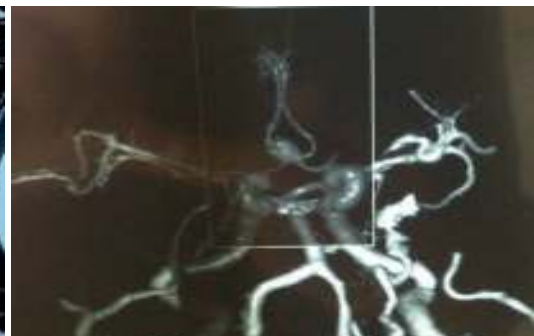
Case 4 - Image 3
Intra operative image showing clip in situ



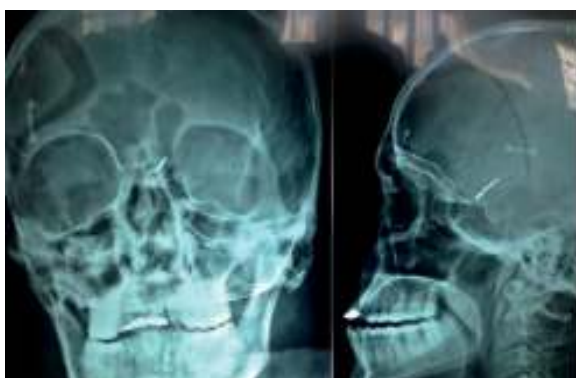Case 4 - Image 4
Post operative CT angio 3D reconstruction showing clip in situ



Case 5 - Image 1
CT angiogram showing narrow necked ACOM aneurysm



Case 5 - Image 2
3D reconstruction shows the Aneurysm



Case 5 - Image 3
Immediate post operative X ray showing clip in situ

Conclusion

With our limited experience we achieved a 100 percent success after clipping with no mortality and minimal morbidity. Though conventional 4 vessel angio is the gold standard test, due to limited availability in our institute CT angio served as an alternative tool in diagnosing. Effective post operative care is essential in ruptured aneurysm to overcome the complications of subarachnoid haemorrhage.