

# Case Report

## Aniridia with Sydney Crease

Dr Srinivasan K\*, Dr Thayumanavan\*\*, Dr Padmapriya\*\*\*

\*Prof of Paediatrics and Consultant Neonatologist Chettinad Super Specialty Hospital, \*\* Prof of Paediatrics and Head of the Dept. of Paediatrics, \*\*\* Compulsory Resident Rotatory Intern Chettinad Hospital & Research institute, Chennai, India.



Professor Dr Srinivasan Kitchanan M.D, D.C.H, PGD (NEO) is Consultant Neonatology at Chettinad Health City. He has done his Fellowship in Neonatology from Australia. He headed the Neonatology unit Madras Medical College, at Institute of Child Health, Egmore. He has a special interest in the field of pre-term intensive care and nutrition.

Corresponding author - Dr. Srinivasan. K (sri\_10@yahoo.com)

Chettinad Health City Medical Journal 2014; 2(1): 14 - 16

### Abstract

Aniridia is abnormal hypoplastic iris reduced to rim of tissues and appears as though there is total absence of iris. It is usually bilateral and is a rare condition bound to be missed during neonatal period due to normal blepharospasm of newborns. Such detection requires protocol guided routine systematic examination aided by a check list. Early detection helps in screening for associated ophthalmic conditions, counseling parents for further investigations, management and to avoid medico legal conflicts. In this case report, bilateral aniridia a rare anomaly is associated with Sydney crease another recognized dysmorphology.

**Keywords:** Aniridia, Neonatal examination, Sydney crease, Nuclear cataract.

### Introduction

The following case has been reported as there are no reports of association of aniridia with Sydney crease and highlights the importance of routine systematic examination based on checklist for newborns in eliciting clinical findings. Missing such a rare condition can have long term diagnostic and prognostic implications. Eye examination in a new born is routinely done but difficulty in opening their eyes results in avoiding further detailed examination. In this case, rare finding Sydney Crease is associated with another rare condition Aniridia.

### Case History

A female child, Infant of Gestational Diabetes Mother (IGDM) born to non consanguineous parents delivered by emergency caesarian section to a mother on Insulin, was transferred to nursery for glucose monitoring. Baby's cry, color and activity were good and on enteral feeds. On day 2 of life a routine examination revealed large pupil which lead to further careful examination and diagnostic finding of bilateral Aniridia with minimal iris in the periphery. Further examination revealed the presence of hairy forehead and Sydney's line in the baby's both palms. Other system examination revealed no clinically detectable anomalies. TORCH screening, Ultrasound examination of cranium and abdomen did not reveal any abnormality. Further eye examination by ophthalmologist did not show any other abnormalities and intraocular pressures were normal. Parents were counseled for regular review at child development clinic and for renal ultra-sonography every 3-6 months till 5 years of age and less frequently till 16 years or till genetic test confirms non involvement of extragene<sup>1</sup>. She was also advised routine screening for detection of

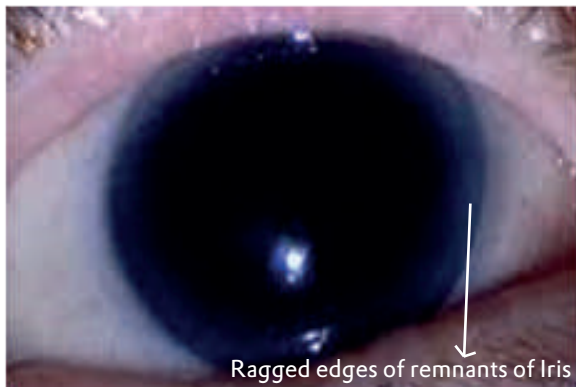
developing corneal opacity, cataract and glaucoma and avoidance of direct bright lights. Infant on ophthalmic follow up was found developing nuclear cataract at nine months of age.

### Discussion

Aniridia is a misnomer because iris tissue is usually present although it is hypoplastic (Fig.1). The condition is bilateral in 98% of all patients regardless of the means of transmission and is found in approximately 1 in 50,000 persons<sup>2</sup>. Aniridia represents a defect of neural crest cell development. In addition to striking absence of iris tissue the other ocular abnormalities frequently seen are nystagmus, fibrovascular corneal pannus, refractive errors, glaucoma, cataract, foveal hypoplasia and optic nerve hypoplasia. In a study of Korean patients, Cataract (82.5%), glaucoma (51.6%), keratopathy (71.6%), and foveal hypoplasia (81.8%) commonly accompanied aniridia. Thirty-four (60.7%) eyes had Visual Acuity less than 20/200 and 20 eyes (35.7%) had Visual Acuity between 20/200 and 20/60<sup>3</sup>. Relative frequencies of the age of patients with aniridia at time of glaucoma diagnosis are as following<sup>4</sup>: from birth to 9 years, 10-19, 20-29, 30-39 were 15%. In the fifth decade i.e. 40-49: 35%, and in 50-59: 5%. Aniridia is an autosomal dominant condition caused by mutation in the PAX6 homeobox gene 11p13 and usually (66%) has no systemic manifestation and classified as Aniridia I<sup>1</sup>. About 30% cases are sporadic, with deletion at 11p13 and classified as Aniridia II. This type has high incidence of associated abnormalities including Wilm's tumour when contiguous oncogene WT1 gene deletion occurs<sup>5</sup> which is known as WAGR syndrome<sup>6</sup>, genitourinary abnormalities and mental handicap. Another form of Aniridia classified as Aniridia III is autosomal recessive with mental

retardation, Cerebellar ataxia. In the molecular diagnosis of aniridia, ocular malformation may be regarded as a group of heterogeneous disorders, rather than a single disease entity, associated with mutations in PAX6 a gene responsible for eye development and/or other genes located elsewhere in the human genome as suggested by the fact that there is variability of the phenotype in the presence or absence of PAX6 mutations<sup>7</sup>. Abdominal palpation and/or abdominal ultrasound study should be performed in all new cases and as a part of our follow.

Sydney crease which is proximal transverse crease extending to the ulnar border of the palm in association with Aniridia has not been reported (Fig.2). Prevalence of Sydney creases is 0.19% in a study of South Nigerian population<sup>8</sup>. There is general pattern of increase in prevalence rate in Caucasian when compared to the Orientals<sup>8</sup>. Ravindranath et al., reported 3.8% a high occurrence of Sydney crease in their normal control in central India<sup>9</sup> with female preponderance. Dar et al.,<sup>10</sup> reported that dermatoglyphic polymorphism results from the co-operation of genetic, ethno-historic and environmental factors and reported that Sydney crease was significantly present in at risk neonates<sup>10</sup>, female congenital rubella<sup>11</sup> Leukemia<sup>12,13,14</sup> Trisomy21.<sup>15</sup> The finding was also significantly present in developmental delay and in hyperactive children<sup>16</sup>.



**Fig 1: Illustration of Aniridia in newborn**



**Fig 2: Illustration of Sydney Crease - Two transverse creases extending to ulnar border**

There are also reports of Sydney crease in Williams Beuren Syndrome, Fragile X-syndromes, Marfans, Rubeinstein Taybi Syndrome, and Achondroplasia In a follow up study the Sydney crease disappeared in 58.8% of infants by 10 months of age<sup>17</sup>.

Studies do not explain the lack of homogeneity and in this neonate aniridia and Sydney crease were randomly present and needs further genetic studies. This case report highlights the significance of routine check list based neonatal examination and of follow-up.

## References

- 1) Jack J Kanski: Clinical Ophthalmology; 6th edition 2007: pg 75
- 2) Tremblay F, Gupta SK, De Becker I, et al. Effects of PAX6 mutations on retinal function: an electroretinographic study. *Am J Ophthalmol.* 1998;126:211-218.
- 3) Shin Hae Park, Young Gun Park, Mee Yon Lee, and Man Soo Kim Clinical Features of Korean Patients with Congenital Aniridia *Korean J Ophthalmol.* 2010 October; 24(5): 291-296.
- 4) Gramer E, Reiter C, Gramer G. Glaucoma and frequency of ocular and general diseases in 30 patients with aniridia: a clinical study. *Eur J Ophthalmol.* 2012 Jan-Feb; 22(1):104-10.
- 5) Forfar and Arneil's textbook of pediatrics, Elsevier; 7th edition. pg 390
- 6) Kleigman Nelson textbook of pediatrics, Saunders. 17th edition, pg 1712.
- 7) Lim HT, Seo EJ, Kim GH, Ahn H, Lee HJ, Shin KH, Lee JK, Yoo HW. Comparison between aniridia with and without PAX6 mutations: clinical and molecular analysis in 14 Korean patients with aniridia. *Ophthalmology.* 2012 Jun; 119(6):1258-64.
- 8) CA Oyinbo MSc; HB Fawehinmi MD Ph.D; Prevalence of simian and Sydney creases in the Ijaws of South- South Nigeria; *The Internet Journal of Biological Anthropology* ISSN: 1939-4594
- 9) D. K. Sharma & Vandana Sharma Prevalences of Simian, Sydney and Suwon Creases and their Association with Each Other, Body Sides, Handedness, Sex and Anomalies, Diseases, Syndromes in a Population of Central India. *Int. J. Morphol.*, 2011, 29(3):1069-1075.
- 10) Dar H, Schmidt R, Nitowsky HM. Palmar crease variants and their clinical significance: a study of newborns at risk. *Pediatr Res* 1977; 11:103-8.
- 11) S.G. Purvis-Smith B.Sc. New England , MargaretA. Menser M.B. Sydney, M.R.A.C.P. *Dermatoglyphics In Adults With Congenital*

- Rubella, *The Lancet*. 1968; 292 (7560) : 141 - 143.
- 12) Oorthuys AM, de Vaan GA, Behrendt H, Geerts SJ.; Palmar flexion creases in childhood neoplasia; *Cancer*. 1979 Feb; 43(2):749-59.
  - 13) Menser MA, Purvis-Smith SG. Dermatoglyphic defects in children with leukaemia. *Lancet*. 1969 May 31;1(7605):1076-8.
  - 14) Menser MA, Purvis-Smith SG. Dermatoglyphics in leukaemia. *Lancet*. 1972 Apr 29;1(7757):956-7.
  - 15) Rajangam S, Janakiram S, Thomas IM. Dermatoglyphics in Down's syndrome. *J Indian Med Assoc*. 1995 Jan;93(1):10-3.
  - 16) Johnson CF, Opitz E.; The single palmar crease and its clinical significance in a child development clinic.; *Clin Pediatr (Phila)*. 1971 Jul;10(7):392-403.
  - 17) Berger, A., Dar, H., Borochoowitz, Z. and Winter, S. T. Changes In The Sydney Line During The First Year Of Life. *Developmental Medicine & Child Neurology*, 1983; 25: 490-492.

### Answer to : **Diagnose the condition**

ECG was showing diffuse Concave upward ST elevation in limb and chest leads. There were no reciprocal ST changes. No Q waves in any of the leads. Acute MI is the most common diagnosis; but absence of Q waves with diffuse ST elevation without any localization and absence of reciprocal ST depression goes against the diagnosis; patient was diagnosed as having acute pericarditis with clinical history, normal cardiac enzymes and echocardiography. High index of suspicion is required in such cases; or thrombolysis or even anticoagulation in such cases can lead to fatal pericardial bleeding and tamponade.

- Dr. N. Ganesh, Consultant Cardiologist,  
Chettinad Supert Speciality Hospital.

### **You can't keep a good guy down**

Marihuana (cannabis) is like a good friend with a bad reputation. For most of human history (going back to 7000 BCE), its use has been legal. Even now it has remained the fourth most popular recreational drug (only behind alcohol, caffeine and tobacco). But in 1937, USA decided to make its use illegal for non-medical reasons (even AMA did not fully agree with the decision). But it is bouncing back. A spate of recent studies have re-established its beneficial effects. Even the Food and Drug Administration (FDA) acknowledges that "there has been considerable interest in its use for the treatment of a number of conditions, including glaucoma, AIDS wasting, neuropathic pain, treatment of spasticity associated with multiple sclerosis, and chemotherapy-induced nausea." Now in the latest study published in *American Journal of Medicine* (May 2013, Vol. 126, No. 5doi:10.1016), Murray A. Mittleman and his colleagues, have claimed potential benefits in patients with obesity and diabetes mellitus. In a study involving 579 current marihuana users and 1975 past users, the authors found that current marijuana use was associated with 16% lower fasting insulin levels (95% confidence interval [CI]), 17% lower HOMA-IR (homeostasis model assessment of insulin resistance; 95% CI) and significant associations between marijuana use and smaller waist circumferences. Getting treated for obesity or diabetes may become a recreation.

### **Subcellular stress is the key to obesity**

Obesity is a major health problem in many parts of the world. Fat, unlike money, is difficult to lose when once it accumulates. Until now, intractable obesity is considered to be due to the development of progressive insensitivity to fat sensing hormone, leptin. But Eduardo A. Nillni, professor of medicine at Brown University, in an earlier study, had also observed low levels of  $\alpha$ MSH (alpha-Melanocyte-stimulating hormone) in obese rats, particularly after heavy meal. Alpha-MSH has two functions in hypothalamus region of the brain: one is to suppress hunger; the other is to facilitate the production of hormone TRH, which promotes the thyroid mediated calorie burning in the body. Now, in a new study published in *Journal of Biological Chemistry*, Nillni and his colleagues decided to examine the cause for low levels  $\alpha$ MSH in rats with diet induced obesity. They found that in obese rats, the endoplasmic reticulum (ER) is stressed and fails to properly assemble the enzyme proprotein convertase 2 (PC2), which is required for the synthesis of POMC, a precursor of  $\alpha$ MSH. So, low levels of  $\alpha$ MSH are seen even when leptin levels are adequate and the gene expression for the precursors is normal. Further, if ER stress is treated by giving Tauroursodeoxycholic acid (TUDCA) or, PBA (4-phenyl butyric acid) to the obese rats,  $\alpha$ MSH levels recovered, So, the root cause of self-perpetuating obesity may be the breakdown of ER protein processing. This explanation is novel and intractable obesity may become treatable in near future (<http://news.brown.edu/pressreleases/2013/05/obesity>)

- Dr. K. Ramesh Rao