

Case Report

Solitary Giant Neurocysticercosis In A Child With Combined Immunodeficiency

Dr.K.V.Karthikeyan* Dr.V.G.Ramesh**

*Consultant Neurosurgeon, **Professor &HOD , Department of Neurosciences, Chettinad Super Speciality Hospital, Chennai, India



Dr.K.V.Karthikeyan is currently working as Consultant Neurosurgeon at Chettinad Super Speciality Hospital. He completed his graduation in 2001 from the prestigious Madras Medical college and completed his MCh (Neurosurgery -5 yrs) from the Madras Institute of Neurology at Madras Medical college in 2007. He is very well trained in Micro neurosurgery and vascular neurosurgery. He joined our institute in 2010. He has special interest in Vascular Neurosurgery and Endoscopic Neurosurgery.

Corresponding author - [Dr.K.V.Karthikeyan \(surgenn@gmail.com\)](mailto:Dr.K.V.Karthikeyan(surgenn@gmail.com))

Chettinad Health City Medical Journal 2014; 2(1): 9 - 10

Abstract

Neurocysticercosis is one of the most common CNS infections in both adult and paediatric age group. Giant Neurocysticercosis is a rare phenomenon in brain. Few cases have been reported in adult population. Solitary giant cystic neurocysticercosis in paediatric age group have not been reported in literature. Here, an 8 yr old boy, already a known case of combined immunodeficiency since birth with frequent chest, skin and mucocutaneous infection presented with large intracranial cystic lesion. CT and MRI imaging showed a non contrast enhancing cystic lesion. Intra operatively a cystic lesion with live worm and scolex removed and confirmed with histopathology as Neurocysticercosis. Giant neurocysticercosis has not been reported in severe combined immunodeficiency patients. Hence we present this interesting case.

Key words : Giant – Cysticercosis – Combined Immunodeficiency

Case Report

An 8 year old boy presented with history of progressive weakness of left upper limb for the past 4 weeks duration and headache for 2 weeks duration. Patient had history of repeated chest, skin and mucosal infection since birth and he was recently diagnosed as Combined immunodeficiency in the form of both B cell and T cell dysfunction. Biochemical and pathological tests confirmed it. On examination the boy was conscious, oriented, and had early papilloedema. He had left hemiparesis of grade IV power. MRI Brain showed a well circumscribed non contrast enhancing 8x7 cm single cystic lesion in the right temporo parietal region with mass effect. Patient underwent a right temporo parietal craniotomy and trans sulcal approach. At a depth of 3 cm a solitary cyst along with wall was removed completely without any spillage. The post operative period was uneventful and the hemiparesis recovered completely during 6 week follow up. Histopathology confirmed as cysticercus with scolex.

Discussion

Neurocysticercosis is the most common parasitic infection of the CNS caused by *T.Solium*. Neurocysticercosis is further divided into parenchymal and extraparenchymal disease. Parenchymal disease is characterized by infection with cysticerci within the brain parenchyma. Extraparenchymal disease develops when cysticerci migrate to the CSF of the ventricles,

cisterns, and subarachnoid space or within the eyes or spinal cord.

Approximately 10-20% of patients with neurocysticercosis present with extraparenchymal disease, often with concomitant parenchymal disease. Subarachnoid neurocysticercosis may form in the gyri of the cerebral convexities or in the fissures of the brain, especially the sylvian fissures. These forms of neurocysticercosis are associated with parenchymal inflammation and resemble parenchymal disease in manifestations and pathogenesis.

Oncospheres that invade the brain may lodge in the brain parenchyma, subarachnoid space, ventricular space¹, or spinal cord. Cysticerci develop after 2 months and may or may not stimulate an appreciable inflammatory response.

In the brain parenchyma, cysticerci form a thin capsule of fibrous tissue that thickens with time. After several years, the parasite dies or is killed and is replaced by an astroglial and fibrous tissue granuloma due to the immune reaction, that becomes calcified. Cysts that grow in the sylvian fissure and in the subarachnoid space at the base of the skull may enlarge to 10 - 15 cm in diameter. Meningeal and spinal cord cysticercosis occurs if the oncospheres enter via the choroid plexus and hatch in the arachnoid membranes along the neural axis.

Most of the cysticercosis infection are small lesion and they elicit strong immune mediated inflammatory reaction which in turn causes extensive surrounding edema and they present with seizure or neurological deficits. But in immunodeficiency patients due to the lack of immune reaction they remain asymptomatic until they become big in size and present with increased Intra Cranial Pressure (ICP) features^{2,3}.

The number of cysticerci present ranges from one to several hundred. But solitary giant cysticercosis without any immune reaction has been reported only in very few instances. Most of the cysticercosis are treated with medical management. Only giant lesions causing ICP features require surgical excision⁴.

Conclusion

Neurocysticercosis present mostly as single or multiple lesions with strong immune reaction like surrounding edema. Solitary giant cysticercosis are rare in children.

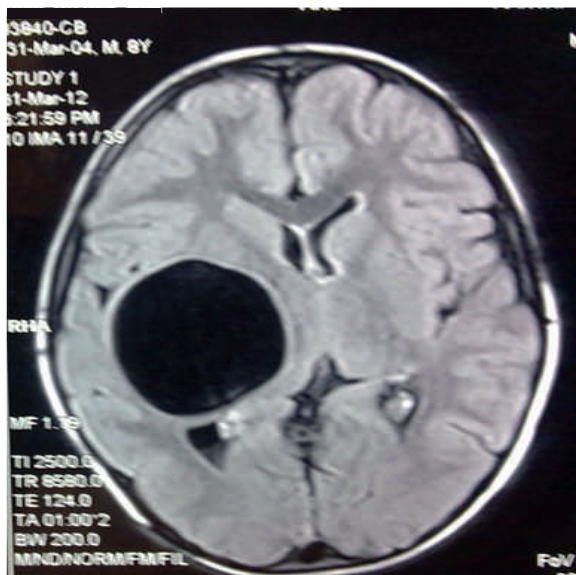


Fig 1: MRI T1 Showing Large Cystic Lesion In Right Temporoparietal Region

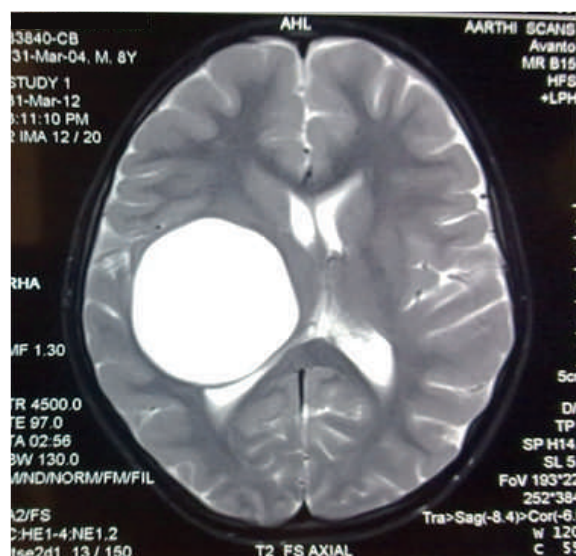

Fig 2: MRI Brain T2 Sequence Showing Large Cyst In Right Temporoparietal Region

That too occurring with background of Combine Immunodeficiency has not been reported so far.




Fig 3: Resected Cyst along with worm

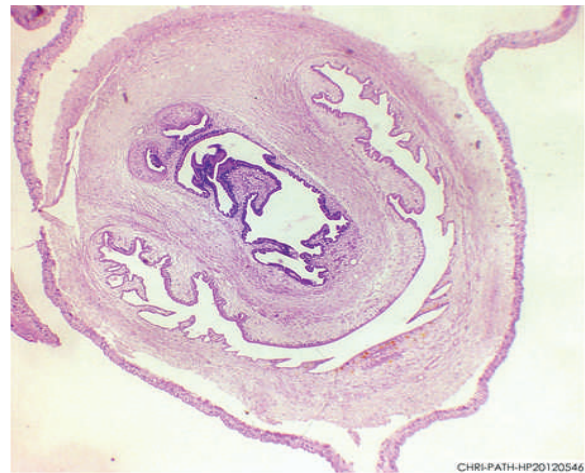

Fig 4: Histopathology showing scolex with wall lined by eosinophilic and mononuclear infiltrates

References

- 1) Bansal KK, Gupta C, Goel D, Singhal A, Bansal R. Giant fourth ventricular cyst : diagnostic and therapeutic dilemmas. *J Assoc Physicians India*. 2006 Apr;54:289.
- 2) Ramesh VG, Parthiban A. Giant parenchymal cysticercosis with unusual imaging features. *J Clin Neurosci*. 2008 Dec;15(12):1404-6. doi: 10.1016/j.jocn.2007.09.026.
- 3) Umredkar A, Singla N, Mohindra S, Bal A, Gupta SK. Giant intraparenchymal neurocysticercosis: report of surgical aspects two cases. *Neurol India*. 2009 Nov-Dec;57(6):800-2. doi: 10.4103/0028-3886.59483.
- 4) Brandão RA, Nunes TW, Dellaretti Filho MA, Tótola PV, Fonseca VS, Souza WC. Giant Neurocysticercosis: diagnosis and treatment. *Rev Assoc Med Bras*. 2010 Jul-Aug;56(4):395-6.