

Case Report

Unusual Ocular Manifestations in a Patient with Alport's Syndrome

Durga Krishnan*, Pavithra T**, Thuvaragah P***, Rajasekaran D****

*Associate Professor, **Postgraduate Student, ***Sr. Resident, ****Prof. & HOD, Department of General Medicine, Chettinad Hospital & Research Institute, Chennai, India.



Dr. Durga Krishnan is currently working as Associate Professor, Department of Internal Medicine, CHRI. She did her MBBS and MD from Devi Ahilaya Vishwavidyalaya, Indore, Madhya Pradesh.

Corresponding author - Durga Krishnan (drdurga79@gmail.com)

Key Words: Alport's syndrome, Coloboma, Thin basement membrane disease

Chettinad Health City Medical Journal 2015; 4(1): 58 - 59

Introduction

Alport's syndrome or hereditary nephritis is a rare genetic disorder of basement membrane, clinically characterized by haematuric nephritis, sensorineural deafness and characteristic ocular manifestations¹. We report a case of Alport's syndrome with unusual ocular presentation featuring bilateral congenital coloboma of optic disc with unilateral pigmentary retinopathy. This is a rare ophthalmological finding in Alport's syndrome.

Case summary

A 23 year old male presented with bilateral progressive diminution of vision for one year and progressive hearing loss for 6 months. Patient also had decreased urine output and swelling of both legs for the 2 months, shortness of breath and easy fatigability for one month. Patient gave a history of renal calculi since 15 years, which had been managed conservatively. There was a history of kidney disease in both of his brothers. His elder brother had macroscopic haematuria and proteinuria while the other had renal calculi. Both of them did not have renal dysfunction severe enough to need active intervention.

On examination, patient had pallor with bilateral pedal edema and hypertension (BP160/100 mmHg). Respiratory examination revealed bilateral basal crepitations and other systems were normal. His visual

acuity was diminished. Slit lamp examination of eyes revealed bilateral congenital coloboma of optic disc with unilateral pigmentary retinopathy in the left eye (Fig 1).

His Hb was 4.8 gm/dl with total WBC count 9700/mm³, blood urea was increased (133 mg/dl), the serum creatinine was elevated (35.30 mg/dl), and his electrolytes were normal. Urine examination showed proteinuria (albumin 3+) and microscopic haematuria. Renal ultrasound showed bilateral contracted kidneys (left- 5.8 x 2.8 cms, right- 6.2 x 2.8 cms) with loss of corticomedullary differentiation. Audiometry revealed bilateral moderate sensorineural hearing loss.

As patient was very apprehensive about renal biopsy and he had bilateral contracted kidneys, renal biopsy was deferred.

On the basis of typical triad of positive family history, sensorineural deafness and medical renal disease, a clinical diagnosis of Alport's syndrome was made. Patient was treated with diuretics, antihypertensives, blood transfusion, hearing aid and maintenance hemodialysis.

Discussion

Alport Syndrome is a progressive form of thin basement membrane disorder with an approximate incidence of 1 in 50,000 live births². It is a disorder arising from mutations

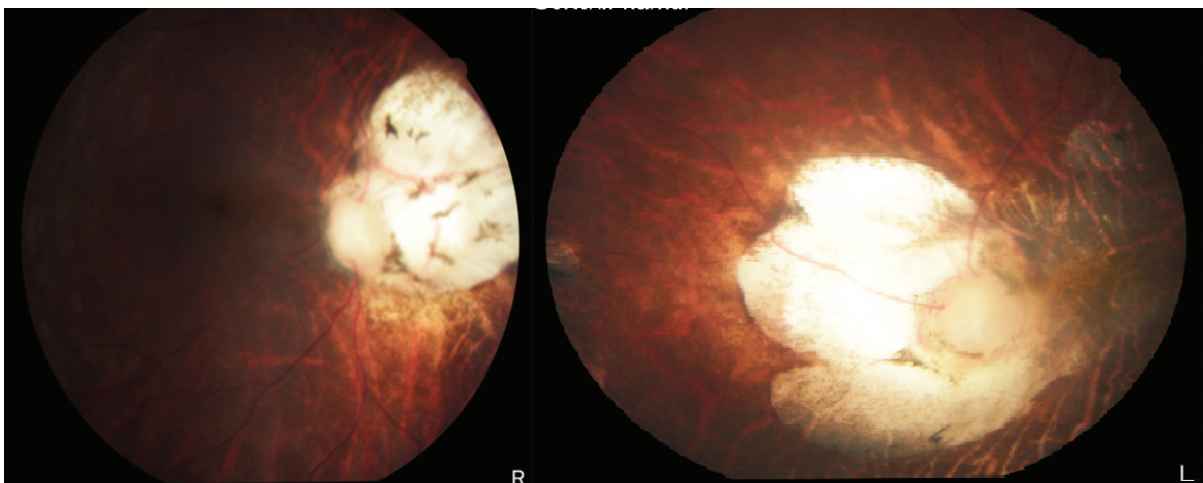


Fig 1 - Slit-examination showing bilateral congenital coloboma of optic disc, left eye unilateral pigmentary retinopathy

in type IV collagen (*col4A3*, *col4A4*, and *col4A5*) biosynthesis genes³. It develops at a younger age and occurs more common in males due to X linked dominant inheritance pattern. Thus, an impairment or change in collagen network found in the glomerular basement membrane, cochlea and anterior lens capsule will lead to gross or microscopic hematuria, proteinuria, end stage renal disease, bilateral sensorineural hearing loss and ocular defects like anterior lenticonus (commonest), posterior capsular cataract, capsular dystrophy, Dot and Fleck Retinopathy⁴. The other rare ocular manifestations include posterior polymorphous corneal dystrophy, posterior lenticonus, cataract, recurrent corneal erosion and macular degeneration⁵.

Our patient had bilateral congenital coloboma of optic disc, causing impairment of visual fields, along with dot and fleck retinopathy.

Even though diagnosis of Alport's Syndrome can be made by the classical triad, electron microscopic examination of renal biopsy specimen is diagnostic in cases without classic findings. But in our case, since biopsy was not done, the differential diagnosis included were other glomerular disorders that are present with microscopic hematuria like IgA nephropathy and thin basement membrane nephropathy. In IgA nephropathy, family history is usually negative and in thin basement membrane nephropathy, the family history may be positive for hematuria, but renal failure and deafness are typically absent.

Treatment involves conservative medical management, dialysis or renal transplantation for renal failure. If ocular manifestations like anterior lenticonus and posterior capsular cataract cause visual impairment, they can be managed by lens extraction. Hearing aids are useful in those with sensorineural hearing loss.

Conclusion

The characteristic clinical manifestations of Alport's syndrome are hematuric nephritis, hearing and visual defects. However, the presence of other ocular defects such as coloboma should also prompt a search for Alport's syndrome.

References

- 1) Kruegel, Diana R, Oliver G. Alport syndrome- insights from basic and clinical research. *Nature Reviews Nephrology* 2013; 9: 170-178.
- 2) Thorner PS. Alport syndrome and thin basement membrane nephropathy. *Nephron Clin Pract.* 2007;106(2):c82-8.
- 3) Badenas C, Praga M, Tazon B, et al. Mutations in the *col4A4* and *col4A3* genes cause familial benign hematuria. *J Am Soc Nephrol.* 2002;13:1248-54.
- 4) Gross O, Netzer KO, Lambrecht R, Seibold S, Weber M. Novel COL4A4 splice defect and in-frame in a large consanguine family as a genetic link between benign familial haematuria and autosomal Alport syndrome. *Nephrol Dial Transplant.* 2003;18:1122-7.
- 5) J A Govan. Ocular manifestations of Alport's syndrome: a hereditary disorder of basement membranes. *Br J Ophthalmol.* Aug 1983; 67(8): 493-503.