

Case Report

Clinicopathologic Case Report of Retrosternal Goitre

Sushma Nayar*, Sivasailam R**, Anantharama Krishnan R***, Arumugam C****, Sudha S*****, Sanjay Theodore*****

*Professor, Department of Pathology, ** Assistant Professor, Department of Anaesthesia, *** Professor, Department of General Surgery, ****Associate Professor, Department of Cardiology, *****Physician Assistant, *****Sr. Consultant, Cardio Thoracic Surgeon, Chettinad Super Speciality Hospital, Chennai, India



Dr. Sushma Nayar did her MD in Pathology from Patna Medical College, Patna. After gaining experience in various premier corporate hospitals, she joined Chettinad Hospital and Research Institute. She is currently Professor in the Department of Pathology.

Corresponding author - Sanjay Theodore (sanjayawake@gmail.com)

Key words : Retrosternal Goitre, Tracheal compression, Non- resolving pneumonia

Chettinad Health City Medical Journal 2015; 4(1): 43 - 45

Case summary

A 60 year old male patient was transferred to our hospital with a diagnosis of community acquired lobar pneumonia and scrub typhus. He was a diabetic and hypertensive and was also positive for the HbsAg antigen. He was being treated with mechanical ventilation for respiratory failure and antibiotics for pneumonia and scrub typhus. His general condition, sepsis and respiratory status gradually improved. He was taken off mechanical ventilation on the second day following admission to the intensive care unit; however he developed an inspiratory stridor and respiratory distress for which he was put back on

mechanical ventilation. CT scan of the thorax showed an anterior mediastinal mass contiguous with the lower lobe of the thyroid, compressing the trachea and extending behind the arch of the aorta (fig 1 & 2). The lung windows were consistent with diffuse pneumonic changes with bilateral small pleural effusions. He underwent surgical resection and a subtotal thyroidectomy through a collar incision and a upper hemi- sternotomy. The mass was confirmed to be a colloid Goiter (Fig 3).He was weaned off the ventilator in 12 hours and was discharged home on the eighth postoperative day.

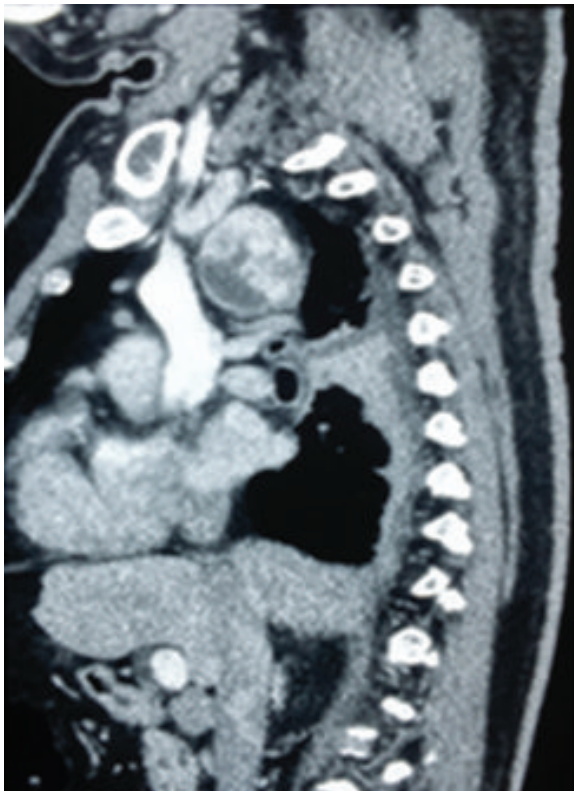

Fig 1 - Sagittal view of thyroid mass compressing the trachea

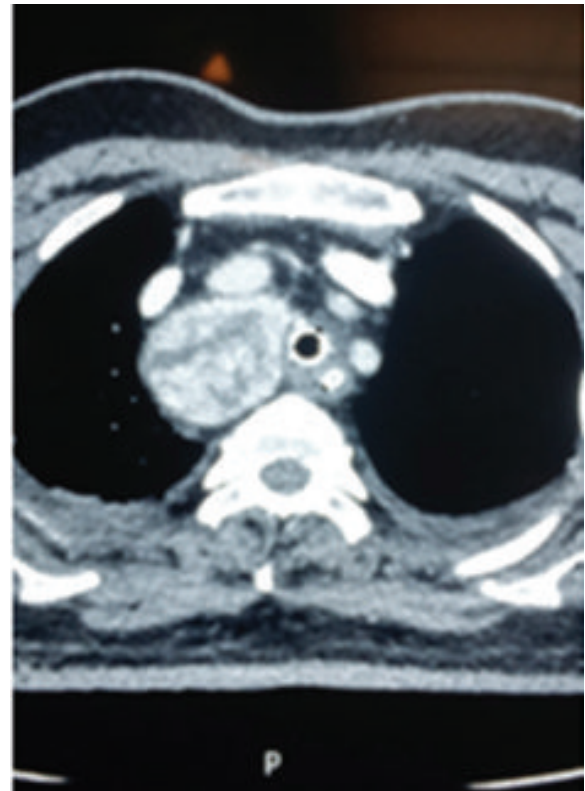


Fig 2 - Coronal view of thyroid mass compressing the trachea

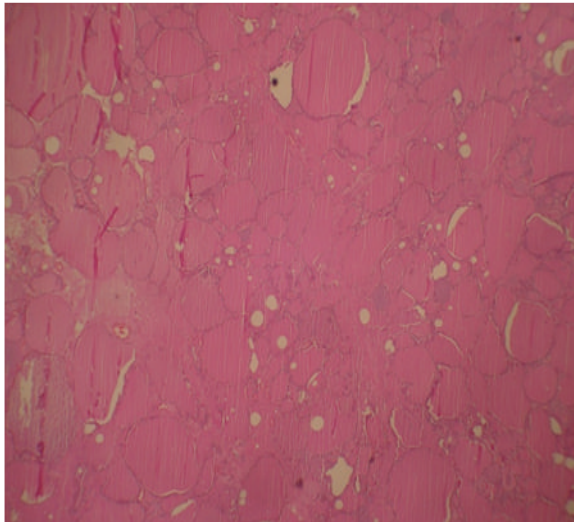


Fig 3 - Photomicrograph of haematoxylin and eosin stained sections showing Thyroid follicles of varying sizes filled with colloid (4X10X).

The absence of toxemia and minimal pleural effusion, ruled out abscess, empyema. Echocardiography ruled out endocarditis. Sputum AFB and other cultures ruled out tuberculosis and fungal infections.

Malignancy, pulmonary embolism, systemic inflammatory disorders were systematically ruled with a combination of history, lower limb Doppler and appropriate immunological blood investigations(Fig4).

The CT scan confirmed the presence of a mass lesion compressing the trachea that explained the difficulty in weaning the patient off ventilator support (Fig 1 & 2).

- In a patient with unresolving or slowly resolving pneumonia, unusual causes and unusual organisms are suspected only after treatment failure.
- A systematic approach to ruling out all causes will prevent life threatening situations

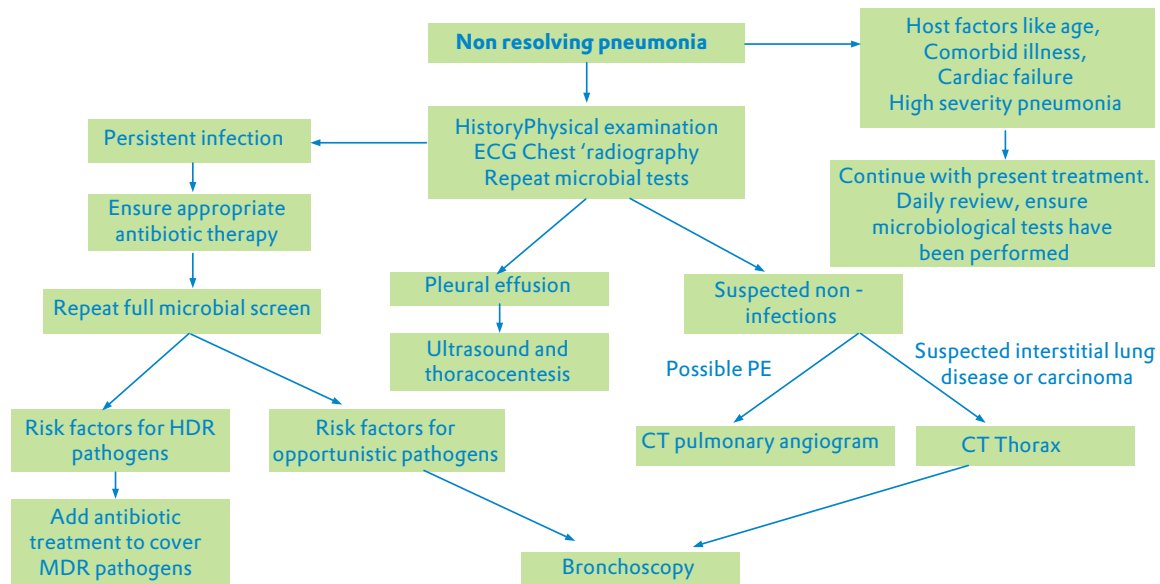


Fig 4 - An algorithm for the investigation and management of non-resolving pneumonia.

Discussion

Intensive care perspective

Differential diagnosis of non resolving pneumonia

1. Complications of pneumonia like empyema or abscess
2. Infective endocarditis
3. Host factors such as old age, alcoholism, immunosuppression and multilobar pneumonia
4. Unusual organisms like tuberculosis, fungi, multi drug resistant pathogens
5. Malignancy or mass lesion with airway obstruction
6. Systemic inflammatory disorders such as SLE, Wegener’s granulomatosis etc
7. Drug induced lung disease
8. Pulmonary embolism with infarct

- Rare causes of mass lesions compressing the airways should prompt the clinician to consider more exhaustive imaging techniques.

A surgical and pathological perspective

Differential diagnosis of a mass in the anterosuperior mediastinum.

1. Thymic neoplasms
2. Thyroid and parathyroid neoplasms
3. Lymphomas
4. Germ cell tumours
5. Thoracic aortic aneurysms

A goiter that extends beyond the thoracic inlet is termed a retrosternal goiter¹. Retrosternal goiters are rare, they are extremely difficult to diagnose if they are

confined to the mediastinum. The incidence varies from 0.02-0.5% in a chest X ray screening series².

The differential diagnosis should include thymic tumours and lymphomas, these are significantly more common in the antero-superior mediastinum. Presenting symptoms are diverse and include, shortness of breath, dysphagia, hoarseness of voice and stridor³, however contrary to popular belief tracheomalacia is uncommon.

The common surgical approaches include a cervical collar incision, upper sternotomy, full sternotomy and rarely lateral thoracotomy⁴.

Learning Points

- Retrosternal goiters can be approached through a variety of incision, the ideal incision should give good access for a complete resection.
- Tracheomalacia is extremely rare⁴
- Malignancy in a retrosternal goiter is rare (2-3%)
- A mass attached to the thyroid is most likely a retrosternal goiter⁵
- Ectopic thyroid present in the anterior mediastinum may result in a retrosternal goiter and blood supply is derived from mediastinal vessels⁶

Conclusion

Retrosternal goiters can present with obstructive symptoms and pneumonia. A systematic approach is required to make an early diagnosis to prevent further patient morbidity, surgical approach should be tailored to the size and location of the goiter.

References

- 1) Reeve TS, Rubenstein C, Rundle FF. Intrathoracic goitre. Its prevalence in Sydney metropolitan mass X-ray survey. *Med J Austr* 1957; 2:149-151.
- 2) Hunis CT, Gerogalas C, Mehrzad H, Tolley NS. A new classification system for retrosternal goitre based on a systemic review of its complications and management. *Int J Surg* 2008; 6:71-76.
- 3) Moran JC, Singer JA, Sardi A. Retrosternal goitre: A six-year institutional review. *Am Surg* 1998; 64: 889-893.
- 4) Bennett AM, Hashmi SM, Premachandra DJ, Wright MM. The myth of tracheomalacia and difficult intubation in cases of retrosternal goitre. *J Laryngol Otol* 2004; 118;778-780. (Review)
- 5) Balasubramanian SP, Harrison BJ. Asymptomatic retrosternal goiter-A case for Primum Non Nocere. *Am R Coll Surg Engl*. Jan 2009;91(1):10-11
- 6) Rugiu MG, Piemonte M. Surgical approach to retrosternal goitre : do we still need sternotomy? *Acta Otorhinolaryngol Ital*. 2009 Dec; 29(6): 331-338.