

Case Report

Anesthetic Management of Posterior Reversible Encephalopathy Syndrome in a Patient with Eclampsia

Boban V*, Balamurugan B**, Lailu Mathews***

*Final year Postgraduate, **Professor, ***Professor & HOD, Department of Anesthesiology and Critical Care, Chettinad Academy of Research & Education, Chennai, India.



V Boban did his M.B.B.S from Sree Balaji Medical College. He is presently doing Final year M.D. Anesthesia in Chettinad Medical College. His area of interest is Critical Care Anesthesia.

Corresponding author - Dr. Boban.V (boban.psla@gmail.com)

Chettinad Health City Medical Journal 2016; 5(4): 192 - 195

Abstract

"Posterior reversible encephalopathy syndrome (PRES)" is a clinico radiological entity, the characteristic neuro-imaging features and non-specific symptoms including headache, confusion, visual disturbances and seizures. Vasogenic edema, which is the most probable underlying pathology results in detectable Parieto-occipital white matter changes in imaging. Vasogenic edematous changes of PRES are reported to be reversible with appropriate clinical management. Eclampsia is one of the underlying etiologies of PRES and prompt diagnosis and treatment of eclampsia are important as cerebrovascular damage caused by eclampsia may result in permanent neurologic sequelae. Termination of pregnancy by caesarean section is the mainstay in the management of PRES. Patients with eclampsia and PRES for caesarean section are a challenge to the anesthesiologist that involves management of airway, arterial oxygenation, control of blood pressure & seizure, hydration, correcting electrolyte disturbances and coagulopathy. This is a case report of anesthetic management of a pregnant woman with PRES due to eclampsia.

Key Words: Posterior reversible encephalopathy syndrome, Pregnancy, Hypertension, Eclampsia, Anesthesia

Introduction

Posterior reversible encephalopathy syndrome (PRES)" is a clinico-radiological entity characterized by headache, altered sensorium, seizures, visual disturbances and vasogenic edema on neuroimaging". PRES is characterized by reversible white matter lesions in parietal and occipital lobes; however progressive ischemic injury may lead to irreversible damage. Prompt control of blood pressure or discontinuation of the offending medication leads to the reversal of the clinical and radiological abnormalities. A variety of clinical situations like hypertension, eclampsia, pre-eclampsia, metabolic states like severe hypercalcemia, platelet or clotting disorders like thrombocytopenic syndromes, Henoch-Schonlein purpura, haemolytic uraemic syndrome may cause PRES. Connective tissue disorders like amyloid angiopathy, Systemic Lupus Erythematous (SLE) etc., are also reported to cause PRES. Other commonly reported causes are renal failure, post-transplantation, infection, sepsis and treatment with immunosuppressive agents like cyclosporine and various antineoplastic agents.²

Hinchey in 1996 was the first one to report an association eclampsia with PRES. Eclampsia is the development of generalized convulsions during pregnancy or in the postpartum period. In eclampsia, the onset of seizures is usually preceded by syndrome of preeclampsia, which includes proteinuria, edema and hypertension during the antepartum, intrapartum or post-partum period.^{1,3}

Patients with eclampsia and PRES are a real challenge to the anaesthesiologist and the obstetrician. The goals in the management of PRES include (i) Reduced dose or discontinuation of drug causing PRES (ii) Lowering of blood pressure, in hypertensives (iii) control of seizures and (iv) in pregnant patients termination of pregnancy by caesarean section, if symptoms are refractory. In addition, maintenance of airway and arterial oxygenation, sufficient hydration, management of hypoglycaemia, correcting electrolyte disturbances and coagulopathy should also be addressed simultaneously.⁴

Optimal maintenance of Blood pressure and control of seizures are vital in treating and preventing progression of cerebral edema. In antenatal women with eclampsia associated with PRES, Magnesium sulfate has been the first line drug. For other patients with PRES the recommended medication include, antihypertensive drugs like hydralazine or labetalol and anti-seizure medication. Close monitoring is recommended for all the patients while on treatment⁵. MRI brain is the diagnostic modality of choice in diagnosis and monitoring of PRES, as it effectively demonstrates the changes in brain lesions.

This case study reports anesthetic management of a patient presented with eclampsia and who went on to develop PRES.

Case Report

A 25-year-old primigravida at 35 weeks and 3 days of gestation with irregular antenatal checkup presented in the emergency department with complaints of headache, altered sensorium, and four episodes of seizures that lasted for about 20 to 30 seconds each. There was no past history of seizures, hypertension, or any other neurological or cardiac disease. On examination, the patient was restless and disoriented with GCS of 12/15 and bilateral pedal edema. Pupils were equal in size and exhibited normal reaction to light. Her heart rate was 130 bpm and blood pressure (BP) on admission was recorded, which was 160/110 mm Hg and 170/110 mm Hg respectively on two successive readings taken at an interval of 5 min. Her respiratory rate was 20 breaths/min displaying a pulse oximetry reading of 96% on room air. Her systemic examination did not reveal anything significant. Investigation was done under emergency basis. Hemogram, renal and liver function tests, and coagulation profile were under normal limits.

A provisional diagnosis of eclampsia was made and Inj. Magnesium Sulfate was initiated as per the Pritchard's regime. The loading bolus dose of 4g MgSO₄ was given slowly intravenously over 5-10 min and followed by 5g given intramuscularly into each buttock. For effective control of hypertension, intravenous Labetalol 20 mg was given slowly. Considering the critical nature of the obstetric condition, the patient was shifted to the operation theatre for emergency caesarean section under general anesthesia.

Rapid sequence induction was carried out using Inj. Thiopentone 250 mg IV and Inj. Succinylcholine 100 mg IV and the airway was secured with cuffed oral endotracheal tube of size 7 mm internal diameter. To reduce the intubation response Inj. Esmolol 5mg IV was given 2 minutes prior to the intubation. Anesthesia was maintained with Isoflurane (0.5-1%) in oxygen and air (1:1) and Inj. Atracurium 15 mg IV was administered to facilitate muscle relaxation. A 2.2 kg male baby was delivered and was shifted to neonatal ICU because of low Apgar score of 7/10 and 8/10 at 1 and 5 min respectively. Analgesia was achieved with 100 µg of intravenous Fentanyl. Intraoperative systolic blood pressure remained between 130 and 150 mmHg, whereas diastolic blood pressure remained between 80 and 90 mmHg. Intraoperative blood loss was estimated at 500 ml and a total of 1500 ml of crystalloid solution (Ringer's lactate) was infused during the entire procedure, which lasted for 1 hour. After the surgical procedure, residual muscular blockade was reversed with Inj. Neostigmine 2.5mg IV and Glycopyrrolate 0.5 mg IV and trachea was extubated when patient was fully awake with rhythmic breathing with adequate tidal volume.

For better monitoring during postoperative period, the patient was shifted to high dependency unit. Two hours after the caesarean section, the patient developed sudden hypertension of 170/100 mmHg along with headache and vomiting. After a rapid clinical review, patient was started on Inj. Phenytoin sodium 100 mg thrice daily, Inj. Magnesium sulphate 5 gm intramuscular 4th hourly and Inj. Labetolol 1mg / hr IV infusion.

During this period, the patient became progressively drowsy and was immediately intubated and put on mechanical ventilation SIMV-PS mode with TV 450ml FiO₂ 40%, PEEP 5cm H₂O, SIMV rate 12/minute. Under all aseptic precautions, an arterial line was inserted and the right internal jugular vein was cannulated to maintain a CVP of 10-12 cm H₂O.

Infusion Inj. Midazolam 2.5 mg and Inj. Fentanyl 30 mcg/hr was started for sedation. Inj. Magnesium sulphate 5 gm intramuscular 4th hourly was continued for 24hrs and hourly urine output was monitored for identifying any toxicity. Inj. Mannitol 100ml was started as an antiedema measure for cerebral protection. Strict HR, BP, urine output and second hourly ABG monitoring was done.

Her BP and hemodynamic status stabilized almost after 12 h of this therapeutic intervention. Considering the seriousness of present neurological status, computed tomography (CT) scan and magnetic resonance imaging (MRI) was performed, which showed bilateral hypo dense cerebral hemispheres involving predominantly parieto-occipital lobes suggestive of PRES (Fig 1).

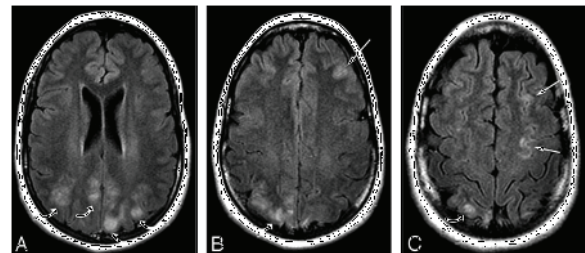


Fig 1 : MRI - Hypointense area seen predominantly in parieto-occipital lobes and minimally in frontal region

On the second postoperative day, the patient's sensorium improved significantly. She was gradually weaned off from the ventilator and was successfully extubated. By the third postoperative day, the patient had completely recovered and did not exhibit any neurological sequelae and was shifted to the ward. Rest of her stay in the hospital was uneventful, and she was discharged on the tenth postoperative day.

Discussion

"Posterior reversible encephalopathy syndrome (PRES) is a rare and serious entity of the central nervous system, characterized by headache, altered mental status, seizures, and visual loss. Seizures, are usually generalized and tonic clonic and are often the presenting manifestation".⁶ The proposed pathological mechanism temporary failure of autoregulatory capabilities of the cerebral vessels, resulting in hyperperfusion, disruption of the blood brain barrier leading to vasogenic edema.

Neuroimaging CT shows edema as bilateral symmetrical hypodensities involving the white matter typically in the parieto-occipital regions. This is explained by better autoregulation of the anterior circulation due to better sympathetic innervations as compared to the posterior circulation.⁸ Magnetic

resonance imaging shows "high signal intensity on T2-weighted and fluid attenuated inversion recovery (FLAIR) sequences".⁹

Demyelinating diseases, basilar artery embolism, and venous sinus thrombosis are the other neurological conditions mimicking PRES and should be considered as differential diagnosis.¹⁰ PRES is reported to be rapidly responsive to aggressive treatment, with remission of clinical and radiological findings. Clinical improvement always follows the treatment of elevated blood pressure and withdrawal of offending agents. Magnesium therapy, considering its effect both on blood pressure and seizures should be considered as the treatment of choice and must be initiated as soon as eclampsia or PRES is suspected in antenatal women.¹¹

Attending to the underlying etiological factors is the essential first step in the management. Prevention of hypertension and other triggering factors (cytotoxic stimuli, immunosuppressive medication, sepsis etc.) is extremely vital. In the current case eclampsia was the most probable etiology, considering her pregnancy and the likelihood of encephalopathy resulting from disturbed blood pressure autoregulation.^{10, 12}

Striano et al. in their retrospective review of 3000 cases, have identified 8 PRES cases. Out of the eight, Five had eclampsia and postpartum eclampsia was found in another two women.¹³ In spite of its clearly documented role in eclampsia, magnesium sulphate is reported to have limited role in prevention of postpartum eclampsia.¹⁴ Thiopental sodium is successfully used in this situation. Our patient was induced with Inj.Thiopentone sodium with the dual aim of preventing seizures and for rapid sequence induction.^{10, 15}

The current patient was diagnosed with PRES and responded well to treatment. Magnesium sulphate is usually administered as a loading dose of 4 to 6 grams intravenously over 20 minutes and then continued at the rate of 1 to 2 gm/ hour. All the necessary clinical parameters including deep tendon reflexes, respiratory rate, heart rate, blood pressure, and urine output needs to be monitored closely.¹⁰ Magnesium usually acts by antagonizing glutamate's attachment to n-methyl-d-aspartate (NMDA) receptors. This in turn decreases the transport of calcium in presynaptic space and blocks the release of acetylcholine. This will result in reduction of postsynaptic membrane sensitivity and muscle membrane stimulation. During general anesthesia, even in patients on standard doses of magnesium sulphate, the effect of neuromuscular blocking agents can be potentiated, and their duration can be prolonged.¹⁶ Low biotransformation rate, short half life with low renal clearance drugs must be chosen for general anesthesia. Beta blockers, small dose of magnesium sulphate and nitroglycerin are used to blunt the intubation response and intra operative hypertensive attacks.¹⁷ Treatment of seizures, lowering blood pressure, removal or significant reduction of causative medications are mandatory, these problems are best managed in the intensive care setting in step wise manner.¹⁸

Stepwise treatment of PRES is as follows:

- i. Removal/significant reduction in the causative factors
- ii. Maintenance of hydration, correction of electrolyte disturbance, coagulopathy and adequate oxygenation.
- iii. Monitoring of airway and ventilation.
- iv. Insertion of central venous catheter and monitoring of volume status and cardiac output.
- v. Lowering of blood pressure.

Conclusion

PRES is a clinical condition caused by varied etiological factors and its clinical presentations vary. PRES, even though a reversible condition can lead to brain damage, if not recognized and managed in time. This can be confirmed by radio imaging studies¹⁰. If a pregnant patient presents with preeclampsia, seizures, altered sensorium in the peripartum, intrapartum (during delivery) or postpartum period, we must suspect the possibility of PRES and relevant investigation must be promptly done. The early diagnosis of PRES in eclampsia is of vital importance, as prompt control of blood pressure will cause reversal of the syndrome. Control of blood pressure and seizures and antiedema measures are the main stay treatment of PRES. Delay in the diagnosis & treatment can lead to permanent damage to the affected brain tissues. Importantly, treating the underlying cause will help to resolve the symptoms without neurological deficit as seen in this patient.

References

- 1) Hinchey J, Chaves C, Appignani B, Breen J, Pao L, Wang A, et al. A reversible posterior leukoencephalopathy syndrome. *N Engl J Med.* 1996;334(8):494-500.
- 2) Bartynski WS, Boardman JF, Zeigler ZR, Shaddock RK, Lister J. Posterior reversible encephalopathy syndrome in infection, sepsis, and shock. *AJNR Am J Neuroradiol.* 2006;27(10):2179-90.
- 3) Report of the National High Blood Pressure Education Program Working Group on High Blood Pressure in Pregnancy. *Am J Obstet Gynecol.* 2000;183(1):S1-S22.
- 4) Staykov D, Schwab S. Posterior reversible encephalopathy syndrome. *J Intensive Care Med.* 2012;27(1):11-24.
- 5) Yi JH, Ha SH, Kim YK, Choi EM. Posterior reversible encephalopathy syndrome in an untreated hypertensive patient after spinal surgery under general anesthesia-A case report. *Korean J Anesthesiol.* 2011;60(5):369-72.
- 6) Kastrup O, Gerwig M, Frings M, Diener HC. Posterior reversible encephalopathy syndrome (PRES): electroencephalographic findings and seizure patterns. *J Neurol.* 2012;259(7):1383-9.
- 7) Lamy C, Oppenheim C, Meder JF, Mas JL. Neuroimaging in posterior reversible encephalopathy syndrome. *J Neuroimaging.* 2004;14(2):89-96.
- 8) Schwartz RB, Mulkern RV, Gudbjartsson H, Jolesz F. Diffusion-weighted MR imaging in hypertensive encephalopathy: clues to pathogenesis. *AJNR Am J Neuroradiol.* 1998;19(5):859-62.

- 9) Casey SO, Sampaio RC, Michel E, Truwit CL. Posterior reversible encephalopathy syndrome: utility of fluid-attenuated inversion recovery MR imaging in the detection of cortical and subcortical lesions. *AJNR Am J Neuroradiol.* 2000;21(7):1199-206.
- 10) Demirel I, Ozer AB, Bayar MK, Kavak SB. Anesthesia and intensive care management in a pregnant woman with PRES: a case report. *Case rep anesthiol.* 2012;2012 :745939
- 11) Thackeray EM, Tielborg MC. Posterior reversible encephalopathy syndrome in a patient with severe preeclampsia. *Anesthesia and analgesia.* 2007;105(1):184-6.
- 12) Uwatoko T, Toyoda K, Hirai Y, Shimada T, Yasumori K, Ibayashi S, et al. Reversible posterior leukoencephalopathy syndrome in a postpartum woman without eclampsia. *Internal medicine.* 2003;42(11):1139-43.
- 13) Striano P, Striano S, Tortora F, De Robertis E, Palumbo D, Elefante A, et al. Clinical spectrum and critical care management of Posterior Reversible Encephalopathy Syndrome (PRES). *Medical Science Monitor.* 2005;11(11):CR549-53.
- 14) Sibai BM. Diagnosis, prevention, and management of eclampsia. *Obstet Gynecol.* 2005;105(2):402-10.
- 15) Malbora B, Avcı Z, Donmez F, Alioğlu B, Alehan F, Alehan F. Posterior reversible leukoencephalopathy syndrome in children with hematologic disorders. *Turk J Hematol.* 2010;27(3):168-76.
- 16) Sipes SL, Weiner CP, Gellhaus TM, Goodspeed JD. The plasma renin-angiotensin system in preeclampsia: effects of magnesium sulfate. *Obstet Gynecol.* 1989;73(6):934-7.
- 17) Kambam JR, Mouton S, Entman S, Sastry B, Smith BE. Effect of pre-eclampsia on plasma cholinesterase activity. *Canadian journal of anesthesia.* 1987;34(5):509-11.
- 18) Andrews P, Azoulay E, Antonelli M, Brochard L, Brun-Buisson C, Dobb G. Year in review in Intensive care medicine : infection and sepsis, ventilator-associated pneumonia, ICU organisation and scoring of brain injury . *Intensive Care Med* 2006;32(3):380-90

Jog To Retard Aging

Importance of regular physical activity to the health of an individual is well established. A new study conducted in Brigham Young University in Provo, UT, has uncovered hitherto unknown benefit of vigorous activity. It suggests that highly active persons can slow down the aging process as much as by 9 years. In the study, the researchers obtained data relating to 62 physical activities from 5823 adults and also measured the length of telomeres in each adult. Telomeres are repetitive nucleotide sequences at the end of chromosomes helping to protect the latter from deterioration and from adhering to other chromosomes. With cellular aging, telomere becomes shorter. In this study, it was found that the highly active subjects (30-40 minutes jogging daily, five days a week) had longer telomeres representing a biological age 9 years less than sedentary subjects and 7 years less than moderately active adults. So, only highly active subjects reap the benefit. Even moderate physical activity was ineffective. If you want to slowdown the biological aging, jog regularly!

(<http://www.medicalnewstoday.com/articles/317417.php>)

- Dr. K. Ramesh Rao