

# Original Article

## Subgaleal Drain for Chronic Subdural Hematoma

Karthikeyan KV\*, Siddarth G\*\*, Ramesh VG\*\*\*, Jayendapalan\*\*

\*Senior consultant, \*\*Post Graduate, \*\*\*Senior Consultant and HOD, Dept of Neurosurgery, Chettinad Super Speciality Hospital, Chettinad Academy of Research & Education, Chennai, India



Dr. K.V. Karthikeyan has been working in the Department of Neurosurgery of Chettinad Super Speciality Hospital since 2010 as Senior Consultant Neurosurgeon. He finished his MBBS and MCh Neurosurgery from the Madras Medical College in 2006. He is very well trained in Microneurosurgery and Endoscopic Neurosurgery. He is specialised in Skull base and cerebrovascular surgery with special interest in Paediatric Neurosurgery. He was awarded FMMC in 2010 from the prestigious Madras Medical College.

Corresponding author - [Dr Karthikeyan KV \(surgenn@gmail.com\)](mailto:surgenn@gmail.com)

Chettinad Health City Medical Journal 2017; 6(3): 121 - 127

### Abstract

**Aim :** The aim of the present study is to Evaluate the use of subgaleal drain in the drainage of Chronic Subdural Hematomas(CSDH) and to study the incidence of recollection, infection and other complications in these cases.

**Materials and Methods :** This is a prospective observational study. All the cases of chronic subdural hematomas diagnosed and operated at the Department of Neurosurgery, Chettinad Hospital and Research Institute, Chennai during the 2 year study period were included. All CSDH cases excluding recurrent CSDH and coagulopathies were excluded. Standard 2 burr hole craniotomy and evacuation done with subgaleal drain near posterior burr hole.

**Results :** Thirty three cases of Chronic Subdural Hematoma have been analysed in this prospective observational study. There have been no incidence of recurrence or infection in this series. The incidence of symptomatic pneumocephalus has been very small and did not require any surgical intervention. The rate of complication associated with the use of subgaleal drainage system is better than what is reported in literature with the use of other drain systems.

**Conclusion :** Subgaleal drainage system should be considered as a safe, simple and effective alternate to Subdural, Subperiosteal drainage system in the treatment of Chronic Subdural Hematoma. This is only the third study in available literature for the use of subgaleal closed system drainage for Chronic Subdural Hematoma. However this is only a small study and we plan to continue the study with a larger sample size.

**Key Words:** CSDH, Burr hole, Subgaleal drain.

### Introduction

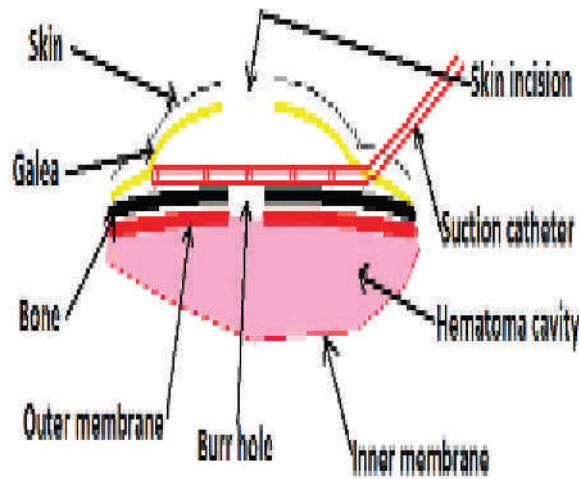
Chronic subdural hematoma (CSDH) is an encapsulated collection of old blood between the duramater and subarachnoid caused by tear of bridging veins. Repeated bleeding from external membrane capillaries facilitated by fibrin degradation products leads to its expansion<sup>1</sup>. Chronic subdural hematoma (CSDH) is one of the common problems seen in Neurosurgical practice, especially in the elderly with incidence ranging between 1.73 to 13.1 per 100,000 population<sup>2</sup>. Known risk factors for CSDH include coagulopathy, alcoholism, trauma and low intracranial pressures for example after lumbar drainage or ventricular peritoneal shunt. Clinical presentation is varied but patient commonly presents with headaches, confusion, drowsiness, vomiting, seizures, ataxia among other presentations and on examination, patient have various neurological deficits including a low Glasgow coma scale, ophthalmoplegia, hemi paresis/hemiplegia among other deficits. Diagnosis is confirmed by non-contrast CT scan head as study of choice although in some instances MRI may be indicated.

Symptomatic CSDH are managed surgically. In surgery the various options available are twist drill drainage, burr hole drainage system and craniotomy. Majority of neurosurgeons use burr hole drainage. Conventional method of drainage is to keep the drain in the subdural space. With a subdural drain, there is always a potential risk of drainage tube coming in contact with the brain causing seizures or hemorrhage due to direct injury and there is increased risk of infection spreading into the intracranial compartment. In subgaleal placement of the drain, with the tip of the drain near the burrhole site subgaleally, the potential complications associated with the placement of subdural drain can be avoided. Only limited experience using the subgaleal drain for treatment of CSDH are available in the literature.

### Aims and Objectives

The aim of the present study is as follows

1. Evaluate the use of subgaleal drain in the drainage of Chronic Subdural Hematomas.
2. Study the incidence of recollection, infection and other complications in these cases



**Fig 1 :** Schematic Representation of Placement of Subgaleal Drain

**Materials and Methods**

This is a prospective observational study. All the cases of CSDH diagnosed and operated at the Department of Neurosurgery, Chettinad Hospital and Research Institute, Chennai, during the 2 year study period were included.

**Case Material**

- Inclusion Criteria
  - All cases of CSDH treated in this hospital
- Exclusion Criteria
  - Recurrent CSDH
  - CSDH secondary to coagulopathies
  - Mass lesions
  - Previous surgery
  - CSDH in children below 18 years of age
- Surgical Procedure
  - Under strict aseptic conditions with patient under General Anaesthesia or Local Anaesthesia with IV sedation, in supine position, with the head turned in the direction opposite to the side of collection of hematoma, Burr hole craniotomy was performed with an anterior and posterior burr hole. Following the drainage of the hematoma, the cavity was filled with normal saline. The anterior burr hole was closed first. The drain was placed subgaleally near the posterior burr hole (Fig 1). The drain was kept in dependent position without vacuum and was removed within 24-48 hours depending upon the volume of the drainage.
- Follow up
  - The patients were observed for the development of post-operative problems like recurrence, infection, symptomatic pneumocephalus. Post-operative imaging (CT scan) was performed after 1 month or earlier if clinical condition warranted. The patients were followed up at intervals of 1 month, 3 months and 6 months post-operatively.
- Assessment Scales used
  - Glasgow Coma Scale
  - Mark Walder scale for Subdural hematoma.

**Statistical Methods**

This is only an observational study and relevant statistical methods using SPSS software were used.

**Observations And Results**

A total of 32 participants were included in the analysis. The various parameters of the analysis are as follows :

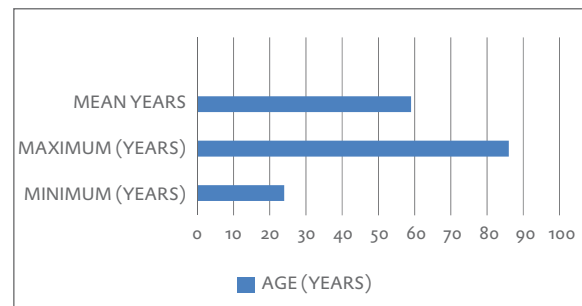
**Age**

The minimum study age of the participants was 24 years and the maximum age was 86 years, with a mean of 59 years (Table 1, Fig 2).

PARAMETER	MINIMUM (YEARS)	MAXIMUM (YEARS)	MEAN (YEARS)
Age	24	86	59

**Table 1 -** Minimum and Maximum age of the subjects Involved in the study with the mean age

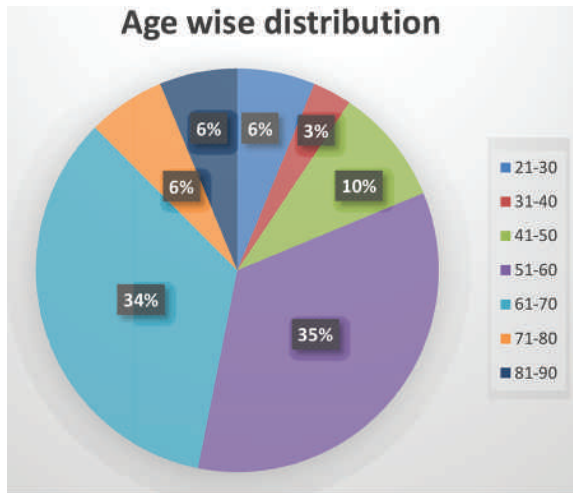
The age distribution of the participants is shown in Table 2 and Fig 3.



**Fig 2 :** Graphical representation of the minimum and maximum age of the subjects involved in the study along with the mean age

AGE GROUP (YEARS)	NO. OF PATIENTS (n)
21-30	2
31-40	1
41-50	3
51-60	11
61-70	11
71-80	2
81-90	2

**Table 2 -** Age group-wise distribution of the subjects involved in the study



**Fig 3 :** Pie Chart representation of subjects in various age groups

### Gender Distribution

Out of 32 study participants, 26 (81.25%) were men and only 6 (18.75%) were women. (Table 3)

GENDER	FREQUENCY	PERCENTAGE (%)
Men	26	81.25
Women	6	18.75

**Table 3 -** Gender distribution of the subjects involved in the study

### Location of Chronic Subdural Hematoma in The Study Population

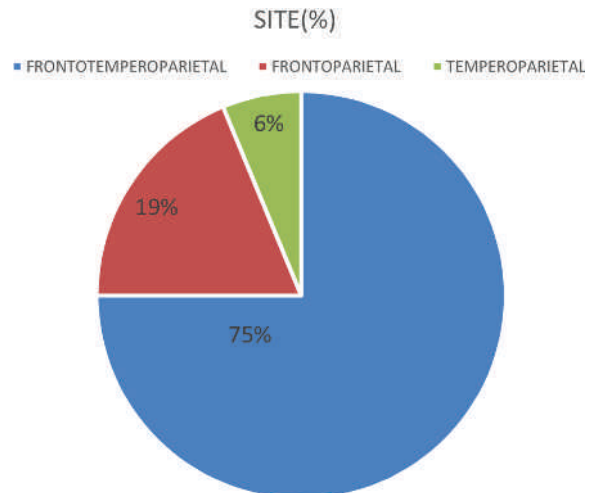
Following is the distribution of the various sites of chronic subdural hematomas in the participants of the study as per CT/MRI Brain. (Table 4, Fig 4)

LOCATION	FREQUENCY	PERCENTAGE (%)
FRONTOTEMPOROPARIETAL	24	75
FRONTOPARIETAL	6	18.75
TEMPOROPARIETAL	2	6.25

**Table 4 -** Frequency and percentage of the site affected by the Chronic Subdural Hematoma in the patients involved in the study

### Side of Chronic Subdural Hematoma in The Study Population

In the study, the most common side of the CSDH was left(50%) followed by right(46.87%) and



**Fig 4 :** Pie Chart showing the areas of the Brain affected by the Chronic Subdural Hematoma in subjects in the study

bilateral(3.12%). Following is the distribution of side of CSDH in the participants of the study as per CT/MRI Brain. (Table 5)

SIDE	FREQUENCY	PERCENTAGE (%)
RIGHT	15	46.87
LEFT	16	50
BILATERAL	1	3.12


**Table 5 -** Frequency and Percentage of the side affected by the Chronic Subdural Hematoma in the Patients Involved In The Study

### Post-Operative Complications

In this study, the participants were evaluated for various immediate post-operative complications such as infection, recollection, symptomatic pneumocephalus (Table 6, Fig 5). Only 2 (6.25%) participants out of a total of 32, developed symptomatic pneumocephalus, which was treated conservatively. No participants in the study had recollection or exhibited any signs of post operative infection.

POST OPERATIVE COMPLICATION	FREQUENCY (n = 32)	PERCENTAGE (%)
INFECTION	0	0
RECOLLECTION	0	0
SYMPTOMATIC PNEUMOCEPHALUS	2	6.25

**Table 6 -** Incidence of various post operative complications in study Group



**Fig 5 :** Bar Diagram depicting the incidence of various post operative complications in The Study Group

### Mark Walder scale assessment at the time of hospital admission

The Mark Walder scale for subdural hematoma was used as one of the assessment scale for the patients of chronic subdural hematoma in this study (Table 7, Fig 6). The scale is as follows:

Grade 0 – No Neurological Deficits

Grade 1 – Patient alert and oriented, mild symptoms such as headache; absent or mild neurological deficits such as reflex asymmetry

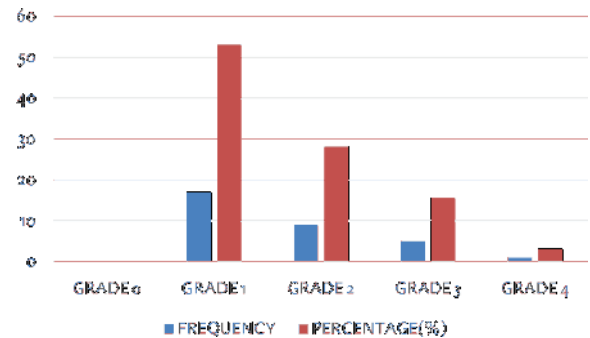
Grade 2 – Patient drowsy or disoriented with various neurological deficits such as hemiparesis

Grade 3 – Patient stuporous but responding appropriately to noxious stimuli; several focal neurological signs like hemiplegia

Grade 4 – Patient comatose with absent motor response to painful stimuli; decerebrate or decorticate posturing

GRADE	FREQUENCY (n=32)	PERCENTAGE (%)
0	0	0
1	17	53.12
2	9	28.12
3	5	15.6
4	1	3.12

**Table 7 -** Mark Walder Scale used for the Neurological Assessment of Patients of Chronic Subdural Hematoma Pre-Operatively



**Fig 6 :** Bar Graph showing the various Mark Walder Grades for Neurological Assessment of Patients of Chronic Subdural Hematoma Pre-Operatively

### Glasgow Coma Scale (GCS) at the time of admission

Glasgow Coma Scale was used as one of the scales for assessment of patients of Chronic Subdural Hematomas in this study (Table 8). The scale is as follows :

Eye Response (E) – Spontaneous (Grade 4), To speech (Grade 3), To pain (Grade 2),

No Response (Grade 1)

Verbal Response (V) – Oriented to time/space and person (Grade 5), Confused (Grade 4)

Inappropriate words (Grade 3), Incomprehensible sound (Grade 2),

No response (Grade 1)

Motor Response (M) – Obeys Commands (Grade 6), Localises to pain (Grade 5),

Flexion Withdrawal From Pain (Grade 4),

Abnormal Flexion – Decorticate (Grade 3),

Abnormal Extension – Decerebrate (Grade 2)

No response (Grade 1)

Best possible score – 15/15

Worst Possible score - 3/15

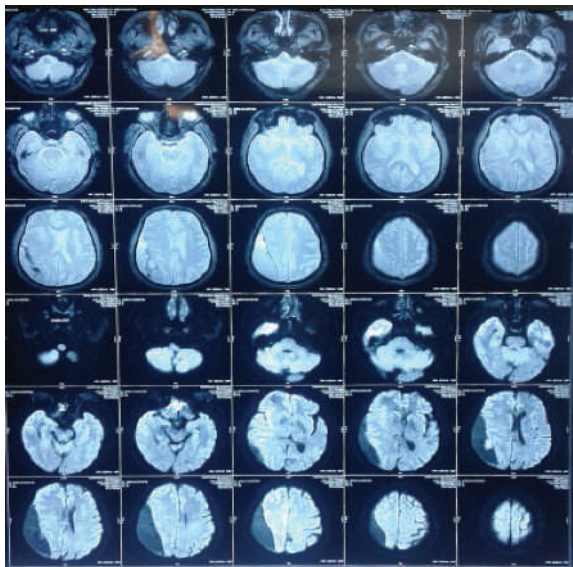
If Tracheally intubated (T) – Best possible score while intubated - 10T/15

Worst Possible Score While Intubated – 2t/15

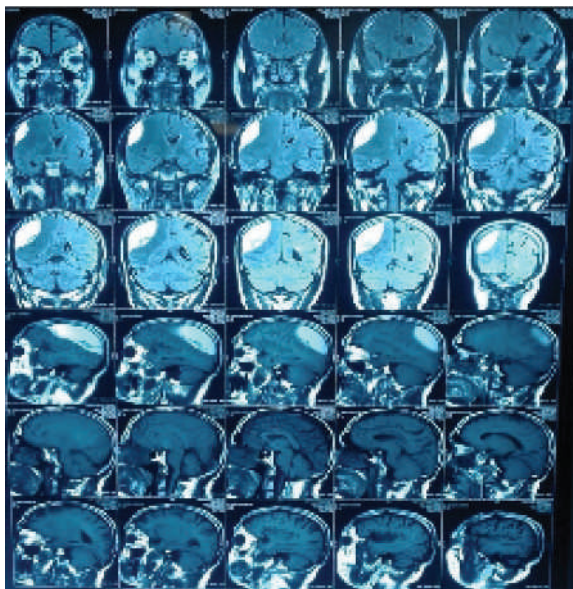
GCS (EVM)	FREQUENCY (n=32)	PERCENTAGE (%)
3-8/15	2	6.25
9-12/15	14	43.75
13-15/15	16	50

**Table 8 -** Glasgow Coma Scale used for the neurological assessment of Patients of Chronic Subdural Hematoma Pre-operatively





**Fig 7 :** MRI Brain (Plain) showing Hypointense Chronic Subdural Hematoma in the Right Parieto-occipital Region



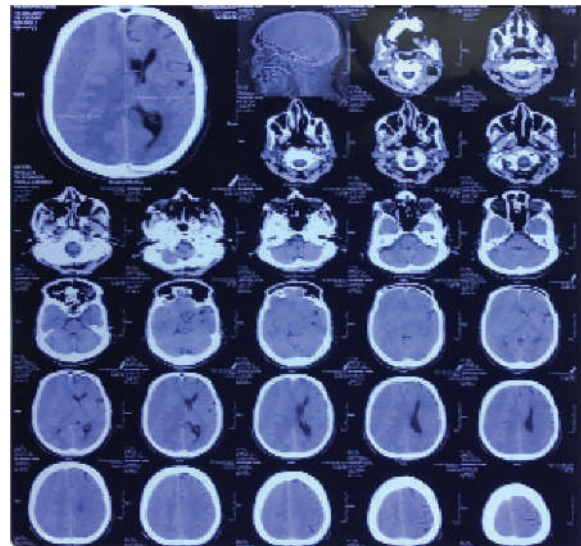
**Fig 8 :** MRI Brain (Coronal and Sagittal Sections) showing Subdural Hematoma in the Right High Parietal Region

## Discussion

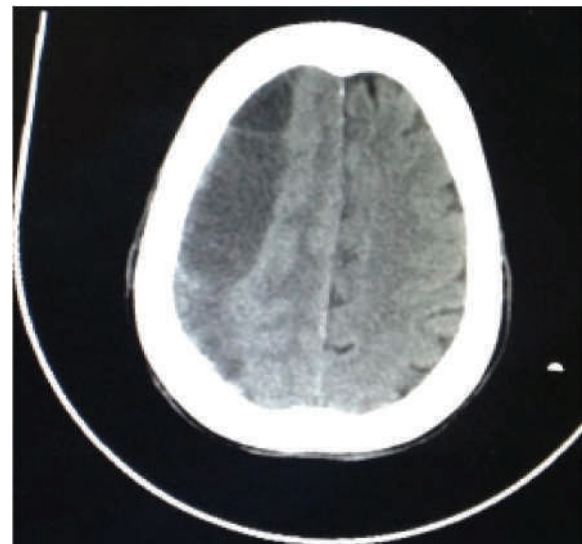
Various methods of drainage of CSDH are present. Burr hole drainage is the commonest method used with other methods being twist drill drainage and craniotomy. Drainage helps in reduction of incidence of re-collection.

Placement of drain can be subdural, subperiosteal or subgaleal. Common type of drain used is subdural drain. The possible problems associated with a subdural drain is direct injury to the cortex producing seizures.

There is considerable evidence in various reported series advocating the use of external drainage after evacuation of CSDH. Santarius et al<sup>3</sup>, Ramchandran



**Fig 9 :** CT Brain (Plain) showing Right Frontotemporal Hypointense Chronic Subdural Hematoma with Partial Effacement of the Ventricles and Mass Effect



**Fig 10 :** CT Brain (Plain) showing Right Frontotemporo-parietal Chronic Subdural Hematoma with Mass Effect and Midline Shift

et al<sup>3</sup>, Wakai et al<sup>4</sup>, Tsutsumi et al<sup>5</sup>, Gurulik et al<sup>6</sup> have reported recurrence rates of 9.3%, 4%, 5%, 3.1% and 10.5% respectively, in the drainage group as compared to the without drain group with recurrence rates of 24%, 30%, 33%, 17% and 19% respectively. However there was no significant difference in post-operative recurrence and complication rates in the above mentioned studies, in the with drain and the without drain groups. Gazerri et al<sup>7</sup> in a study of 224 patients in 2007, reported a recurrence rate of 7.6%. Bellut et al<sup>8</sup>, in a study conducted in 2012, reports a recurrence rate of 1.8% and 3.1% for subgaleal and subdural drain placement respectively. Yu et al reports a recurrence rate of 16.3% and 1.7% in CSDH with drain removal before and after 72 hours respectively<sup>9</sup>.

Santarius et al reported a lower mortality rate of 8.6% in the drain group at the end of 6 month interval, as compared to 18.1% mortality rate in the without drain

group after 6 months<sup>2</sup>. Certain authors, who advocate non usage of drain in the treatment of the CSDH, cite increase risk of post-operative complications such as brain injury, hemorrhage from neo-membranes, infection, without any significant change in the recurrence rates in the with drain and without drain groups.

The sites commonly used for continuous drainage following surgery are subdural, subperiosteal and subgaleal. The subdural and subperiosteal methods of drain placement are highly effective, with the subperiosteal method having a lesser mortality rate and lesser rate of serious complications following surgery, as compared to the subdural method. Subperiosteal closed drainage system is a technically easy, safe and cost-effective treatment strategy for CSDH. The advantage of this procedure is that there is no direct contact of the drain with the hematoma capsule as is in subdural drain placement thereby reducing the risk of post operative seizures and limiting the secondary spread of infection to the intracranial compartments. Various studies such as Bellut et al<sup>8</sup> report lower rates of mortality and post-operative complications with subperiosteal drain than with subdural drain but higher rate of recurrence.

Yadav et al<sup>9</sup> did a prospective study of 260 patients of CSDH with subgaleal method of drain placement and found it to be an effective and safe method with reduced recurrence rates as compared to subdural and sub-periosteal drain placement. It is a relatively simple procedure. Gazzeri et al<sup>7</sup> placed the tip of the suction drain on the burr hole which facilitates continuous drainage of the hematoma or collected air. Yadav et al<sup>10</sup> however, in their study series, positioned the suction tip away from the burr hole site to prevent accidental slippage of the catheter tip into the subdural space. Subgaleal drainage system avoids the risk of acute hemorrhage from a neo-membrane injury, which is sometimes seen with the introduction and subsequent removal of a subdural drain. Chances of brain parenchymal injury, especially after suction drain, are also reduced. Subdural Drain can cause an acute subdural hematoma and intracerebral hematoma formation post-surgery in CSDH patients, due to the blind placement of the drain. This particular complication can be avoided with the placement of a subgaleal drain.

Another serious complication of subdural drain placement is post-operative symptomatic pneumocephalus. It impedes the adhesion of the inner and outer membranes, prolonging the widening of the subdural spaces and hence facilitating re-accumulation in the immediate post-operative period. The placement of a subgaleal suction drain prevents collection of subdural air and hence reduces the risk of recurrence. Other methods by which post-operative pneumocephalus can be prevented are intraoperative saline flushing, supine position of the patient, avoidance of nitrous oxide as an anesthetic agent, introduction of saline in the cavity to facilitate earlier expansion of the cerebrum and placement of burr hole at the highest point. This also reduces the chances of recurrence of CSDH. Post-operative subdural empyema, following subdural drain placement can sometimes be seen. Post-operative infection of the subgaleal space following subgaleal

drain placement, has also been reported, though the incidence is relatively low.

The present study is a prospective observational study designed to document the use of Subgaleal drain system in the management of Chronic Subdural Hematoma and to observe the pros and cons associated with the procedure. The limitations of this study are the relatively small sample of cases and the lack of a without drain control group of Chronic Subdural Hematoma patients, for comparison analysis with the patients in whom the subgaleal drainage system was utilized.

Very few studies documenting the use of subgaleal drain for the treatment of CSDH are available in the literature and there too, the evidence to support the use of subgaleal drain over a subdural or subperiosteal drain is not entirely conclusive. Further studies need to be undertaken to reach a decisive conclusion on the advantage of one drainage system over the other. In the current scenario, the use of subgaleal drain for CSDH provides a viable option for post-operative drainage as opposed to a viable substitute to the use of a subdural or subperiosteal drain.

## Conclusion

Chronic subdural hematoma (CSDH) is one of the common problems seen in Neurosurgical practice. There are many surgical options available including twist drill drainage, burr hole drainage and craniotomy. Majority of neurosurgeons use burr hole drainage. Even in this, there is a controversy whether to use single or two burr holes, whether to use irrigation or not, whether to use drains or not and the type of drain and so on. Only very few studies using the subgaleal drain for treatment of CSDH are available in the literature.

Thirty-three cases of CSDH have been analysed in this prospective observational study over a three year period. The use of Subgaleal drainage system was utilised in all the cases and the various pros and cons of the use the subgaleal drain in the treatment of CSDH were analysed. The following conclusions have been derived from the study

- There have been no incidence of recurrence or infection in this series. The incidence of symptomatic pneumocephalus has been very small and did not require any surgical intervention.
- The use of two burr holes to drain the CSDH with irrigation and subgaleal closed system drainage is a very safe, simple, and effective in the management of CSDH.
- The rate of complication associated with the use of subgaleal drainage system is better than what is reported in literature with the use of subdural and subperiosteal drainage system for the treatment of CSDH.
- Subgaleal drainage system should be considered as a safe, simple and effective alternate to subdural, subperiosteal drainage system in the treatment of CSDH.

This is only the third study in available literature for the use of subgaleal closed system drainage for CSDH.

However this is only a small study and we plan to continue the study with a larger sample size.

## References

- 1) Mohamed EE. Chronic subdural hematoma treated by craniotomy, durectomy, outer membranectomy and subgaleal suction drainage. Personal experience in 39 patients. *Br J Neurosurg.* 2003;17(3):244-7.
- 2) Santarius T, Qureshi HU, Sivakumaran R, Kirkpatrick PJ, Kirillos RW, Hutchinson PJ. The role of external drains and peritoneal conduits in the treatment of recurrent chronic subdural hematoma. *World Neurosurg.* 2010;73(6):747-50.
- 3) Ramachandran R, Hegde T. Chronic subdural hematomas—causes of morbidity and mortality. *Surg Neurol.* 2007;67(4):367-72.
- 4) Wakai S, Hashimoto K, Watanabe N, Inoh S, Ochiai C, Nagai M. Efficacy of closed-system drainage in treating chronic subdural hematoma: A prospective comparative study. *Neurosurgery.* 1990;26(5):771-3.
- 5) Tsutsumi K, Maeda K, Iijima A, Usui M, Okada Y, Kirino T. The relationship of preoperative magnetic resonance imaging findings and closed system drainage in the recurrence of chronic subdural hematoma. *J Neurosurg.* 1997;87(6):870-5.
- 6) Gurelik M, Aslan A, Gurelik B, Ozum U, Karadag O, Kars HZ. A safe and effective method for treatment of chronic subdural hematoma. *Can J Neurol Sci.* 2007;34(1):84-7.
- 7) Gazzeri R, Galarza M, Neroni M, Canova A, Refice GM, Esposito S. Continuous subgaleal suction drainage for the treatment of chronic subdural hematoma. *Acta Neurochir (Wien).* 2007;149(5):487-9.
- 8) Bellut D, Woernle CM, Burkhardt JK, Kockro RA, Bertalanffy H, Krayenbühl N. Subdural drainage versus subperiosteal drainage in burr-hole trepanation for symptomatic chronic subdural hematomas. *World Neurosurg.* 2012;77(1):111-8.
- 9) Yu GJ, Han CZ, Zhang M, Zhuang HT, Jiang YG. Prolonged drainage reduces the recurrence of chronic subdural hematoma. *Br J Neurosurg.* 2009; 23(6):606-11.
- 10) Yadav YR, Parihar V, Chourasia ID, Bajaj J, Namdev H. The role of subgaleal suction drain placement in chronic subdural hematoma evacuation. *Asian J Neurosurg.* 2016;11(3):214-8.

## Answer to : INTERESTING ECG

Her ECG showed Sinus rhythm with an atrial rate of 90 beats /min and ventricular rate of 48 beats /min. In the rhythm strip initial recording showed 2:1 AV block which then converted into Mobitz type II second degree AV block which indicated probable block at infra-nodal level.

### 2: 1 AV block – localizing the site of block

	NODAL	INFRANODAL
QRS	Narrow QRS	Wide QRS
PR INTERVAL	> 200 ms	< 160 ms
ASSOCIATED RHYTHM	Mobitz type I	Mobitz type II
ATROPINE / EXERCISE	Improves conduction	Increases block
CAROTID SINUS MASSAGE	Increases Block	Improves conduction

Patients with symptomatic 20 AV block usually requires Permanent Pacemaker Implantation.

**- Dr.G.Ashok, Consultant Cardiologist, CSSH.**