

# Classroom Article

## Zika Virus-An Emerging Viral Illness and Congenital Zika Virus Syndrome

Pushkar P\*, Rathinasamy M\*\*, Srinivasan K\*\*\*, Giridhar S\*\*\*\*, Satish D\*\*\*\*\*

\*Intern, \*\* Professor, \*\*\* Professor and HOD, \*\*\*\* Associate Professor, \*\*\*\*\* Post Graduate, Department of Neonatology, Chettinad Hospital and Research Institute, Chettinad Academy of Research and Education.



Dr. Pushkar Pazhani is pursuing his internship at Chettinad Hospital & Research Institute.

Corresponding author - : [Pushkar Pazhani \(pazhanipushkar@gmail.com\)](mailto:pazhanipushkar@gmail.com)

Chettinad Health City Medical Journal 2017; 6(1): 35 - 41

### Abstract

Zika viral infection is an emerging viral infectious disease. Most of the cases are asymptomatic, a few may present as a very severe illness, rarely leading to death. The common presentation is a febrile illness with rash, myalgia, arthralgia, conjunctivitis and headache. Congenital Zika virus syndrome produces a wide range of Central Nervous System and ocular abnormalities in newborn. Studies have also suggested a strong association between Zika virus infection and Guillain-Barre' syndrome. Primary route of spread is by the bite of Aedes mosquito and vertical transmission. It can also spread by sexual route and blood transfusion. Diagnosis is by RNA-Nucleic acid testing (RNA-NAT) and RT-PCR. Like other Flaviviral illnesses (Dengue, Yellow fever and Chikungunya), there is no specific treatment for Zika viral illness other than symptomatic treatment. So prevention is the main modality stressed.

**Key Words:** Zika Virus, mode of transmission, clinical features, congenital Zika virus syndrome, Flaviviral infections, diagnosis, prevention.

### Introduction

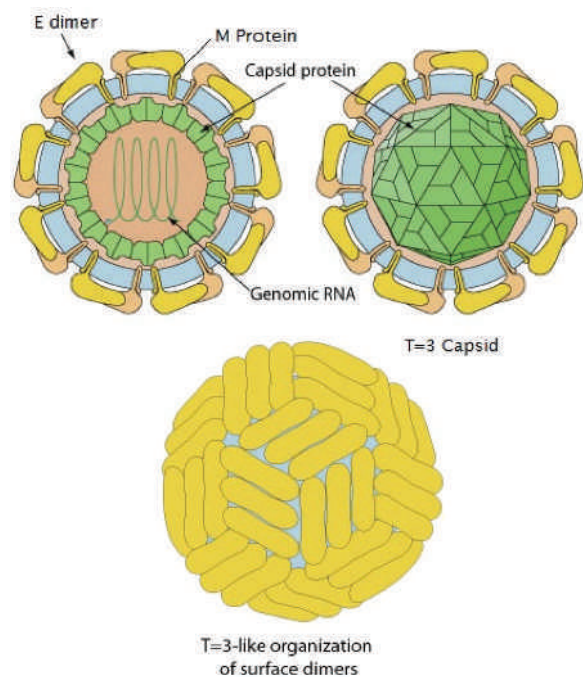
There are several emerging viral and other infectious diseases, one among them being Zika viral disease (ZVD) which has recently come into the limelight because of its association with increased number of cases of microcephaly in babies born to mothers infected with Zika virus during pregnancy in Brazil in 2015. However, Zika virus has been in existence since 1947 and is named after the Ugandan forest where it was first isolated. There have been 4 cases of Zika virus reported in India since 2016, and considering the fact that the vector for Zika virus (*Aedes aegypti* and *Aedes albopictus*) is plentiful in India, it is a ticking time bomb waiting to explode any time into an epidemic. The purpose of this review article is to spread awareness regarding Zika virus infection, clinical features, diagnosis and prevention.

### Biology

Zika virus belongs to the flavivirus family and is similar to dengue virus, yellow fever virus, Japanese encephalitis virus and West Nile virus. It is an enveloped virus with an icosahedral core and single stranded positive sense RNA (Fig 1). Like other flaviviruses, it has a nucleocapsid of 25-30nm diameter, encased by a lipid bilayer which has envelope proteins E and M. The overall virion is 50nm in diameter<sup>1</sup>. There are seven non structural proteins (NS1, NS2A, NS2B, NS3, NS4A, NS4B, NS5) and three structural proteins (envelope protein, pre-membrane protein and capsid protein) which help in attachment.

Phylogenetic analysis has revealed two lineages of Zika virus<sup>2</sup>:

1. Asian strain (further classified into Malaysian and Micronesian strains)
2. African strain (further classified into Nigerian cluster MR766 and prototype cluster isolated in Uganda)



**Fig 1 :** Structure of Zika virus

Source: [www.laboratoryinfo.com](http://www.laboratoryinfo.com)

## Mode of Transmission:

### 1. Mosquito bite<sup>3</sup>

This is the primary mode of spread by *Aedes* (*A. aegypti* and *A. albopictus*). *Aedes* mosquitoes are aggressive feeders and primarily bite during the day time, but can also however bite during the night time. These mosquitoes lay eggs in domestic water collections like coconut shells, pots, flower vases, tyres, etc. *Aedes albopictus* is slowly replacing *Aedes aegypti* in urban areas, and has a longer life span of about 10 weeks.

### 2. Vertical transmission<sup>3</sup>:

Pregnant mother can transfer the virus to the fetus, if infection is acquired during the antenatal as well as during the perinatal period. Though there are no reports of transmission through breast feeding, Zika virus has been isolated in breast milk, and hence there is a risk of transmission through breast feeding. In a study of three Zika virus infected mothers, Zika virus was demonstrated in the breast milk and blood of all three mothers. Of the three newborns, two had confirmed Zika virus infection. Due to the variable incubation period of Zika virus, antepartum and intrapartum transmission could not be ruled out in these cases<sup>4</sup>.

### 3. Sexual transmission<sup>3</sup>:

Few studies have shown the presence of Zika virus in the seminal fluid<sup>5</sup>. Another study has demonstrated prolonged presence of Zika virus RNA in the semen, even 62 days (maximum of 180 days) after the onset of symptoms<sup>6</sup>.

### 4. Blood transfusion<sup>3</sup>:

Though there are no such confirmed cases in USA, multiple reports are there in Brazil. There are two reported cases of transmission of Zika virus by platelet transfusion<sup>7</sup>. Centre for disease control USA have mandated screening for Zika virus in blood donors from August 2016. So far 40 were found to be positive.

### 5. Laboratory and healthcare setting exposure<sup>3</sup>:

Samples from persons with suspected Zika virus infection should be handled with Biosafety level 2 precautions.

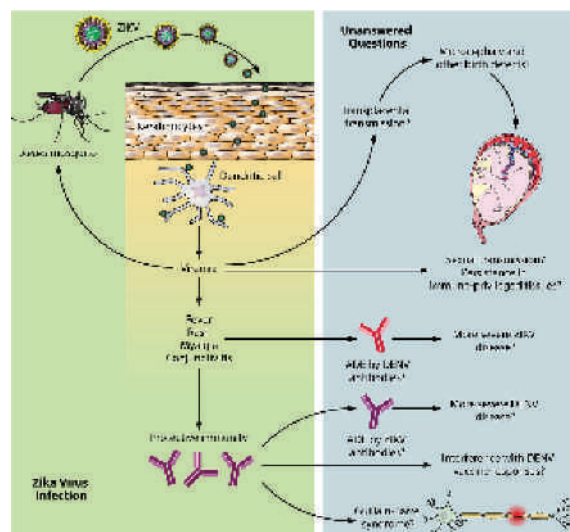
## Clinical Features:

The clinical features are almost indistinguishable from other viral illnesses in the flavivirus group like dengue and chikungunya. However the presentation is mild in most of the cases. Incubation period ranges from three days to two weeks. Most of the cases (80%) are mild or asymptomatic and hence go unnoticed<sup>8</sup>.

### (i) Clinical features are:

- Rash is the most common presentation (82.1%)<sup>9</sup>. It is usually a maculopapular rash involving the facial region and upper limbs (95%), torso (93%), lower limbs (86%). There is also associated itching (82%) which is usually intense. Infrequently the palms (30%) and soles (13%) are involved<sup>10</sup>.

- Febrile illness is seen in 75% of cases<sup>9</sup>. In contrast to other flaviviral illnesses, Zika virus usually causes a mild fever. Rarely, it can cause a high grade fever.
- Arthralgia is seen in 61.9%<sup>9</sup>. This commonly involves the wrist, ankle and the small joints of the hand and foot. Involvement of larger joints like elbow, knee are rare. Unlike Chikungunya, joint pain usually recovers.
- Oedema has been noted in 39.6%<sup>9</sup>.
- Myalgia (32.1%) and back pain (1.5%)<sup>9</sup>.
- Conjunctivitis (50.7%)<sup>9</sup>.
- Headache (24.6%), retro orbital pain (17.1%) and dizziness (4.5%)<sup>9</sup>.
- GIT manifestations<sup>9</sup> noted are Abdominal pain (6%), Vomiting (3.7%), Diarrhea (2.2%).
- Constitutional symptoms such as Fatigue (12.7%), anorexia (3%) has been documented<sup>9</sup>.
- Other less common presentations are Sore throat (3.7%), Cough (1.5%), Lymphadenopathy (5.2%) and Aphthous ulcers (2.2%)<sup>9</sup>.
- Neurological manifestations:
  - Guillain-Barre syndrome: In a study among 42 patients diagnosed to have GBS, 98% had anti-zika virus IgG or IgM. Neurological symptoms started within 6 days from the onset of infection<sup>11</sup>. The short interval between the onset of Zika viral illness and the onset of GBS suggests a parainfectious pattern rather than the classical post infectious pattern<sup>12</sup> (Fig.2). The possible reasons for this is not exactly known, but can be due to<sup>13</sup>:
    - Zika virus triggers an immune molecular mimicry against neural antigens before the onset of clinical symptoms



**Fig 2 : Pathogenesis of Zika Viral Disease**

Source: [www.jvi.asm.org](http://www.jvi.asm.org)

- (b) Through mechanisms unrelated to molecular mimicry
  - (c) Direct viral neural damage/invasion
  - (d) Production of a hyperimmune response
- (ii) Other neuro manifestations are acute myelitis presenting with Hemiparesis and sensory abnormalities (parasthesias), 7 days after onset of infection<sup>14</sup>.
- (iii) Meningo-encephalitis is seen rarely<sup>15</sup>.
- (iv) Auditory disturbances observed are bilateral metallic sound and a small delay between sound and perception of the sound<sup>16</sup>.
12. Rare presentations:
- (i) Prostatic infection presenting as pain over the perineal region, UTI like symptoms and hematospermia<sup>17</sup>.
  - (ii) Bleeding manifestations (Gingival bleeds, hematuria and hematospermia). However the incidence of bleeding is lower compared to Dengue and Chikungunya<sup>18</sup>.
13. Zika Viral Deaths:
- (a) There is a reported case of death following Zika virus infection in a 15 year old girl with sickle cell disease (Hb SC). The patient developed an acute febrile illness with myalgia, arthralgia, retro-orbital pain, abdominal pain and jaundice. She was provisionally diagnosed with Dengue. The patient's condition then deteriorated with deepening of jaundice, ARDS, severe hypoxemia and bleeding diathesis (prolonged PT and aPTT; patient had hemothorax). The patient was positive for Zika virus by RT-PCR<sup>19</sup>.
  - (b) Another case of Zika virus related death was in USA, a 73 year old man being treated for prostatic cancer (otherwise in good health). He then developed a serious febrile illness and passed away soon after. There was history of travel to Mexico one week before the illness. He was found to be positive for Zika virus (same strain as that circulating in Mexico). The man had a previous history of dengue. This could possibly explain the severity of Zika virus disease in this patient (due to antibody-dependent enhancement/ADE)<sup>20</sup>.
  - (c) Another death was reported from Puerto Rico, in a 70 year old man, the cause being immune thrombocytopenic purpura<sup>21</sup>.
14. Some studies have shown cardiovascular manifestations in Zika viral infection in the form of serious rhythm abnormalities (Ventricular arrhythmias, atrial fibrillation and atrial tachycardia) and sometimes even cardiac failure<sup>22</sup>.

From 2016 to 2017 there have been 4 laboratory confirmed cases of Zika virus infection in India. 3 cases were from Ahmedabad, Gujarat<sup>23</sup>. The most recent case was from Krishnagiri district in Tamil Nadu<sup>24</sup>. Since

there is no significant travel history in these cases, the source of infection could probably be due to an already circulating strain of virus in India. The only evidence for the existence of the virus in India is the detection of antibodies against Zika virus, most prevalent in Bharuch district (of the then Bombay state), Gujarat and Nagpur<sup>25</sup>.

**Case 1:** (November 2016) 34 year old female who had delivered a normal child, developed a low grade fever during the post natal period. There was no significant travel history or history of fever during pregnancy.

**Case 2:** (January 2017) During a routine antenatal clinic surveillance at BJ medical college, Gujarat, a sample from a 22 year old female at 37th week of gestation was found to be positive for Zika virus.

**Case 3:** (February 2017) During an acute febrile illness (AFI) surveillance at BJ medical college, Gujarat a sample from a 64 year old male who had complaints of fever for 8 days turned up to be positive for Zika virus.

**Case 4:** (July 2017) The patient was a 27 year old male who complained of fever, headache, redness of eyes, photophobia and photophobia. RT-PCR done in Manipal Centre for Virus Research was positive. Subsequent tests at the National Institute of Virology, Pune found the urine positive for Zika virus.

IMPORTANT DIFFERENCES BETWEEN THE FLAVIVIRAL INFECTIONS<sup>26</sup> (number of plus denotes how common or how severe the particular manifestation is)

- (a) Zika Virus:
  1. Rash: +++
  2. Fever: either absent or mild in nature
  3. Itching: +++
  4. Joint pain: +
  5. Myalgia: +
  6. Conjunctivitis: +++
  7. Headache: +
  8. Bleeding manifestations: Very rare
  9. Shock: Very rare
  10. Leucopenia and/or thrombocytopenia: very rare
  11. Recovery: 4-7 days
  12. **Antenatal and Perinatal infection: Congenital Zika Virus Syndrome**
- (b) Dengue Virus:
  1. Rash: +
  2. Fever: Moderately high fever lasting for 4-7 days
  3. Itching: +
  4. Joint pain: +
  5. Myalgia: ++
  6. Conjunctivitis: Very rare
  7. Headache: ++
  8. Bleeding manifestations: ++
  9. Shock: +/-
  10. Leucopenia and/or thrombocytopenia: +++
  11. Recovery: 6-7 days
  12. Antenatal and Perinatal infection: No fetal anomalies
- (c) Chikungunya:
  1. Rash: ++

2. Fever: High grade lasting for 2-3 days
3. Itching: +
4. Joint pain: +++
5. Myalgia: +
6. Conjunctivitis: +/-
7. Headache: +
8. Bleeding manifestations: +/-
9. Shock: Very rare
10. Leucopenia and/or thrombocytopenia: +
11. Recovery: within 7 days
12. Antenatal and Perinatal infection: No fetal anomalies

## Congenital Zika Virus Syndrome (CZS)

Zika virus can cause a variety of congenital conditions (congenital Zika virus syndrome) when the mother had acquired infection during the antenatal period. Though many of the congenital abnormalities in congenital Zika virus syndrome are also seen in other congenital infections, there are 5 unique manifestations which are characteristic to Congenital Zika virus infection<sup>27</sup>:

- (1) Microcephaly with a partly collapsed skull.
- (2) Cerebral cortex thinning/atrophy with sub cortical calcifications.
- (3) Retinal abnormalities: scarring of macula and pigmentary retinal mottling.
- (4) Basal ganglia involvement presenting as increased muscle tone and other extra pyramidal manifestation
- (5) Congenital contractures and CTEV.

### 1. Cranial Abnormalities<sup>27</sup>

Severe microcephaly is most common. From 19th May, 2016 there have been 1384 confirmed and 3332 suspected microcephaly cases caused due to Zika virus in Brazil and 88545 suspected and 31616 confirmed Zika virus infections, suggesting the rate of microcephaly to the total number of Zika virus infected cases to be around 1%-4%. Other anomalies seen are Cranio facial disproportion (95.8%), Biparietal depression (83.3%), Prominent occiput (75%). Excess nuchal skin in 47.9% of cases<sup>28</sup>. Zika virus is also associated with fetal brain disruption sequence (FBDS), where there is collapse of the cranial bones secondary to decreased brain volume and intra cranial pressure. Though FBDS is not exclusive to Zika virus, it has rarely been seen before<sup>29</sup>. CNS abnormalities noted are Cerebral cortex thinning Enlarged ventricles and Intracranial calcification<sup>30</sup>. The intracranial calcifications are strikingly similar to that seen in congenital cytomegalovirus (CMV) infection. However, the location of the calcifications in both differ. It is periventricular in CMV and subcortical in Congenital Zika virus infection. Corpus callosum abnormalities, Cerebellar abnormalities (especially involving the vermal region) also have been observed<sup>31</sup>.

### 2. Ocular Anomalies<sup>29</sup>

- Microphthalmia
- Cataract
- Coloboma
- Chorioretinal atrophy
- Focal pigmentary mottling
- Optic nerve hypoplasia/atrophy

### 3. Congenital Contractures

May manifest as Congenital talipes equinovarus or arthrogryposis multiplex congenital. 3 large case series describing microcephaly due to congenital Zika virus syndrome have shown incidence of isolated club foot to be 3.8-14% and arthrogryposis to be 5.7-11%<sup>29</sup>.

### 4. Neurological Sequelae Observed are:<sup>29</sup>

- Motor dysfunction
- Cognitive disabilities
- Extraparamidal manifestations: Increased muscle tone, tremors, irritability, posturing<sup>32</sup>.
- Seizures
- Visual and/or hearing defects.

## Diagnosis<sup>33</sup>

1. RNA-NAT (nucleic acid testing)-Confirmatory test:
  - This should be done on serum/urine sample within the first 14 days of symptom onset.
  - Though a positive result is almost confirmatory of Zika virus infection, a negative result does not rule out infection and serum should be subjected to serological testing (IgM antibody testing).
2. RT-PCR
  - Though the FDA has not approved this test, it has authorized its use under an Emergency use authorization (EUA).
3. Zika MAC ELISA
  - This is used to detect IgM antibodies in the serum.
  - However this test is not specific due to cross reaction with other flaviviruses like dengue and chikungunya.
4. Diagnosis of congenital Zika virus infection<sup>34</sup>

Laboratory testing for congenital Zika virus infection is recommended in cases where Zika virus infection is suspected in the mother. rRT-PCR testing is done on the serum and urine of the infant, and IgM antibodies should be concurrently tested on serum by IgM ELISA. Testing should be done within a period of 2 days. If CSF sample is available, rt-PCR and IgM ELISA tests can be performed on the CSF sample. Testing on cord blood sample is not desirable as the sample might be contaminated with maternal blood, yielding false positive results. A positive rt-PCR test for Zika virus is more predictive than a positive IgM ELISA test. Infants diagnosed with congenital Zika virus infection should be assessed periodically for the development of ocular, auditory, cognitive, behavioural and musculoskeletal problems and treated accordingly.

## Prevention

1. Control of mosquitos:
 

Antilarval measures:

  - a) Environmental control: Elimination of mosquito breeding places/source reduction such as elimination of domestic/artificial collections of water.

b) Chemical methods<sup>35</sup>:  
Larvicides used: Bacterial larvicides (*Bacillus thuringiensis israelensis*), Chlorpyrifos, Fenthion, Temephos.

c) Biological control<sup>36</sup>:  
The use of larvivorous fish like: *Gambusia*, *Lebistes*, *Aphanius*, *Danio*, *Rasbora*, *Anabas*, etc.

#### Anti-Adult measures<sup>35</sup>:

a) Residual sprays:  
Indoor residual spraying (IRS): Long acting insecticides are sprayed on the walls and roofs of houses to kill mosquitos that rest on these surfaces.

Insecticides used: DDT, Malathion, Fenitrothion, Propoxur, Pirimiphos-methyl, Bendiocarb

b) Space spraying:

The usual recommendation for space spraying is in cases of emergency like an epidemic or an impending epidemic. The aim of space spraying is a quick and mass destruction of the adult mosquito population to reduce the intensity of transmission.

Insecticides used: Deltamethrin (ultra low volume liquid/emulsion), Lambda-cyhalothrin (emulsifiable concentrate), Malathion (emulsion and ultra low volume liquid)

c) Long-lasting insecticidal nets<sup>35</sup>:  
DawaPlus 2.0 (Deltamethrin coated on polyester), Duranet (Alpha-cypermethrin incorporated into polyethylene), Olyset Net (Permethrin incorporated into polyethylene)

#### 2. Prevention of sexual transmission for those traveling to an area with risk of Zika virus<sup>37</sup>:

a) Only the male partner travelling to an area with risk of Zikavirus: Sexual abstinence or use of condoms for a period not less than 6 months, irrespective of whether the person has symptoms of Zika viral disease or not.

b) Only the female partner travels to an area with risk of Zika virus: Sexual abstinence or use of condoms for a period not less than 8 weeks, irrespective of whether the person has symptoms of Zika viral disease or not.

c) If both the male and female partner travel to an area of risk of Zika virus: Sexual abstinence or use of condoms for a period not less than 6 months, irrespective of the whether either of them have symptoms or not.

#### 3. Prevention of transmission through blood products<sup>38</sup>:

As per FDA recommendations, blood donors should be considered ineligible if they have any of the following risk factors:

a) Medical diagnosis of Zika virus infection in the past 6 months.

b) Residence in, or travel to, an area with active Zika virus transmission within the past 6 months.

c) Sex within the past 6 months with a male who is known to have either one of the above risk factors mentioned above.

If blood products are to be transfused, testing for Zika virus must be done when the blood product is being used for pregnant women, to prevent CZS.

4. Vaccine: Zika virus vaccine is under development. Animal studies have shown very promising results (almost 100% efficacy)<sup>39</sup>. Currently human trials are being conducted.

### Treatment<sup>40</sup>

Like other viral illnesses like dengue and chikungunya, there is no specific treatment for Zika viral disease. Treatment is mainly symptomatic:

Plenty of oral fluids to avoid dehydration

Bed rest

Paracetamol is the preferred drug of choice for reduced fever and pain since other NSAIDs have a risk of precipitating bleeding (unless dengue is ruled out)

### Conclusion

Zika viral disease is an emerging viral disease that has the potential to increase in number in the coming years. Since 4 cases have already been reported in India, and the vector *Aedes aegypti* is in abundance, Zika virus should be considered in the differential diagnosis of viral illness. Samples negative for Dengue and Chikungunya in suspected Zika viral illness should be sent for further analysis for detecting Zika virus in order to assess the true magnitude of the disease in the country. A large percentage of the infections are asymptomatic, however severe disease and very rarely death have been reported. Congenital Zika viral disease can cause a wide spectrum of fetal anomalies. The virus can be transmitted by routes other than mosquito bites and vertical transmission, like sexual transmission and blood transfusion. Since treatment is mainly symptomatic, prevention is of prime importance.

### References

- 1) Barreto-Vieira DF, Barth OM, da Silva MAN, Santos CC, da Silva AS, Filho JBF, et al. Ultrastructure of Zika virus particles in cell cultures. *Mem Inst Oswaldo Cruz*. 2016;111(8):532-34
- 2) Faye O, Freire CC, Lamarino A, Faye O, de Oliveira JV, Diallo M, et al. Molecular evolution of Zika virus during its emergence in the 20th century. *PLoS Negl Trop Dis* 2014; 8(1); 2636-40.
- 3) <http://www.cdc.gov/zika/index.html>.

- 4) Colt S, Garcia-Casal MN, Pena-Rosas JP, Finkelstein JL, Rayco-Solon P, Prinzo ZC, et al. Transmission of Zika virus through breast milk and other breastfeeding-related bodily-fluids: A systematic review. *PLoS Negl Trop Dis*. 2017; 11(4): e0005528.
- 5) Mansuy JM, Dutertre M, Mengelle C, Fourcade C, Marchou B, Delobel P, et al. Zika virus: high infectious viral load in semen, a new sexually transmitted pathogen? *Lancet Infect Dis*. 2016; 16(4):405.
- 6) Atkinson B, Hearn P, Afrough B, Lumley S, Carter D, Aarons EJ, et al. Detection of Zika virus in semen. *Emerg Infect Dis*. 2016;22(5):940
- 7) Motta IJ, Spencer BR, Cordeiro da Silva SG, Arruda MB, Dobbin JA, Gonzaga YB, et al. Evidence of Transmission of Zika Virus by Platelet Transfusion. *N Engl J Med*. 2016; 375(11):1101-3
- 8) Petersen E, Wilson ME, Touch S, McCloskey B, Mwaba P, Bates M, et al. Rapid spread of Zika virus in The Americas- Implications for Public Health Preparedness for Mass Gatherings at the 2016 Brazil Olympic Games. *Int J Infect Dis*. 2016 ;44:11-5
- 9) Salehuddin AR, Haslan H, Mamikutty N, Zaidun NH, Azmi MF, Senin MM, et al. Zika virus infection and its emerging trends in Southeast Asia. *Asian Pac J of Trop Med* 2017; 10(3): 211-9.
- 10) Cordel N, Birembaux X, Chaumont H, Delion F, Chosidow O, Tressières B, et al. Main characteristics of Zika virus exanthema in Guadeloupe. *JAMA Dermatol*. 2017; 153(4):326-8
- 11) Cao-Lormeau VM, Blake A, Mons S, Lastere S, Roche C, Vanhomwegen J, et al. Guillain-Barre syndrome outbreak associated with Zika virus infection in French Polynesia: a case-control study. *Lancet*. 2016; 387(10027) 1531-9.
- 12) Pinto-Díaz CA, Rodríguez Y, Monsalve DM, Acosta-Ampudia Y, Molano-González N, Anaya JM, et al. Autoimmunity in Guillain-Barre syndrome associated with Zika virus infection and beyond. *Autoimmun Rev*. 2017; 16(4): 327-34
- 13) Parra B, Lizarazo J, Jiménez-Arango JA, Zea-Vera AF, González-Manrique G, Vargas J, et al. Guillain-Barre Syndrome Associated with Zika Virus Infection in Columbia. *N Eng J Med*. 2016; 375(16):1513-23
- 14) Mecharles S, Herrmann C, Poullain P, Tran TH, Deschamps N, Mathon G, et al. Acute myelitis due to Zika virus infection. *Lancet*. 2016; 387(10026): 1481.
- 15) Carreaux G, Maquart M, Bedet A, Contou D, Brugieres P, Fourati S, et al. Zika virus associated with meningoencephalitis. *New Eng J Med*. 2016; 374(16): 1595-6.
- 16) Tappe D, Nachtigall S, Kapaun A, Schnitzler P, Gunther S, Schmidt-Chanasit J. Acute Zika virus infection after travel to Malaysian Borneo, Setember 2014. *Emerg Infect Dis*. 2015; 21(5): 911-3.
- 17) Foy BD, Kobylinski KC, Chilson Foy JL, Blitvich BJ, Travassos da Rosa A, Haddock AD, et al. Probable non-vector-borne transmission of Zika virus, Colorado, USA. *Emerg Infect Dis*. 2011;17(5): 880-2.
- 18) Olson JG, Ksiazek TG. Zika virus, a cause of fever in Central Java, Indonesia. *Trans R Soc Trop Med Hyg*. 1981; 75(3): 389-93.
- 19) Arzuza-Ortega L, Polo A, Perez-Tatis G, Lopez-Garcia H, Parra E, Pardo-Herrera LC, et al. Fatal sickle cell disease and Zika virus infection in girl from Colombia. *Emerg Infect Dis* .2016; 22(5): 925.
- 20) <https://www.statnews.com/2016/09/28/zika-death/>
- 21) <https://mobile.nytimes.com/2016/04/30/health/zika-virus-first-death-in-us-puerto-rico.html>
- 22) <http://www.acc.org/about-acc/press-releases/2017/03/09/13/25/researchers-sound-alarm-over-zikas-potentially-harmful-heart-effects>
- 23) <http://www.who.int/csr/don/26-may-2017-zika-ind/en/>.
- 24) <http://www.thehindu.com/news/national/tamil-nadu/tamil-nadu-reports-first-case-of-zika-virus/article19254690.ece/amp/>
- 25) Mourya DT, Shil P, Sapkal GN, Yadav PD. Zika virus: Indian perspectives. *Indian J Med Res*. 2016; 143(5):553-64
- 26) <http://zika-virus.net/signs-a-symptoms.html>
- 27) Moore CA, Staples JE, Dobyns WB, Pessoa A, Ventura CV, Fonseca EB, et al. Characterizing the Pattern of Anomalies in Congenital Zika Syndrome for Pediatric Clinicians. *JAMA Pediatr*. 2017;171(3): 288-95.
- 28) Moura da Silva AA, Ganz JS, Sousa PD, Doriqui MJ, Ribeiro MR, Branco MD, et al. Early growth and neurological outcomes of infants with probable congenital Zika virus syndrome. *Emerg Infect Disease*. 2016 Nov;22(11):1953-6.
- 29) Corona-Rivera JR, Corona-Rivera E, Romero-Velarde E, Hernandez-Rocha J, Bobadilla-Morales L, Corona-Rivera A. Report and review of fetal brain disruption sequence. *Eur J Pediatr*. 2001;160(11):664-7.

- 30) Solomon IH, Milner DA, Folkerth RD. Neuro-pathology of Zika Virus. *J Neuroinfect Dis.* 2016; 7(2):220.
- 31) Averill LW, Kandula VV, Akyol Y, Epelman M. Fetal brain magnetic resonance imaging findings in congenital cytomegalovirus infection with postnatal imaging correlation. *Semin Ultrasound CT MR.* 2015;36(6):476-86.
- 32) Schuler-Faccini L, Ribeiro EM, Feitosa IM, Horovitz DG, Cavalcanti DP, Pessoa A, et al; Brazilian Medical Genetics Society-Zika Embryopathy Task Force. Possible association between Zika virus infection and microcephaly: Brazil, 2015. *MMWR Morb Mortal Wkly Rep.* 2016;65(3):59-62.
- 33) <https://www.cdc.gov/zika/hc-providers/types-of-tests.html>
- 34) <https://www.cdc.gov/mmwr>
- 35) <https://www.who.int/whopes/en/>
- 36) Chandra G, Bhattacharjee I, Chatterjee SN, Ghosh A. Mosquito control by larvivorous fish. *Indian J Med Res.* 2008;127(1): 13-27
- 37) <https://www.cdc.gov/zika/prevention/index.html>
- 38) <http://www.fda.gov/BiologicsBloodVaccines/GuidanceComplianceRegulatoryInformation/Guidances/default.html>
- 39) Sumathy K, Kulkarni B, Gondu RK, Ponnuru SK, Bonguram N, Eligeti R, et al. Protective efficacy of Zika vaccine in AG129 mouse model. *Sci Rep.* 2017; 7: 46375.
- 40) <https://www.cdc.gov/zika/symptoms/treatment.html>