

# Case Report

## Sickle Beta<sup>+</sup> Thalassemia

Jegan Niwas K\*, Ramcharan Reddy\*\*, Udayashankar D\*\*\*, Durga Krishnan\*\*\*, Rajasekaran D\*\*\*\*

\*Assistant Professor, \*\*Post Graduate Student, \*\*\*Associate Professor, \*\*\*\*Professor & HOD, General Medicine, Chettinad Hospital and Research Institute, Chennai, India.



Dr. Jegan Niwas K graduated from Thanjavur Medical College, Thanjavur and completed his postgraduation from the prestigious Madras Medical College, Chennai. He is presently working as an Assistant Professor in the Department of General Medicine, CHRI. His fields of interest are Haematology and Endocrinology.

Dr. Ramcharan Reddy is Final year MD Post Graduate student in General Medicine, CHRI. His fields of interest include Nephrology and Infectious diseases.



Both the authors \* & \*\* have contributed equally to the article.

Corresponding author - Jegan Niwas K (docjegan@hotmail.com)

### Abstract

Sickle beta thalassemia is a disorder which represents the double heterozygous state for the Hb-S and the beta-thalassemia genes. The clinical and hematological manifestations of sickle beta thalassemia are highly variable due to existence of two types of genes, beta<sup>0</sup> thalassemia gene and beta<sup>+</sup> gene. Beta<sup>0</sup> gene leads to complete absence of Hb-A levels, whereas beta<sup>+</sup> gene leads to production of Hb-A levels 10-30%. This disorder is diagnosed by levels of Hb-S, Hb-A<sub>2</sub> and Hb-F in Hemoglobin Electrophoresis. We are presenting one such patient with features of Sickle Beta<sup>+</sup> thalassemia who presented with anemia, splenomegaly and characteristic features in Hb Electrophoresis.

**Key Words:** Sickle Cell Anemia, Beta Thalassemia, Hb Electrophoresis, Hemoglobin A, Hemoglobin S

Chettinad Health City Medical Journal 2014; 3(3): 133 - 135

### Introduction

Hemoglobinopathies are a group of genetic disorders of hemoglobin in which there is abnormal production or structure of the hemoglobin molecule. These hereditary disorders are major public health problem in many parts of the world including India. The clinical spectrum of the disorders varies from asymptomatic conditions to serious disorders like thalassemia major that requires regular blood transfusions and extensive medical care.

As per World Health Organization (WHO) report, around 7% of the global population carries an abnormal haemoglobin gene<sup>1</sup>.

Population screening has identified the prevalence of - thalassemia carrier status as high as 17% in certain communities in India<sup>2</sup>. The prevalence of hemoglobinopathies varies in different parts of India. Sickle beta thalassemia prevalence was found to be relatively low in contrast to the prevalence of beta thalassemia trait in various studies<sup>3-9</sup>. Sickle beta thalassemia is a disorder which represents the double heterozygous state for the Hb-S and the beta thalassemia genes.

The overall prevalence of sickle beta thalassemia in India is 0.02% with highest prevalence in Bangalore (0.06%). The overall prevalence of beta-thalassemia trait in India is (2.78%) with highest prevalence in Kolkata (3.64%). The overall prevalence of HbS trait in India is 0.70% with highest prevalence in Vadadora (2.94%). The overall prevalence of HbE trait in India is 3.63% with highest prevalence of 23.9% in Dibrugarh<sup>3</sup>. This case is presented due to uncommon occurrence of sickle beta<sup>+</sup> thalassemia.

The clinical and haematological manifestations of sickle beta thalassemia are highly variable. Variability is due to existence of two types, one characterised by complete absence of Hb-A due to the presence of a beta<sup>0</sup> thalassemia gene and the other with Hb-A levels of 10-30% due to a beta<sup>+</sup> gene. This disorder is diagnosed by the levels of HbS, HbA<sub>2</sub> and HbF levels in Haemoglobin Electrophoresis, Peripheral smear, and Reticulocyte count.

### Case report

A 23 year old man from Kolkata, West Bengal presented with acute onset of intermittent fever with chills, rigor and vague abdominal fullness of 2 days duration. He did not have any other symptoms suggestive of cardiac, respiratory and haematological disorders. He takes mixed diet and has no significant family or personal history.

On examination he was conscious, oriented, and mildly icteric with mild pallor. He had a single axillary, non tender lymph node of size 1.5x1cm. His abdominal examination revealed moderately firm splenomegaly (7cms). Other systems examinations were unremarkable.

His complete blood count revealed anaemia Hb 8.6 gm%, RBCs 3.5 million/cubic mm, MCV 77.3 fl, with normal Total count, and marginally low platelets (83,000) with ESR 13mm/hr. Peripheral smear showed microcytic hypochromic RBCs with target cells with elliptocytes, fragmented RBCs with polychromatic cells with no heamoparasites. Reticulocyte count was 3%.

His biochemical investigations showed mild haemolysis with Total Bilirubin 2.93 mg/dl (Indirect bilirubin-2.80mg/dl), Lactate dehydrogenase (LDH)-1387 IU with normal liver function tests and Urine Urobilinogen were normal.

Serological tests like Coombs direct and indirect, ELISA for HIV and Dengue were negative. FNAC of the node showed a reactive infiltrate. Serum ferritin was 191.6ng/ml. Bone marrow biopsy study showed erythroid hyperplasia with mild megaloblastic changes and dyserythropoiesis. Iron stores were increased.

In view of anemia and splenomegaly and raised LDH, negative coomb's test and in the absence of hemoparasites, patient was investigated further to find the cause for hemolysis and hence sickling test was ordered. Sickling test came positive with Hb electrophoresis revealing HbS 72.8%, HbA level 4.6%, HbA<sub>2</sub> 5.2%, HbF- 15.3%, suggestive of a hemoglobinopathy.

## Discussion & Conclusion

Differentiation of sickle cell anaemia and some of the sickle beta thalassemia syndromes has to be done carefully due to close similarity of symptoms and laboratory features. Mean corpuscular volume (MCV) may be normal or low in all thalassemia syndromes.

Symptoms and blood picture of patients with HbS beta<sup>0</sup> thalassemia are similar to those of homozygous sickle cell disease (HbSS) with microcytosis, marked hypochromia, target cells and sickle cells in the peripheral smear and can be differentiated only by Hb electrophoresis.

The Haemoglobin Electrophoresis pattern of the sickle-beta<sup>0</sup> thalassemia consists almost totally of Hb-S with a mild increase in Hb-F and Hb-A<sub>2</sub> and absent Hb-A<sup>10</sup>. They also have similar symptoms of homozygous sickle cell disease like frequent painful vasoocclusive crises, hand-foot syndrome and aseptic necrosis of bone with autosplenectomy.

The beta<sup>+</sup> thalassemia type consists of Hb-S, along with 10-30% of Hb-A and a mild increase in Hb-F and Hb-A<sub>2</sub>. Patients with HbS beta<sup>+</sup> thalassemia are characterized by mild anemia associated with moderate splenomegaly, in contrast to autosplenectomy of sickle cell anemia<sup>11</sup>.

Sickle beta<sup>+</sup> thalassemia patients have Hb-S composition of approximately 60-70%, Hb-A 25%, and an elevated level of Hb-A<sub>2</sub><sup>12</sup>. They also can have few symptoms like occasional vasoocclusive crises and aseptic necrosis of the bone.

Patients with HbS-HPFH (HbS & Hereditary Persistence of Fetal Hemoglobin) are asymptomatic and not anemic.

HbA<sub>2</sub> levels are elevated above 3.5% in HbS beta thalassemia and are low or normal in patients with HbS-HPFH. HbF level in patients with HPFH are generally more than 20%<sup>13</sup>.

Thus a careful evaluation of symptoms and signs along with Hb electrophoresis helps us to distinguish between various sickle beta thalassemia syndromes.

## References

- 1) WHO. Management of Haemoglobin Disorders. Report of Joint WHO-TIF Meeting on the Management of Haemoglobin Disorders. Nicosia, Cyprus, 16-18 November 2007. World Health Organization 2008: 1-2. Available from: [http://www.who.int/genomics/WHO\\_TIF\\_genetics](http://www.who.int/genomics/WHO_TIF_genetics).
- 2) Vaz FE, Thakur CB, Banerjee MK, Gangal SG. Distribution of beta-Thalassemia Mutations in the Indian Population Referred to a Diagnostic Center. *Hemoglobin* 2000;24:181-94 [PUBMED]
- 3) D. Mohanty, R. B. Colah, A. C. Gorakshakar, R. Z. Patel, et al., Prevalence of  $\beta$ -thalassemia and other haemoglobinopathies in six cities in India: a multicentre study. *J Community Genet.* Jan 2013; 4(1): 33-42.
- 4) Jain BB, Roy RN, Ghosh S, Ghosh T, Banerjee U, Bhattacharya SK. Screening for thalassemia and other hemoglobinopathies in a tertiary care hospital of West Bengal: Implications for population screening. *Indian J Public Health* 2012;56:297-300
- 5) Balgir RS. Spectrum of hemoglobinopathies in the state of Orissa, India: A ten years cohort study. *JAPI.* 2005;53:1021-1026.
- 6) Chatterjee N, Mishra A, Soni R, Kulkarni H, Mantani M, Shrivastava M. Bayesian estimates of the prevalence of  $\beta$ -thalassemia trait in voluntary blood donors of central India: a survey. *Hemoglobin.* 2010;34:548-560. Doi: 10.3109/03630269.2010.526488.
- 7) Chhotray GP, Dash BP, Ranjit M. Spectrum of hemoglobinopathies in Orissa, India. *Hemoglobin.* 2004;28:117-122. Doi: 10.1081/HEM-120034244.
- 8) Colah R, Thomas M, Mayekar P. Assessing the impact of screening & counseling high school children for beta thalassemia in India. *J Med Screen.* 2007;14:158. Doi: 10.1258/096914107782066202.
- 9) Madan N, Sharma S, Sood S K, Colah R, Bhatia H M. Frequency of  $\beta$ -thalassemia trait and other hemoglobinopathies in northern and western India. *Indian J Hum Genet* 2010;16:16-25
- 10) Frank Firkin, Disorders of Haemoglobin structure and Synthesis, De Gruchy's Clinical Haematology in Medical Practice, 5th edition: pages 140-151, Blackwell Science Ltd., France.
- 11) Winfred C.Wang, Sickle Cell Anemia and other Sickling Syndromes, Wintrobe's Clinical Haematology, 11th edition: pages 1294-1295,

Philadelphia. Lippincott Williams & Wilkins.

- 12) David J Weatherall, The Thalassemias, William's textbook of haematology 7th edition pages 698-99, McGraw Hill Companies.
- 13) Angastiniotis M, Eleftheriou A, Galenello Ret al., Prevention of Thalassemia and other Haemoglobin Disorders: Volume 1: 2nd edition: Thalassemia International Federation; 2013.

### Answer to : **Diagnose the condition**

ECG 2 -shows Wellens syndrome also referred to as LAD coronary T-wave syndrome. Rhinehart et al (2002) describe the following diagnostic criteria for Wellens' syndrome:

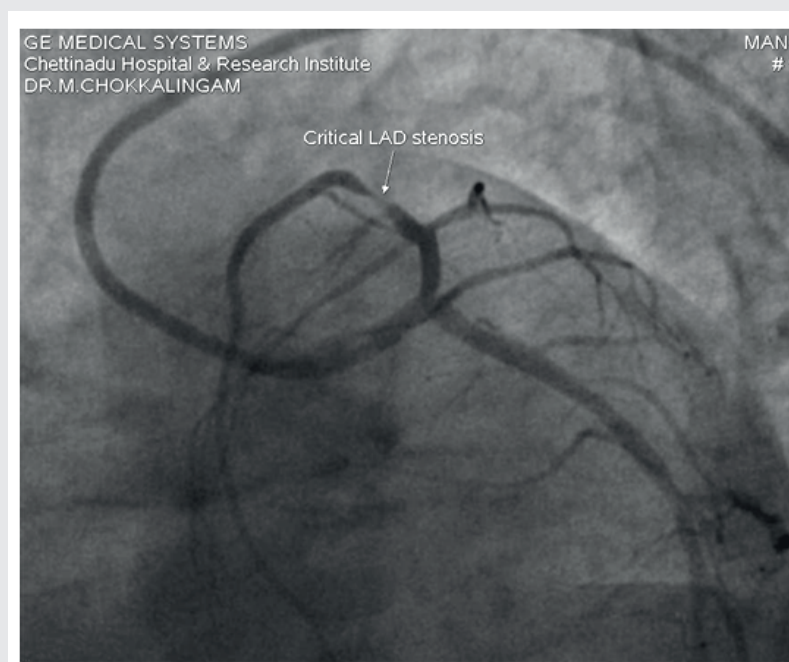
- Deeply-inverted or biphasic T waves in V2-3 (may extend to V1-6)
- Isoelectric or minimally-elevated ST segment (< 1mm)
- No precordial Q waves
- Preserved precordial R wave progression
- Recent history of angina
- ECG pattern present in pain-free state
- Normal or slightly elevated serum cardiac markers

Recognition of this ECG abnormality is of paramount importance because this syndrome represents a preinfarction stage of coronary artery disease (CAD) that often progresses to a devastating anterior wall MI.

Associated with critical stenosis of the proximal left anterior descending (LAD) coronary artery.

Our patient had 99% stenosis of LAD for which he underwent successful PTCA with stenting to LAD.

Prompt identification is important as it prevents major acute MI.



- **Dr.M.Chokkalingam**, Consultant Cardiology, CSSH.