

Case Report

Dumb Bell Skull Base Meningioma

Dr. K.V.Karthikeyan*, Dr.V.G.Ramesh**

* Consultant Neurosurgeon, **Prof. and Chief Consultant Neurosurgeon, Dept. of Neurosciences, Chettinad Super Speciality Hospital, Chennai, India.



Dr.K.V.Karthikeyan is currently working as Consultant Neurosurgeon at Chettinad Super Speciality Hospital. He completed his graduation in 2001 from the prestigious Madras Medical college and completed his MCH (Neurosurgery -5 yrs) from the Madras Institute of Neurology at Madras Medical college in 2007. He is very well trained in Micro neurosurgery and vascular neurosurgery. He joined our institute in 2010. He has special interest in Vascular Neurosurgery and Endoscopic Neurosurgery.

Corresponding author - Dr.K.V.Karthikeyan (surgenn@gmail.com)

Chettinad Health City Medical Journal 2014; 2(2): 60 - 62

Abstract

Meningiomas are the most commonly occurring benign tumors of the brain. Meningiomas occurring in the base of the skull account for 10 % of them. Microsurgical excision of meningiomas in skull base is technically demanding because of the close association of the major blood vessels and vital brain areas. Here we present an interesting skull base meningioma which has a dumbbell component.

Key words : Meningioma-Dumb bell- Dura-skull base

Case Report

A 38 yr old female patient presented with progressively increasing left sided headache associated with occasional vomiting for the past 6 months duration. On examination patient was conscious oriented and she had early papilloedema. No other neurological deficit. MRI of the brain with contrast showed 5 cm well circumscribed contrast enhancing lesion occurring the left temporal base with another dumbbell component of 4 cm size in the frontal lobe. MRI also showed the classic dural tail sign which is characteristic of Meningioma (Fig 1,2).

Under ETGA and hypotensive anaesthesia, patient was placed in supine position and face turned to right side, a left fronto temporo parietal scalp incision made. Temporalis muscle was separated from the bone and the zygomatic arch exposed. With high speed drill left fronto temporo parietal craniotomy and zygomatic osteotomy was performed. Both the frontal and temporal part of the skull base exposed. Dura was opened along the margin of the tumor and the dura was devascularised from the surface of the tumor. The tumor was firm and very vascular in nature (Fig 3). With meticulous microsurgical technique and microscope the tumor was debulked. Tumor-brain interface was dissected along the arachnoid plane. Then the tumor was detached from the dura of the base of the frontal and temporal bone. There was a dumb bell component of the tumor going to the frontal lobe which was attached through a small pedicle. With meticulous dissection the tumor was removed in total along with involved dura without damaging the underlying brain parenchyma. Dura was reconstructed with the temporalis fascia and closed in water tight fashion. Temporalis muscle was reattached and the boneflap and zygomatic bone was replaced and fixed with mini plate and screws. Post operative period was uneventful (Fig 4). Histopathology confirmed it as Grade I meningioma. Three month follow up MRI showed no residual lesion (Fig 5).

Discussion

Meningioma comprise about one fourth of all primary tumors of the central nervous system (CNS). It is the most common primary intracranial neoplasm and the most diversified in histologic patterns among all primary tumors of the CNS. Meningioma arise from Arachnoidal cap cells. Meningiomas, as defined by the World Health Organization (WHO), are "meningothelial (arachnoid) cell neoplasms, typically attached to the inner surface of the dura mater," and these tumors fall into WHO grades I, II, and III. Meningioma is essentially a tumor of adulthood, with a peak incidence in the sixth decade of life. These tumors are twice as common in women. Atypical and anaplastic meningiomas, however, show a male predominance. Childhood meningiomas occur more often in males. Meningiomas associated with neurofibromatosis type 2 (NF2) tend to occur in younger individuals and with equal distribution between males and females. With the exception that papillary meningiomas are more common in children, meningiomas are rather uncommon in children and almost never occur in infants. When these tumors occur in children, however, they are more often infratentorial, intraventricular, or intraparenchymal than in adults.

Meningiomas are most commonly dural-based tumors in the brain and, less commonly, the spinal cord. Rare cases occur as intraventricular and pulmonary tumors. Most meningiomas are intracranial extra-axial tumors. About half of these tumors occur in the falx and parasagittal locations, and they are often firmly affixed to the sagittal sinus. The majority of the remainder occur in the skull base. Meningiomas are slow-growing tumors, and smaller ones often remain asymptomatic throughout life. For the larger and symptomatic tumors, symptoms result from local compression and peritumoral edema. Headache and newly onset seizures are the most common initial manifestations. For the rare tumors that arise in the ventricles, hydrocephalus is often part of the clinical picture.

Tumors that arise in the cranial base have a strong tendency to invade the surrounding osseous and nonosseous tissue, and they can be surgically challenging¹. Invasion of the cranial base and adjacent structures could cause a spectrum of manifestations, ranging from cranial nerve palsy, symptoms related to involvement of the sinuses and the orbit, dental complaints, and masses in the forehead. Cranial base meningiomas are more likely to recur², but this probably reflects the difficulty in total surgical resection rather than the biological nature of these tumors.

Contrast-enhanced MRI is the most sensitive method for detecting meningiomas. Meningiomas enhance strongly and often homogeneously. About half of patients have an area of dural enhancement, or so-called "dural tail." Histologically, the dural tails may be composed entirely of hypervascular, presumably reactive tissue, but not meningioma tumor cells. Management of meningiomas are entirely complete surgical excision of the tumor along with the involved dura and involved bone. Recurrence of the meningioma occur depending upon the extent of removal.(SIMPSON S GRADING)

Conclusion

Skull base meningiomas usually erode the adjacent bone and encircle the adjacent neurovascular structure, thus posing challenge in removing completely. Only with very good anatomical knowledge and meticulous neurosurgical skills they can be removed appropriately without damaging the adjacent normal brain^{3,4,5}.

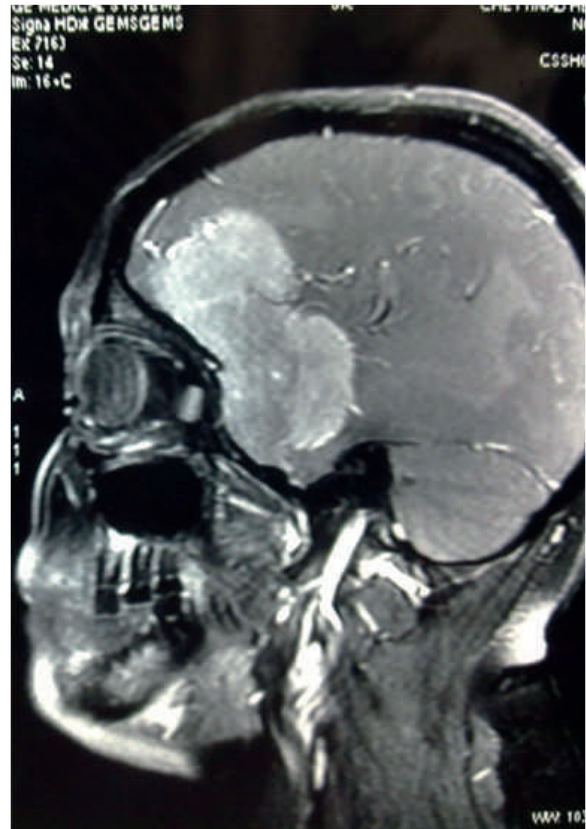


Fig 2 - Mri Sagittal Showing Basal Meningioma With Dumb Bell Component

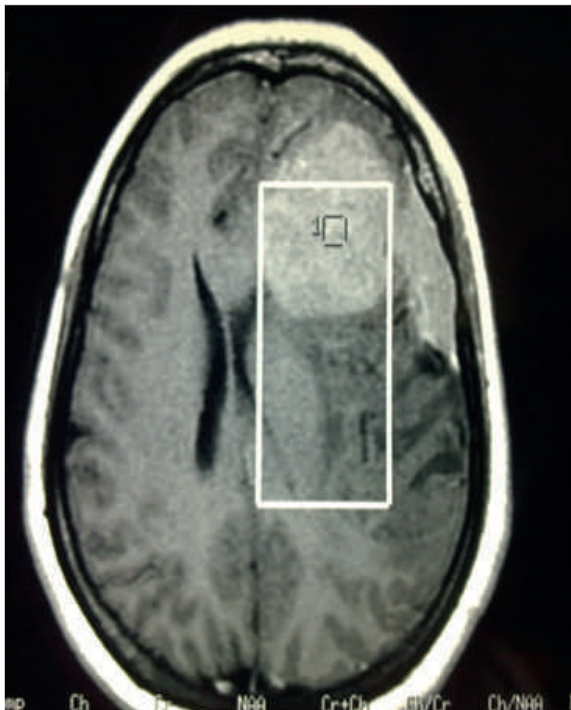


Fig 1 - Mri Brain Axial Showing Dural Based Lesion With Frontal Dumb Bell Component

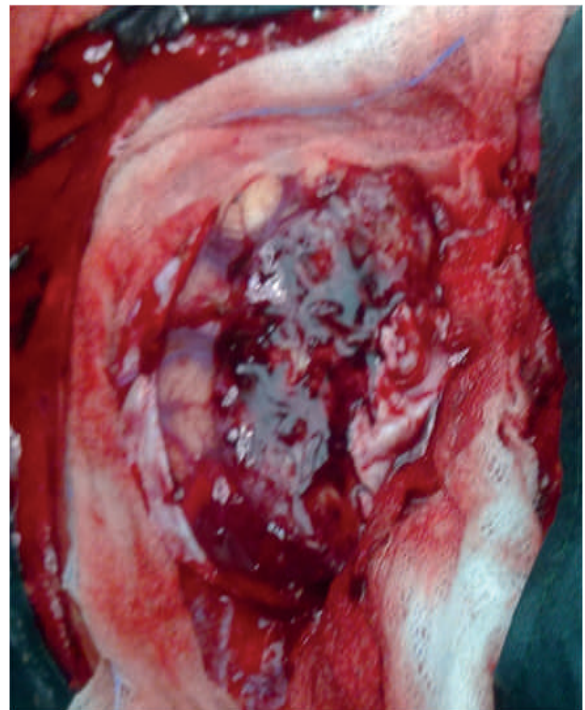


Fig 3 - Intra Operative Pic Showing Brain Dura & Tumor

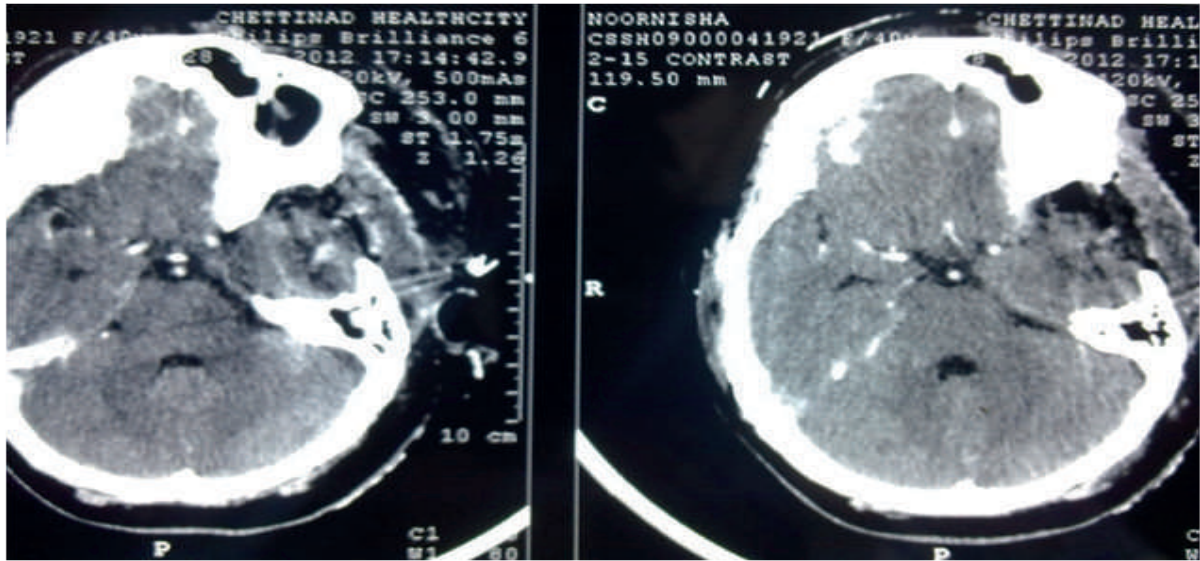


Fig 4 - Post op ct brain showing complete excision

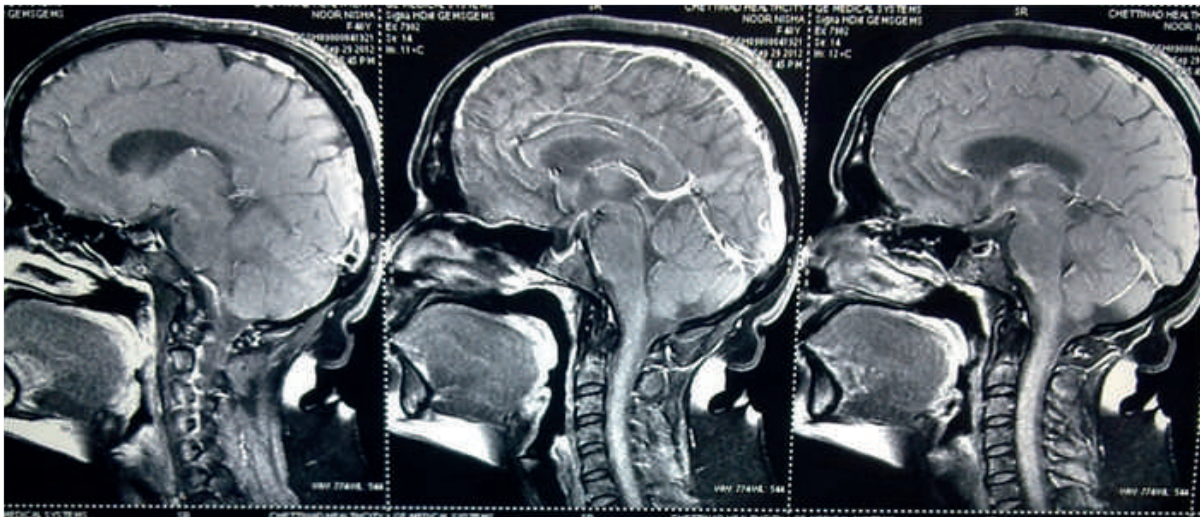


Fig 5 - Two Month Follow Up Mri Showing No Residual Lesion

References

- 1) Bikmaz K, Mrak R, Al-Mefty O. Department of Neurosurgery, University of Arkansas for Medical Sciences, Little Rock, Arkansas 72205-7199, USA. Management of bone-invasive, hyperostotic sphenoid wing meningiomas. *J Neurosurg.* 2007 Nov;107(5):905-12.
- 2) Sughrue ME, Rutkowski MJ, Chen CJ, Shangari G, Kane AJ, Parsa AT, Berger MS, McDermott MW. Brain Tumor Research Center, Department of Neurological Surgery, University of California, San Francisco, California 94143, USA. Modern surgical outcomes following surgery for sphenoid wing meningiomas; *J Neurosurg.* 2013 Jul;119(1):86-93.. Epub 2013 Feb 22.
- 3) Nakamura M, Roser F, Jacobs C, Vorkapic P, Samii M. Department of Neurosurgery, Nordstadt Hospital, Klinikum Hannover, Hannover, Germany. Medial sphenoid wing meningiomas: clinical outcome and recurrence rate; *Neurosurgery.* 2006 Apr;58(4):626-39, discussion 626-39.
- 4) Behari S, Giri PJ, Shukla D, Jain VK, Banerji D; Department of Neurosurgery, Sanjay Gandhi Postgraduate Institute of Medical Sciences, Lucknow, 226014, India. sbeari27@yahoo.com. Surgical strategies for giant medial sphenoid wing meningiomas: a new scoring system for predicting extent of resection. *Acta Neurochir (Wien).* 2008 Sep;150(9):865-77;
- 5) Liu DY, Yuan XR, Liu Q, Jiang XJ, Jiang WX, Peng ZF, Ding XP, Luo DW, Yuan J, Xiangya Hospital, Central South University, The Institute of Skull Base Surgery and Neurooncology at Hunan, Department of Neurosurgery, Changsha, Hunan, China. Large medial sphenoid wing meningiomas: long-term outcome and correlation with tumor size after microsurgical treatment in 127 consecutive cases; *Turk Neurosurg.* 2012;22(5):547-57.