

Case Report

T- Cell Lymphoma Arising From Gluteal Muscle –A Rare Presentation

Dr.K.Senthil Kumar* Dr. R. Anantharamkrishnan** Dr. R. Karunanithi***

*Assistant Professor, **Associate Professor, ***Professor, Department of Surgery, Chettinad Hospital and Research Institute, Chennai,India



Dr.K.Senthil Kumar M.S.,FMAS.,Dip in Lap, is an Assistant Professor in the Department of Surgery, Chettinad Hospital and Research Institute. He did his M.B.B.S in PSG Institute of Medical Sciences and Research (1999 batch) and postgraduation in Coimbatore Medical College (2006 batch). He joined Chettinad Hospital and Research Institute in 2009. He has done Fellowship in minimal access surgery. He has attended many state and national conferences and presented interesting clinical cases and case studies in surgery. He is a member of Asia Pacific Hernia Society and his field of interest is Urology and minimal access Surgery.

Corresponding author - Dr. K. Senthil Kumar (drsenthil_psg@yahoo.co.in)

Chettinad Health City Medical Journal 2014; 2(1): 11 - 13

Abstract

Non-Hodgkin Lymphomas (NHLs) are diverse group of blood cancers that include any kind of lymphoma except Hodgkin's lymphomas¹. NHLs arise from the lymph nodes or extranodal sites. B cell lymphomas are common and T cell lymphomas account for only 10 to 15 % of NHL. Extranodal sites comprise 24% – 48% of NHL cases, commonly occurring sites are GI tract, skin and bone. Rare localizations have also been reported like skeletal muscles comprising 0.5% of Extranodal NHLs². There is an increasing incidence of these Extranodal lymphomas during the past decades. Sometimes, Lymphomas present as refractory cellulitis and is diagnosed after failure to respond to antimicrobial therapy. Here we report a rare case of T cell type of NHL arising from gluteal muscle which presented with features mimicking cellulitis.

Key Words: T- Cell Lymphoma, Non-Hodgkin Lymphomas (NHLs), Gluteal swelling

Case Report

A 60 yr female presented to surgical opd with complaints of pain and swelling in the left gluteal region and hip for 2 weeks. She had fever and difficulty in walking for 3 days. There was no history of weight loss and loss of appetite. No significant past medical or surgical history. On examination patient was moderately built and well nourished. On examination patient was febrile, no pallor, left inguinal nodes palpable. Left side pitting pedal edema was present. No signs of DVT. Vitals were stable. CVS, RS examination was normal. Per abdomen examination : No hepatosplenomegaly Examination of the left gluteal region and thigh revealed Swelling in the lt gluteal region, thigh and lower limb (Fig 1). Tenderness present in the lt hip, lt iliac fossa, lt gluteal region. Warmth was present, and no fluctuation. Blood investigations were normal. USG left gluteal region was suggestive of cellulitis, with no evidence of loculation. Hence a diagnosis of gluteal cellulitis was made and the patient was started on intravenous antibiotics. Patient was treated conservatively for 1 week but her symptoms never improved. She had progression of pain and swelling. MRI showed features suggestive of inflammatory pathology in gluteal muscle (Fig 2). Hence Incision and drainage was planned under spinal anaesthesia. Intraop findings : Gluteal muscle was found to be unhealthy & grey in colour, intermuscular layer had fluid, no pus found. Hence muscle biopsy was taken and sent for histopathology, and fluid was sent for culture & sensitivity. Fluid showed no bacterial growth. Inguinal node biopsy showed reactive hyperplasia. Muscle biopsy report was positive for

malignancy-suggestive of high grade NHL (Fig 3a,3b). Immunohistochemistry showed strong positivity for CD 45, CD 3 than CD 20 (Fig 4a,4b,4c) confirming a diagnosis of diffuse large T cell lymphoma. Hence a diagnosis of primary T cell lymphoma arising from gluteal muscle was made. Patient was started on chemoradiation and responded well to treatment.

Discussion

The patient in this case presented with features suggestive of cellulitis and was found not responding to antimicrobial therapy. Patient was investigated further and MRI was done which also suggested features of cellulitis. Finally, muscle biopsy clinched the diagnosis of NHL - T cell type.

- Peripheral T cell Lymphoma generally affect 60 years and older and are common more often in men than in women³. The signs and symptoms vary according to the site, subtype and grade of lymphoma. Common signs and symptoms include fatigue, painless swelling in lymph nodes, fever, weight loss, night sweats. Primary extranodal lymphomas were defined as those presenting with extranodal sites and no or only minor lymph node involvement⁴. Almost any organ can be affected by NHL, the most common extranodal sites being stomach, Waldeyer ring, spleen, central nervous system, bone, lung, skin and skeletal muscles⁵. Primary muscle lymphoma is even less common. Although primary skeletal muscle NHL is very uncommon^{6,7} clinical presentation of refractory cellulitis, as seen in this case is extremely rare.

- The extranodal NHLs are difficult to treat, the main modality of treatment being anthracycline based chemotherapy regimes⁸ as follows: CHOP(cyclophosphamide, hydroxydoxorubicin, oncovin, prednisone) EPOCH (etoposide, prednisone, oncovin, cyclophosphamide, hydroxydoxorubicin) Hyper - CVAD (cyclophosphamide, vincristine, adriamycin, dexamethasone) "hyper" refers to "hyperfractionation of the dose". Locoregional radiation therapy is the treatment option for limited-stage disease.

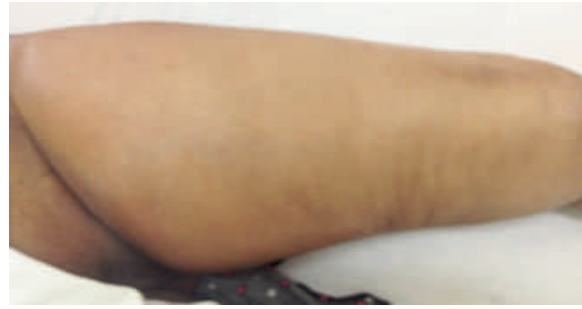

Fig 1: Clinical examination showing swelling left thigh and gluteal region

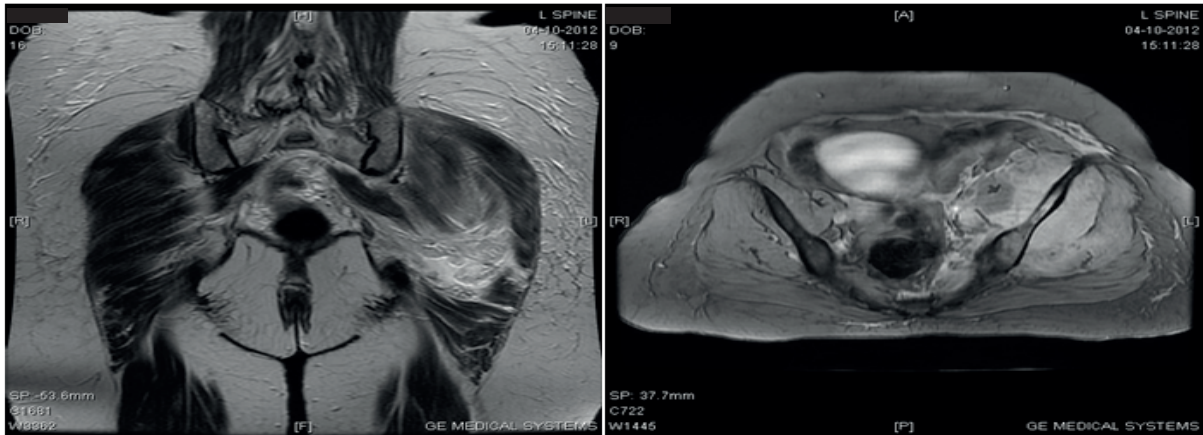


Fig 2: MRI left gluteal region and thigh showing muscle edema and fluid in the intermuscular space

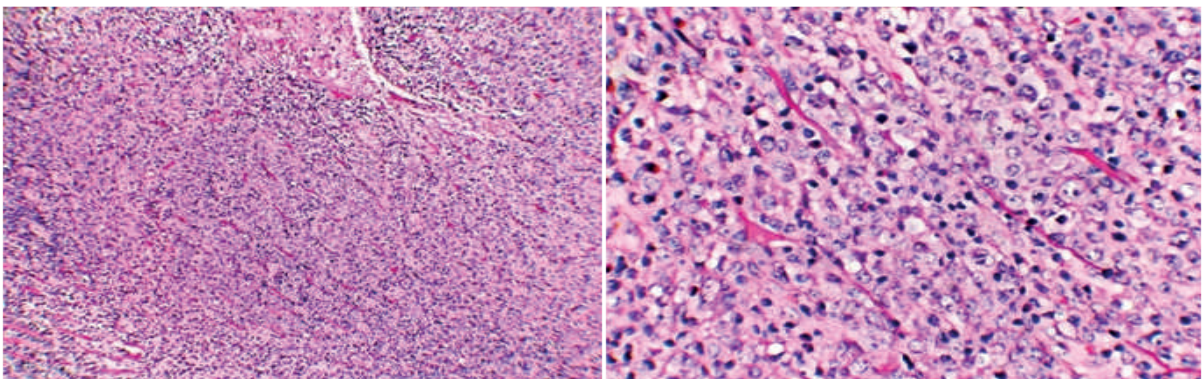


Fig 3: 3a&b: 3a:Muscle histology showing bundles of skeletal muscle infiltrated by atypical cells with eosinophilic cytoplasm and large nucleus (H&E,100X) / 3b:Mitosis and extensive areas of necrosis suggestive of high grade NHL.(H&E,400X)

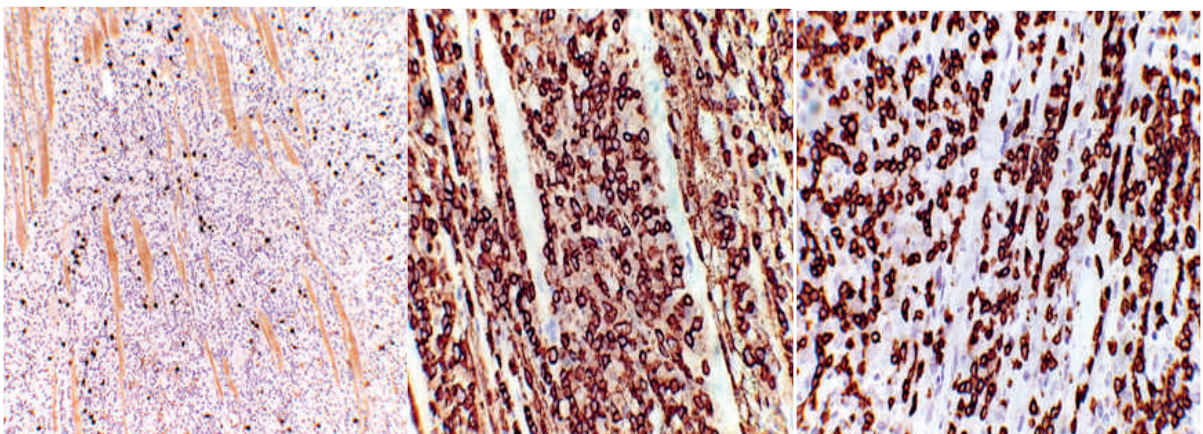


Fig 4a,4b,4c:Immunohistochemistry showing 4a(100X): B cell marker CD 20+ / 4b(400X): LCA-leucocyte common antigen CD 45 +++ / 4c(400X):T cell marker CD 3 ++ positivity suggesting diffuse large cell - T cell lymphoma

Conclusion

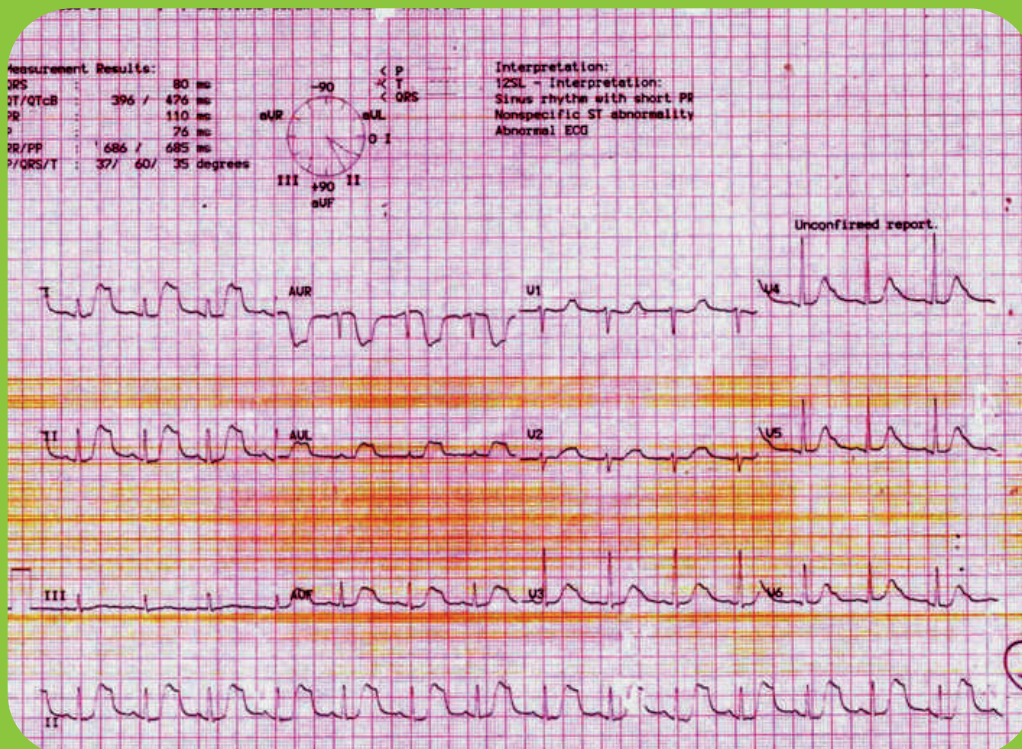
Malignancies are an important, although rare, cause of back pain which must be a consideration in patients with certain factors, or in patients who do not respond to treatment. This case report emphasizes the importance of performing a thorough examination of any unexplained complaint of low back, buttock or hip pain, the need for continual re-evaluation and modification of the initial diagnosis, the importance of diagnostic Ultrasound & MRI when clinically indicated and the importance of tissue biopsy in suspected cases.

References

- 1) Wikipedia-http://en.wikipedia.org/wiki/Non_Hodgkin_lymphomas - Dorland's medical dictionary
- 2) Laura Bourdeanu, Rashmi Menon, and George Somlo. Diffuse Large B-Cell Lymphoma with Calf Muscle Localization. Case Reports in Hematology (Internet) 2011[cited 2011]; doi:10.1155/2011/292494: (about 3 pages)
- 3) Muller A, Ihorst G, Mertelsmann R. Epidemiology of Non Hodgkin's lymphoma (NHL): trends, geographic distribution and aetiology. Ann Hematol. 2005;84:1-12.
- 4) Lopez-Guillermo A, Colomo L, Jimenez M, et al. Diffuse B cell lymphoma: clinical and biological characterization and outcome according to nodal and extranodal primary origin. J Clin Oncol. 2005;23:2797-2804.
- 5) Paes FM, Kalkanis DG, Sideras PA, Serafini AN. FDG PET/CT of extra nodal involvement in Non Hodgkin lymphomas and Hodgkin disease. Radiographics. 2010 30(1):269-291.
- 6) De Giorgi S, Piazzolla A, De Giorgi G, Cimmino A, Parisi G, Ricco R : Non hodgkin's lymphoma in the gluteal region-a case report ; Chir Organi Mov: 2004 Oct-Dec; 89(4):329-38
- 7) Baddour LM, Haden KH, Allen JW . Primary skeletal muscle lymphoma presenting as refractory cellulitis. Cutis. 2001 Sep; 68(3):223-6.
- 8) Zain JM, O'Connor O, . Targeted treatment and new agents in peripheral T cell lymphoma. International journal of Hematology. 2010;92(1):33-44.

Diagnose the condition

60 year old chronic smoker presented with chest pain radiating to both shoulder ridge for 3 days. ECG was taken



Answer in page no : 16

- Dr. N. Ganesh, Consultant Cardiologist, Chettinad Super Speciality Hospital.