

Case Report

Synchronous Presentation of Sporadic Angiomyolipoma and Renal Cell Carcinoma in Contra lateral Kidneys in Patient with no Evidence of Tuberous sclerosis

Dr. Femila Padmavathy. M*, Dr. Rajesh Nachiappa Ganesh**, Dr. Bhawana Ashok Badhe***, Dr. Arshad Jamal****

*Assistant Professor, Department of Pathology, Chettinad Hospital and Research Institute, Kelambakkam, India, **Assistant Professor, *** Professor, Department of Pathology, Jawaharlal Institute of Postgraduate Medical Education and Research (JIPMER), Puducherry, India, **** Senior Resident, Department of Urology, JIPMER.



Dr. Femila Padmavathy did her graduation from Madurai Medical college & post graduation from JIPMER. She received the endowment prize for post graduation studies and has published articles in international indexed journals. She has presented papers in national conferences and has received awards for the same.

Corresponding author - Dr. Femila Padmavathy. M (fppathology@gmail.com)

Abstract

Angiomyolipoma is an uncommon benign tumor. Clinical presentation of angiomyolipoma either sporadic or in association with tuberous sclerosis has been reported in several studies. Synchronous manifestation of angiomyolipoma and renal cell carcinoma in contralateral kidneys raised clinical suspicion of bilateral renal cell carcinoma in our patient. Patient was a 60 year old male and he was thoroughly investigated for evidence of tuberous sclerosis and was found to have none. Ultrasound evaluation of abdomen did not reveal the characteristic echogenicity of fat in the left kidney. Hence bilateral renal tumors were diagnosed as renal cell carcinoma upstaging the tumor and hence modifying the treatment plan. Computerised Tomography (CT) scan examination further confirmed the diagnosis of bilateral renal cell carcinoma. Histopathology examination however confirmed a sporadic angiomyolipoma in the left kidney and renal cell carcinoma in the right.

Key Words : Angiomyolipoma; Renal cell carcinoma; Synchronous

Chettinad Health City Medical Journal 2012; 1(4): 192 - 195

Case Report

Angiomyolipoma is an uncommon benign tumor and is composed of adipose tissue, smooth muscle and blood vessels. Renal angiomyolipomas are known to be associated with tuberous sclerosis. But this association occurs only in approximately fifty per cent of cases of angiomyolipomas.¹⁻⁵ Tuberous sclerosis was first reported by von Recklinghausen in 1863 and it was described as a syndrome by Bourneville in 1880. It is an autosomal dominant disorder and presents typically with a clinical triad of mental retardation, seizures and adenoma sebaceum. This condition is so named for the potato like nodules present in the brain.⁶⁻⁹ The revised diagnostic criteria for tuberous sclerosis complex, determined by the Committee of the the National Tuberous Sclerosis Association (now the T.S. Alliance) are the following: Major criteria include facial angiofibromas, forehead plaques, non-traumatic ungual or periungual fibromas, hypomelanotic macules more than three in number and Shagreen's patch; and the minor criteria are multiple randomly distributed pits in dental enamel and gingival fibromas.⁹ The clinical presentation of patients having angiomyolipoma with and without tuberous sclerosis has been reported in several studies.^{1-4,6-8,10-16} We report a case of angiomyolipoma in one kidney who presented concurrently with renal cell carcinoma in the other kidney, without any stigmata of tuberous sclerosis.

A 60-year-old man presented to the Urology out-patient department with complaints of right flank pain for the past six months and one episode of hematuria. On examination, the patient was conscious, oriented; his vital parameters were normal; no lymph nodes were palpable; a lump was palpable in the right loin; on general and systemic examination, no other abnormality was detected. Routine investigations revealed that the renal functions were normal. Ultrasonogram showed a tumor in the right kidney and it was provisionally diagnosed as renal cell carcinoma. Contrast (Iomeron 400, Iomeprolbracco, Milano) enhanced computed tomogram (CECT) showed a mass lesion in the upper pole of the right kidney which was measuring about 6X5 cm and a mass lesion in the lower pole of the left kidney which was measuring about 3X3 cm (Fig. 2,3). Both the lesions were suspected to be renal cell carcinoma. Partial nephrectomy of the smaller lesion in the left kidney and radical nephrectomy of the larger lesion in the right kidney were planned for. First, partial nephrectomy was done on the left side. It showed a haemorrhagic nodule in the lower pole measuring 3 cm X 2 cm X 2 cm, involving neither the capsule nor the Gerota's fascia. Cut section of the nodule showed solid, ill circumscribed areas of haemorrhage and yellowish areas of fat. Intraoperative, no lymphadenopathy was noted. Histological examination revealed

c l a s s i c a l

features of angiomyolipoma viz. sheets of mature adipose tissue, tortuous thick walled blood vessels and smooth muscle tissue with areas of haemorrhage (Fig. 1a & Fig. 1b). The tumor cells stained strongly with HMB45 (Fig. 1c) while Smooth muscle actin (SMA) (Fig. 1d) was positive in the blood vessels. After five weeks, radical nephrectomy was done on the right side. A circumscribed mass was seen in the upper pole. The tumor was seen replacing most of the renal parenchyma, involving both cortex and pelvis and bulging outside. The overlying renal capsule, the perinephric pad of fat and the Gerota's fascia were adherent to the tumor at a few foci. But the tumor was not breaching the Gerota's fascia. The tumor showed dark brown areas of hemorrhage, few areas of fat and few areas of necrosis. The preserved renal parenchyma measured 1.5 cm in its maximum dimension. Renal medulla could not be seen grossly. No lymphnodes were seen in the specimen even on meticulous examination. Histology showed renal cell carcinoma – clear cell type – Fuhrman nuclear grade III (Fig. 1e). The tumor cells contained intracytoplasmic fat. The renal capsule, adrenals, the Gerota's fascia, the renal sinus, ureter and the renal vessels were free of tumor.

Discussion

Concurrent presentation of angiomyolipoma and renal cell carcinoma in the absence of tuberous sclerosis has been reported very occasionally.¹⁷ Fifty per cent of renal angiomyolipomas occur in patients with tuberous sclerosis.¹⁴ Coexisting angiomyolipoma and renal cell carcinoma have been described in patients with^{6,7,10,12} and without^{8,10,12-14,16} tuberous sclerosis. In a review of ten patients with coincidental angiomyolipoma and renal cell carcinoma, 50% exhibited tuberous sclerosis.¹³ A case who presented with metachronous renal cell carcinoma 9 years after resection of angiomyolipoma in the contra lateral kidney in a patient without tuberous sclerosis has also been reported.¹⁷ The pathogenesis of renal cell carcinoma in a case of angiomyolipoma is still not determined.⁷ Possibility of a genetic link between angiomyolipoma and renal cell carcinoma has been suggested with a few molecular studies. Cohen et al described a family in which, out of ten family members, eight had demonstrated association between angiomyolipoma and renal cell carcinoma.^{17,18} Genotypic analysis disclosed a reciprocal translocation between chromosomes 3 and 8 [t(3;8) / (p14;q24)].^{18,19} Matthews et al discuss a case of renal cell carcinoma in a patient without tuberous sclerosis, occurring 9 years after contra lateral resection for angiomyolipoma. Possible predisposition of a patient with angiomyolipoma with or without tuberous sclerosis to develop renal cell carcinoma in the same or contra lateral kidney still needs to be determined. They advocate that any renal angiomyolipoma should be suspected as a premalignant lesion to renal cell carcinoma. Further molecular studies have to be undertaken to determine exactly what makes a patient with angiomyolipoma vulnerable to contract renal cell carcinoma.^{16,17} Further, Malone et al state that angiomyolipoma with tuberous sclerosis should be considered suspicious for potentially harboring renal cell carcinoma.¹⁴ The clinical presentation of

angiomyolipoma and renal cell carcinoma in patients with tuberous sclerosis is different from that in patients without tuberous sclerosis. Either angiomyolipoma or renal cell carcinoma tends to be multifocal and bilateral in the setting of tuberous sclerosis, whereas both tend to be solitary in non-tuberous sclerosis cases.^{8,13,20} Also, tuberous sclerosis patients tend to develop renal failure as compared to the non-tuberous sclerosis patients.¹³ Our case presented with right flank pain, an episode of hematuria and no stigmata of tuberous sclerosis complex. A lump was palpable in the right flank but not on the other side. In the recent days, the combined imaging of CT and ultrasonography is being increasingly used to arrive at an accurate pre-operative diagnosis of an angiomyolipoma.¹⁰ The classical findings of an angiomyolipoma are of low attenuation areas of fat on CT and hyperechogenicity on ultrasonography from the multiple fat and non-fat interfaces within the tumor. However, not all angiomyolipomas demonstrate these findings.² In our case, ultrasonography could not pick up the lesion in the left kidney though the right kidney lesion was correctly diagnosed as renal cell carcinoma. Further, the echogenicity produced due to the lipid density in case of an angiomyolipoma was not appreciated in this case. CECT picked up both the lesions and diagnosed them to be renal cell carcinomas because the attenuation produced in the left kidney was consistent with that of a carcinoma. It was not too low to render a diagnosis of angiomyolipoma.⁸ Grossly, both the lesions had areas of fat and both had extensive areas of hemorrhage. This picture can be seen in both angiomyolipoma and renal cell carcinoma; although fat is less commonly seen in renal cell carcinoma.⁵ The radiological diagnosis of an angiomyolipoma would be based on the high fat content present in the tumor. Sometimes it becomes difficult to differentiate between angiomyolipoma and renal cell carcinoma radiologically, particularly if the fat content is less, since the appearance of the non-fat component of angiomyolipoma is similar to renal cell carcinoma on ultrasonogram, computed tomogram and angiographic studies.¹³ The high vascularity in case of angiomyolipoma can also mimic carcinoma.¹⁴ The histological type of renal cell carcinoma in this case is the clear cell type and this type has been observed as the most common histologic subtype in both sporadic and tuberous sclerosis – associated cases in a study by Jimenez et al.¹²

Summary

We present an additional sporadic case of angiomyolipoma in one kidney with synchronous renal cell carcinoma in the contra lateral kidney without any signs of tuberous sclerosis. The preoperative diagnosis was renal cell carcinoma on both CT and USG. Nevertheless USG missed to note the lesion on the left side. Partial and radical nephrectomies were performed on the left and right sided kidneys respectively. Histopathology showed angiomyolipoma in the left kidney and clear cell type of renal cell carcinoma in the right kidney.

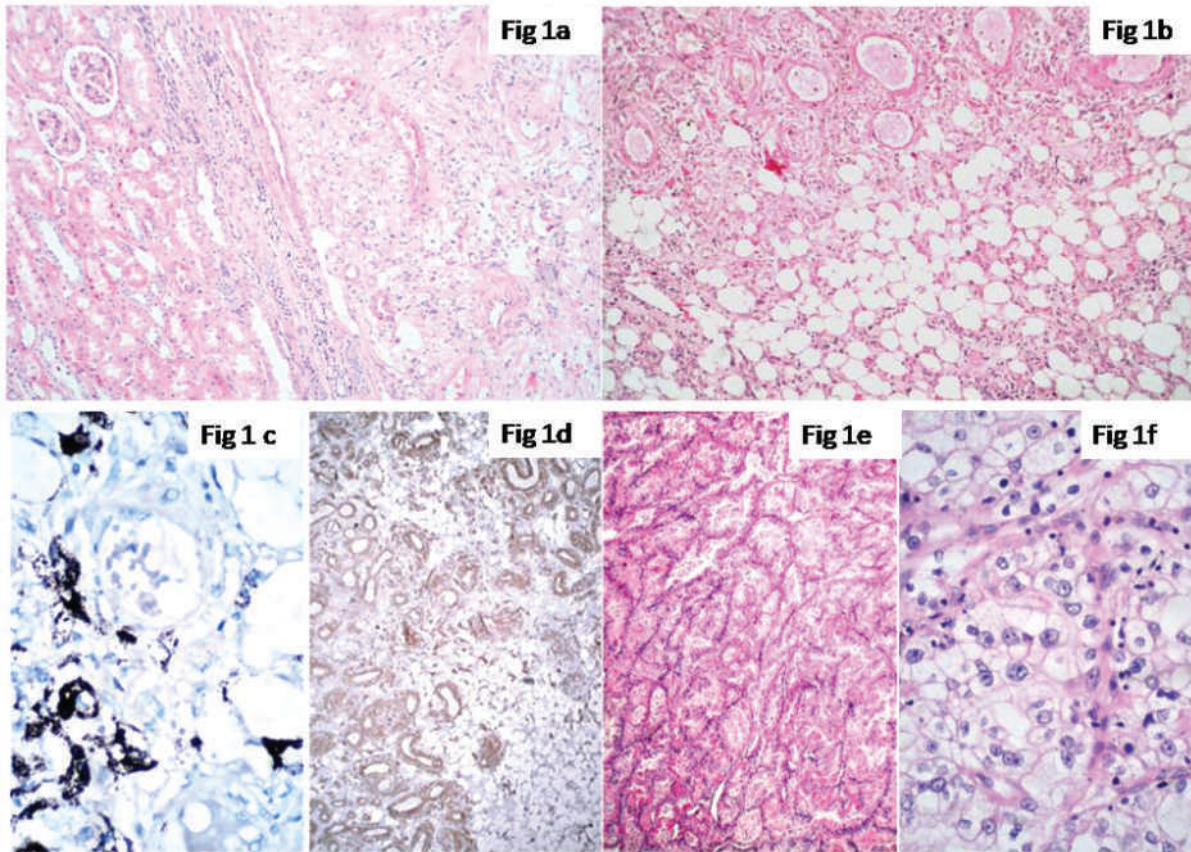


Figure 1a – Section shows angiomyolipoma at the interface with normal kidney, Hematoxylin and Eosin stain, x 50

Figure 1b – Section shows angiomyolipoma with admixture of tumor cells, adipocytes and blood vessels, Hematoxylin and Eosin stain, x 100

Figure 1c – Section shows strong cytoplasmic positivity for HMB-45 in tumor cells, Immunohistochemistry with HMB-45, DAKO Polymer technique DAB Chromogen, x400

Figure 1d – Section shows strong cytoplasmic positivity for Smooth muscle actin (SMA) in blood vessels of angiomyolipoma, Immunohistochemistry with SMA, DAKO Polymer technique DAB chromogen, x100

Figure 1e – Section shows clear cell carcinoma of kidney, Hematoxylin and Eosin stain, x 50

Figure 1f – Section shows Fuhrman nuclear grade III in clear cell type of renal cell carcinoma, Hematoxylin and Eosin stain, x 400

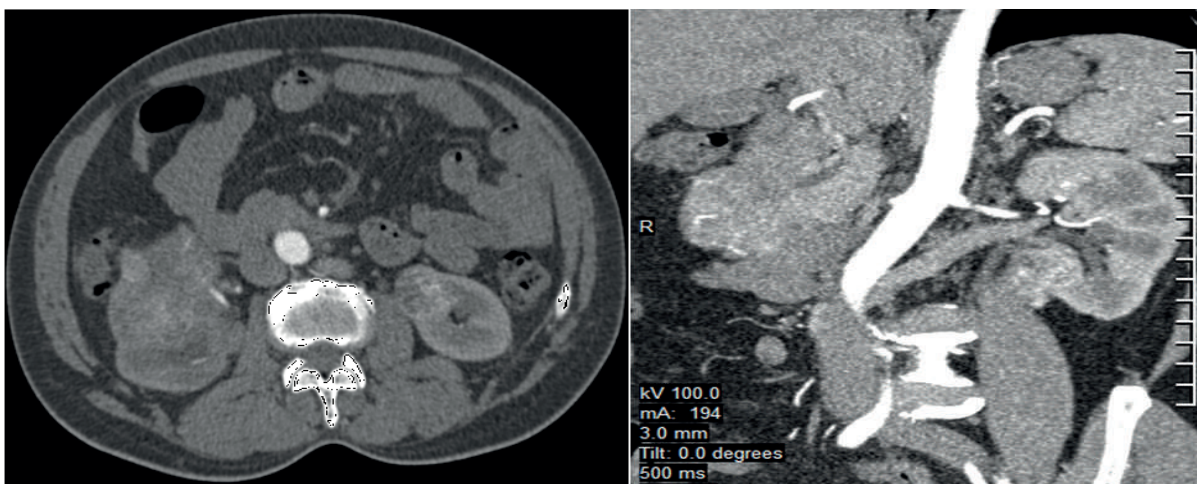


Fig. 2.3 - CECT abdomen showing a mass lesion in the upper pole of right kidney and lower pole of left kidney

References

- 1) Walker DE, Barry JM, Hodges CV. Angiomyolipoma: Diagnosis and treatment. *J Urol.* 1976;116:712-4
- 2) Wong K, Kaisary AV, Waters CM, Horner J, Hershman MJ. Angiomyolipoma of the kidney: a clinical enigma in diagnosis and management. *Ann R Coll Surg Engl.* 1992;74:144-8
- 3) Wong AL, McGeorge A, Clark AH. Renal angiomyolipoma: A review of the literature and a report of 4 cases. *Br J Urol.* 1981;53:406-11
- 4) Chonko AM, Weiss SM, Stein JH, Ferris TF. Renal involvement in tuberous sclerosis. *Am J Med.* 1974;56:124-32
- 5) Muttarak M, Pattamapaspong N, Lojanapiwat B, Chaiwun B. Renal angiomyolipoma with bleeding. *Biomed Imaging Interv J.* 2007;3(4):e8
- 6) Graves N, Barnes WF. Renal cell carcinoma and angiomyolipoma in tuberous sclerosis: Case report. *J Urol.* 1986;135:122-3
- 7) Taylor RS, Joseph DB, Kohaut EC, Wilson ER, Bueschen AJ. Renal angiomyolipoma associated with lymph node involvement and renal cell carcinoma in patients with tuberous sclerosis. *J Urol.* 1989;141:930-2
- 8) Takeyama M, Arima M, Sagawa S, Sonoda T. Preoperative diagnosis of coincident renal cell carcinoma and renal angiomyolipoma in nontuberous sclerosis. *J Urol.* 1982;128:579-81
- 9) Irvine AD, Mellerio JE. Genetic and genodermatoses. In: Burns T, Breathnach S, Cox N, Griffiths C, editors. *Rook's textbook of dermatology.* 8th ed. Vol.1. West Sussex: Wiley-Blackwell; 2010. p.15.1-15.97
- 10) Blute ML, Malek RS, Segura JW. Angiomyolipoma: Clinical metamorphosis and concepts for management. *J Urol.* 1988;139:20-4
- 11) Rakowski SK, Winterkorn EB, Paul E, Steele DJR, Halpern EF, Thiele EA. Renal manifestations of tuberous sclerosis complex: Incidence, prognosis, and predictive factors. *Kidney int.* 2006;70(10):1777-82
- 12) Jimenez RE, Eble JN, Reuter VE, Epstein JI, Folpe AL, de Peralta-Venturina et al. Concurrent angiomyolipoma and renal cell neoplasia: a study of 36 cases. *Mod Pathol.* 2001;14(3):157-63
- 13) Huang JK, Ho DM, Wang JH, Chou YH, Chen MT, Chang SS. Coincidental angiomyolipoma and renal cell carcinoma – report of 1 case and review of literature. *J Urol.* 1988;140:1516-8
- 14) Malone MJ, Johnson PR, Jumper BM, Howard PJ, Hopkins TB, Libertino JA. Renal angiomyolipoma: 6 case reports and literature review. *J Urol.* 1986;135:349-53
- 15) Gutierrez OH, Burgener FA, Schwartz S. Coincidental renal cell carcinoma and renal angiomyolipoma in tuberous sclerosis. *Am J Roentgenol.* 1979;132(5):848-50
- 16) Kavaney PB, Fielding I. Angiomyolipoma and renal cell carcinoma in the same kidney. *Urology.* 1975;6:643-6
- 17) Matthews MR, Caruso DM, Kassir AA, deGuzman J. Renal cell carcinoma 9 years after contralateral resection for angiomyolipoma in a patient without tuberous sclerosis. *Hosp Physician.* 1999;70-5
- 18) Cohen AJ, Li FP, Berg S, Marchetto DJ, Tsai S, Jacobs SC et al. Hereditary renal-cell carcinoma associated with a chromosomal translocation. *N Engl J Med.* 1979;301(11):592-5
- 19) Berg S, Jacobs SC, Cohen AJ, Li F, Marchetto D, Brown RS. The surgical management of hereditary multifocal renal carcinoma. *J Urol.* 1981;126:313-5
- 20) Eble JN, Young RH. Tumors of the urinary tract. In: Fletcher CDM. *Diagnostic histopathology of tumors.* 3rd ed. Vol.1. Philadelphia: Churchill Livingstone Elsevier; 2007. p. 485-566