

Case Report

Peripheral Giant Cell Granuloma

Dr.Karthik Krishna Munagala *, Dr.V.Gopinath**, Lumbini M***

*Reader, Dept. of Periodontology, Teerthanker Mahaveer Dental College and Research Centre, Moradabad, ** Associate Professor, Dept. of Periodontology, Rungta Dental College and Research Institute, Bhilai. *** Junior Resident, Dept. of Preventive and Pediatric Dentistry, Teerthanker Mahaveer Dental College and Research Centre, Moradabad.



Dr.Karthik Krishna Munagala graduated from Meenakshiammal Dental College and is currently working as Reader in the department of Periodontology, Teerthanker Mahaveer Dental College and Research Centre, Moradabad. His areas of interest includes regenerative periodontal surgical procedures.

Corresponding author - Dr.Karthik Krishna munagala (karthikmunagala@gmail.com)

Abstract

The peripheral giant cell granuloma (PGCG) is a rare reactive lesion of the gingival tissues. Usual contributing factors include local irritating factors such as plaque, calculus, food impaction, trauma, badly finished fillings and tooth extraction. This case report presents the clinical and histopathological features and management of a PGCG lesion in a 25-year old man.

Key Words : Peripheral giant cell granuloma, Osteoclastoma giant cell hyperplasia

Chettinad Health City Medical Journal 2012; 1(4): 196 - 198

Introduction

Peripheral giant cell granuloma (PGCG) is an infrequent exophytic lesion of the oral cavity. It is known by other terms such as giant cell epulis, osteoclastoma, giant cell reparative granuloma, or giant cell hyperplasia. The PGCG can be localized on the attached gingiva or alveolar mucosa. The lesion usually originates from either the periodontal ligament or mucoperiosteum and is more common in the mandibular arch and frequently occurs anterior to the permanent first molars.¹

It is more common between the fifth and sixth decades of life, with slight predilection for women. The exact etiology of PGCG is unknown, but may be caused by deposits such as plaque and calculus, trauma, rough or overhanging restoration margins, chronic infections, and food impaction. Clinically, the PGCG appears as a bluish red nodular lesion with a smooth, shiny surface and sessile or pedunculated base. The lesion is variable in size, though reportedly rarely exceeding 2 cm in diameter, and are generally soft or rubbery to touch. The lesion is well demarcated from the adjacent tissue. Usually, PGCG is asymptomatic, but the patient may complain of bleeding and pain.²

Radiologically, no significant finding can be observed. Rarely, the underlying alveolar bone may show superficial erosion which may present in the radiograph as superficial destruction of the alveolar margin or crest of the interdental bone. Histological features of PGCG reveal a non-capsulated mass of tissue containing a large number of young connective tissue cells and multinucleated giant cells. Hemorrhage, hemosiderin, inflammatory cells, and newly formed bone or calcified material may also be seen throughout the cellular connective tissue.³

Case Report

A 25-year-old man complaining of pain and swelling in upper right gums was referred to the Dept. of Periodontology, Patient appeared apparently healthy without any significant medical history. On extra-oral examination, patient presented with swelling in the upper right cheek region and involvement of the left submandibular lymphnodes. Intraorally, a dumbbell shaped tumoral mass was present involving the buccal and palatal gingiva of right upper first and second premolars. (Fig.1)

The lesion measured approximately 2 x 1.5 x 1 cm on the buccal aspect and 1 x 10.75 on the palatal aspect.(Fig.2) The patient had noticed the lesion 1 year back and it gradually increased in size. The lesion was well-defined, sessile with a bluish red tinge on the entire surface. On palpation, the lesion was tender, smooth and soft in consistency. An intra-oral periapical radiograph of the involved region showed radiolucency and slight loss in vertical height of the interdental bone. (Fig.3) After thorough clinical and radiological examination, it was decided to do an excisional biopsy of the lesion.

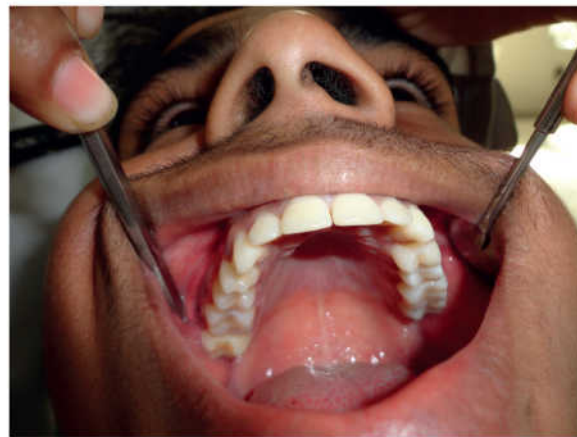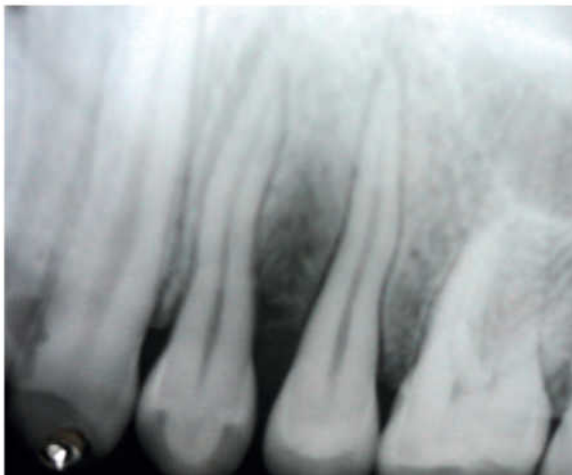
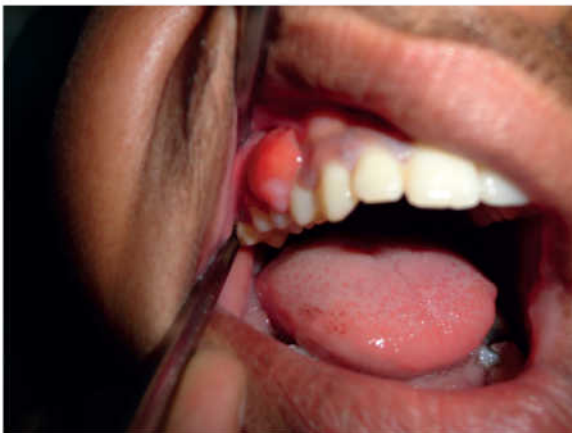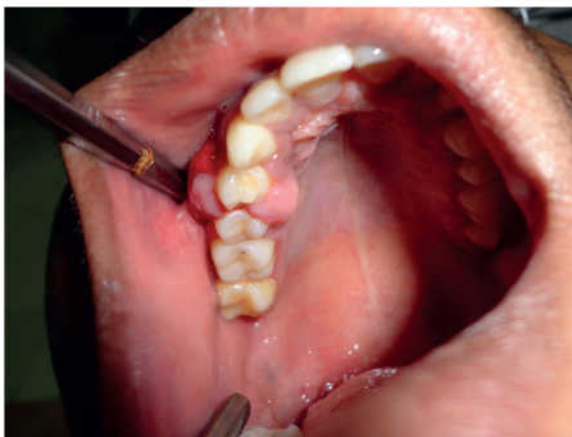Excision was done with a No. 15 b-P blade by splitting the lesion into buccal and palatal sections. (Fig4, 5, 6) During biopsy, the lesion bled profusely and was controlled by physical pressure. Histopathological examination under low magnification showed proliferative epithelium overlying a vascular connective tissue stroma. Under higher magnification, epithelium was of parakeratinized stratified squamous type. Connective tissue stroma showed numerous proliferating blood vessels with extracellular

hemorrhage. Several multi-nucleated giant cells were seen interspersed in the connective tissue stroma. (Fig.7)

As the lesion was exophytic and hyperplastic in nature, differential diagnosis includes pyogenic granuloma, central giant cell granuloma and fibroma. However, absence of ossification did not support the central giant cell granuloma and presence of vascularity can exclude fibroma. The presence of several giant cells and hemorrhage ruled out other forms of inflammatory hyperplastic lesions such as pyogenic granuloma.

Discussion

Giant cell granulomas (peripheral and central) are benign, non odontogenic, moderately rare tumors of the oral cavity. They originate from the periosteum or



periodontal membrane following local irritation or chronic trauma. Generally, PGCG size varies from 0.5 to 1.5 cm in diameter. There are no pathognomonic clinical features whereby these lesions can be differentiated from other forms of gingival enlargement. Microscopic examination is required for definitive diagnosis. The PGCG has numerous foci of multinuclear giant cells and hemosiderin particles in a connective tissue stroma. Areas of chronic inflammation are scattered throughout the lesion, with acute involvement occurring at the surface. The overlying epithelium is usually hyperplastic, with ulceration at the base.⁴

The exact etiology of PGCG is unknown. Local irritation factors such as poor dental restorations, dental extraction, plaque, and calculus accumulation play significant role in the development of a PGCG.⁵ In the above-mentioned case, it could be because of chronic irritation and food impaction. The radiographic examinations generally don't show any findings since it is confined to soft tissue without involving the bone. But in this patient, loss of crestal bone with mild cratering was observed interdentally in the involved region. This may be due to secondary chronic inflammatory changes that might have occurred due to deepening of the gingival sulcus.

Because of the recurrence rate, close follow-up is indicated. The patient was followed upto a period of 6 months with recall visits once every month. Patient had no further complains and no recurrence of the lesion was noted.

The early and precise diagnosis of peripheral giant cell granuloma allows conservative management without risk to the adjacent teeth or bone. Proper therapy and regular follow-up will help in ensuring that there is adequate healing and minimal chance of recurrence, as demonstrated in this case.

References

- 1) Ozcan E, Bodur S, Erdem G. Peripheral Giant Cell Granuloma – A Case Report. *Pak Oral Dent J* 2011;31(1):171-2.
- 2) Adlakhia VK, Chandna P, Rehani U, Rana V, Malik P. Peripheral Giant Cell Granuloma. *J Ind Soc Ped Prev Dent*;28: 293-6.

- 3) Subarnbhesaj A. Peripheral Giant Cell Granuloma : A Case Report and Review of Literature. Khon Kaen Dental J 2005;8:125-30.
- 4) Falaschini S, Ciavarella D, Mazzanti R, Di Cosola M, Turco M, Escudero N, Bascones A, Lo Muzio L. Peripheral Giant Cell Granuloma: Immunohistochemical Analysis of Different Markers. Study of Three Cases. Av. Odontostomatol 2007; 23(4): 189-196.
- 5) Chaparro-Avendaño AV, Berini-Aytés L, Gay Escoda C. Peripheral Giant Cell Granuloma. A Report of Five Cases and Review of The Literature. Med Oral Patol Oral Cir Bucal 2005;10:48-57.

A new role for yellow pigment?

We all recognize bilirubin as the haem-derived pigment that imparts an unpleasant yellow colour to those afflicted with certain liver diseases and haemolytic anaemias. But most people fail to realise that it is not a waste product but a powerful anti-oxidant. In a new study carried out in University of Missouri, the researchers discovered that bilirubin could prevent or limit the extent of vascular damage in individuals at risk for occlusive cardiovascular disease. It does so by inhibiting the growth of vascular smooth muscle cells without killing them. However, as bilirubin is not soluble in water and is rather quickly digested when consumed orally, the challenge is to find a way to exploit this useful property of bilirubin therapeutically to check the largest killer. The authors' suggestion: coat the stents with bilirubin. (Frontiers in Pharmacology, 2012; 3 DOI: 10.3389/fphar.2012.00048)

- Dr. K. Ramesh Rao