

# Case Report

## Warty But Not Warts

Riswana Jasmine M\*, Preethi K\*, Meenakshi Mohanram\*\*, Srinivasan M S\*\*\*

\*Postgraduate Student, \*\*Associate Professor, \*\*\*Professor & HOD, Dept of Dermatology, Chettinad Hospital and Research Institute, Chennai, India



Dr. M. Riswana Jasmine is an undergraduate (2004 – 2010) from Pondicherry Institute of Medical Sciences (PIMS). She is currently pursuing her post graduation in Dermatology in Chettinad Medical College and Research Institute. She has attended various National and International conferences where she has presented papers and posters.

Corresponding author -Riswana Jasmine M (riswana.j@gmail.com)

### Abstract

Warty dyskeratoma (WD) is a benign epidermal proliferation characterized by a reddish-brown or skin colored solitary papule or nodule with central follicular plugging. It is usually limited to the scalp, neck and face but has occasionally been reported on oral and vulval mucosae. Herein we report a female patient presenting with multiple verrucous papules on the scalp diagnosed clinically and histopathologically as warty dyskeratoma. The etiology of WD is unknown, but ultraviolet light, autoimmunity, viral infections, chemical carcinogens, and smoking have been postulated to play a role. Besides the characteristic histopathological features, the clinical appearance of WD is distinctive and is composed of discrete papules or nodules.

**Key Words:** Warty dyskeratoma, Verrucous

Chettinad Health City Medical Journal 2014; 3(3): 141 - 142

### Introduction

The skin of the scalp has several unique features that aid in its critical role of protecting the head. The follicular density is much higher, creating a dark, warm and moist environment. These unique features of the scalp make it susceptible to various infections, inflammations and tumors. A clear understanding of each disease process and its unique manifestations is key to developing an accurate differential diagnosis.

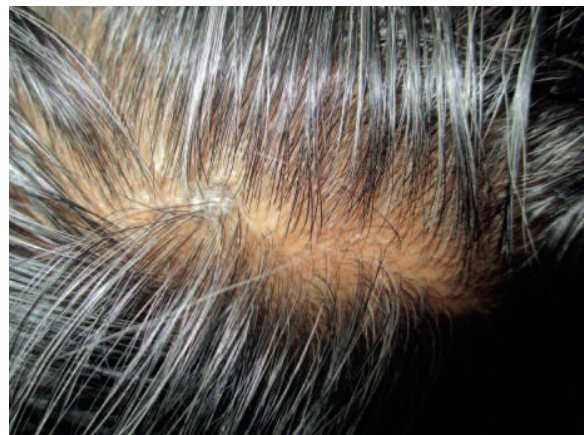Warty dyskeratoma (WD) is a benign epidermal proliferation characterized by a reddish-brown or skin colored solitary papule or nodule with central follicular plugging.

It is usually limited to the scalp, neck and face but has occasionally been reported on the oral and vulval mucosae<sup>1</sup>.

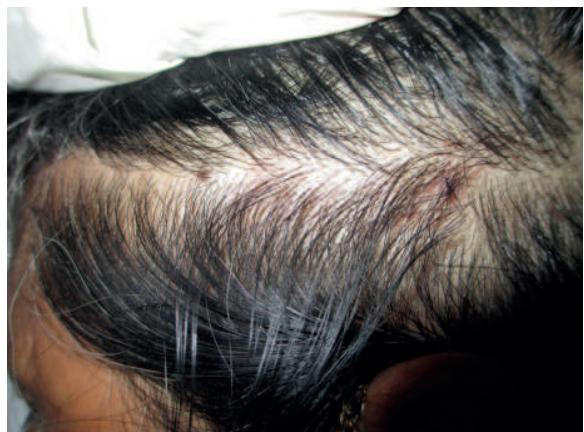
### Case Report

- A 56 year old woman presented to our out patient department with 5 years history of asymptomatic raised skin lesions on the scalp.
- The lesions were insidious in onset. The number of lesions were increasing gradually since one month. Oral mucosa, genital mucosa and nails were normal. She had no other dermatological or systemic disease and no history of preceding trauma.

On examination well demarcated erythematous and hyperpigmented verrucous papules of 0.5-2cm with yellowish plug were seen on the left parietal scalp. (Fig. 1 & 2)

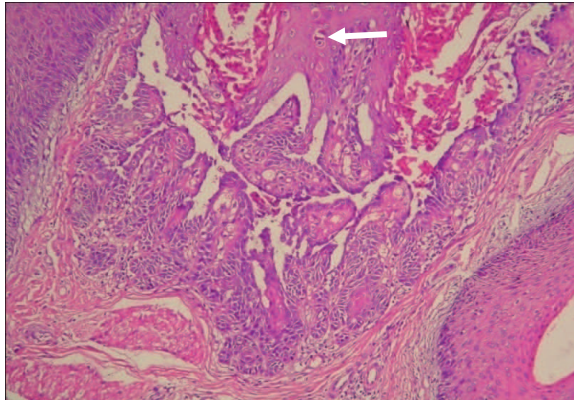


**Fig 1 - Hyperpigmented verrucous plaque on the scalp**



**Fig 2 - Multiple hyperpigmented warty papules**

A biopsy was obtained for histological diagnosis. Histopathological examination showed medium sized invagination of epidermis connected with a column of keratinous material. The invaginated area showed acantholytic dyskeratotic cells (Fig. 3). In this particular case the lesions resolved spontaneously.



**Fig 3** - HPE shows skin with a central lesion occupied by medium sized invagination of epidermis connected with a column of keratinous material. The invaginated area shows acantholytic dyskeratotic cells. (The arrow marked shows a dyskeratotic keratinocyte)

## Discussion

Warty dyskeratoma (WD) is a rare and benign epidermal proliferation that was first described in 1954 by Helwig. The term warty dyskeratoma was later coined by Szymansky in 1957<sup>2</sup>. It manifests as a peculiar hyperkeratotic umbilicated persistent nodule usually limited to head and neck regions. Oral involvement<sup>3</sup> particularly the hard palate, and genital involvement have been reported<sup>1</sup>. A rare subungual warty dyskeratoma has also been reported<sup>4</sup>. Most common in middle aged individuals, males are more commonly affected. In most cases, its size does not exceed 5 mm<sup>5,6</sup> and the largest tumor reported is 3 cm in diameter<sup>7</sup>. Multiple lesions may occur in the same patient. The etiology of WD is unknown, but ultraviolet light, autoimmunity, viral infections, chemical carcinogens, and smoking have been postulated to play a role. Acquired genetic mutations in ATP2A2 gene has been postulated as supported by the absence of SERCA2 in immunohistochemistry but has not been reported in literature so far.

## Differential Diagnosis

- Common warts (verruca vulgaris)
- Follicular Keratosis (Darier's disease)
- Familial Benign Pemphigus (Hailey-Hailey Disease)
- Keratoacanthoma
- Actinic keratosis

## Treatment

The treatment modalities are surgical removal by excision and topical application of tazarotenic acid gel may provide successful results in the management of this dyskeratotic disorder<sup>8</sup>. But in our patient the lesions underwent spontaneous resolution.

No known risk of malignant transformation of warty dyskeratoma is reported. Recurrence is extremely uncommon<sup>10</sup>.

## Conclusion

- Not all warty lesions on scalp are common warts.
- The characteristic clinical and histopathological features of WD is distinctive.
- Multiple warty dyskeratomas on scalp are rare and reported in association with renal failure but our patient had normal renal function<sup>9,10</sup>. In summary, multiple WD is an exceptional entity that could be misdiagnosed and its diagnosis should lead us to rule out any possible renal involvement.

## Acknowledgement

We acknowledge Dr. Ramesh Rao, Prof. & HOD, Dept. of Pathology, Chettinad Hospital and Research Institute for his valuable contribution.

## References

- 1) Duray PH, Merino MJ, Axiotis C. Warty dyskeratoma of the vulva. *Int J Gynecol Pathol* 1983; 2: 286.
- 2) Graham J.H, Helwig E.B. Isolated dyskeratosis follicularis. *Archives of Dermatology (Chicago)* 1958; 77: 377-389.
- 3) Kaugars GE, Lieb RJ, Abbey LM. Focal oral warty dyskeratoma. *Int J Dermatol* 1984; 23:123-30.
- 4) Baran R, Perrin C. Focal subungual warty dyskeratoma. *Dermatology* 1997; 195:278.
- 5) Weedon D, ed. *Skin pathology*. Edinburgh: Churchill Livingstone, 2002; 47: 423.
- 6) Ackerman AB, Troy JL, Rosen LB, Jerasutus S, White CR, King DF. Warty dyskeratoma vs. squamous-cell carcinoma with acantholytic cells. In: *Differential diagnosis in dermatopathology II*. Philadelphia: Lea & Febiger, 1988: 90.
- 7) Panja RK. Warty dyskeratoma. *J Cutan Pathol* 1977; 4: 194
- 8) Abramovits W, Abdelmalek N. Treatment of warty dyskeratoma with tazarotenic acid. *J Am Acad Dermatol*. 2002;46:S4
- 9) Rocx M, Kavala M, Kocaturk E et al. Multiple warty dyskeratomas on the scalp. *Dermatol online J*. 2009;15:8
- 10) Griffiths TW, Hashimoto K, Sharata HH et al. Multiple warty dyskeratomas of the scalp. *Clin Exp dermatol*. 1997;22:189-191