

# Case Report

## Endodontic Management of a Mandibular Second Premolar with Two Roots and Three Canals

Sai Shamini\*, Padmini Govindasamy\*\*, Vidya KM\*\*\*

\*Reader, \*\*Prof. and HOD, Dept. of Conservative Dentistry and Endodontics, Madha Dental College, Chennai, India,

\*\*\*Reader, Dept. of Oral Pathology, Sathyabama University & Dental College, Chennai India.



Dr. Sai Shamini graduated in Dental Surgery at Ragas Dental College, Chennai, in 2000. She secured the III Rank in the TN State Post-graduate Entrance Examinations, held in 2001 and entered the hallowed portals of the Tamil Nadu Government Dental College and Hospital, Chennai to specialize in Conservative Dentistry & Endodontics. She has presented several scientific papers in National & International conferences and delivered guest lectures in Chennai. She has also contributed two chapters for the text book - "Materials used in Dentistry" - (Dr.S.Mahalakshmi). She is presently working as Reader, Department of Conservative Dentistry and Endodontics, Madha Dental College and Hospital, Chennai.

Corresponding author - Sai Shamini (sai.shamini@gmail.com)

### Abstract

The mandibular premolars exhibit variations in the number of roots and root canals. This presents with diagnostic difficulty and subsequent endodontic flare ups and failure. Precise location of additional canals is the key to successful endodontic management. In this article, we report a rare case of mandibular second premolar with two root canals and three roots in which a nonsurgical endodontic treatment was completed.

**Key Words:** Mandibular second premolar, Two roots, Three canals.

Chettinad Health City Medical Journal 2014; 3(3): 136 - 138

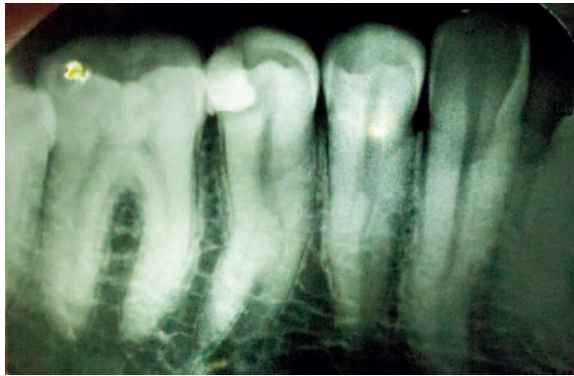
### Introduction

The knowledge and understanding of the normal root canal system and variations are of vital significance to clinicians. Accurate location, negotiation, cleaning, shaping and obturation of root canals determines the success of endodontic therapy<sup>1</sup>. Endodontic failure is common in mandibular premolars due to undetected additional canals as evidenced in literature<sup>1</sup>. Hoen and Pink reported 42% incidence of missed canals or roots in teeth requiring endodontic treatment<sup>2</sup>. This case presents the successful detection and endodontic treatment of a mandibular premolar with two roots and three canals.

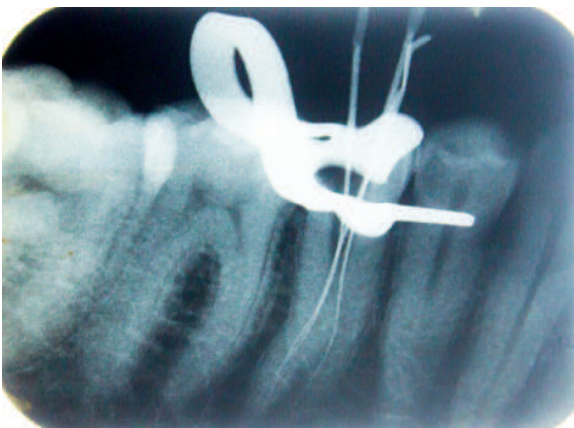
### Case report

A 38 year old male was referred for endodontic treatment by a general practitioner. The patient complained of pain in the left posterior part of his lower jaw since 3 weeks. The pain aggravated on drinking hot fluids and he had two episodes of nocturnal pain for a period of one week, which subsided on taking over-the-counter analgesics. Intra oral examination revealed a temporary filling in 35 with tenderness on percussion. Radiographic examination revealed a large distal cavity in 35 filled with a radioopaque filling material, involving the pulp (Fig 1A). The tooth showed two roots, mesial and distal, dividing at the mid root level. The mesial root exhibited a continuous radiolucent line suggesting one root canal. The distal root revealed a disappearing radiolucent line suggesting the presence of more than one canal. Widening of the periodontal ligament space was seen in relation to 35 (Fig 1A). The different root

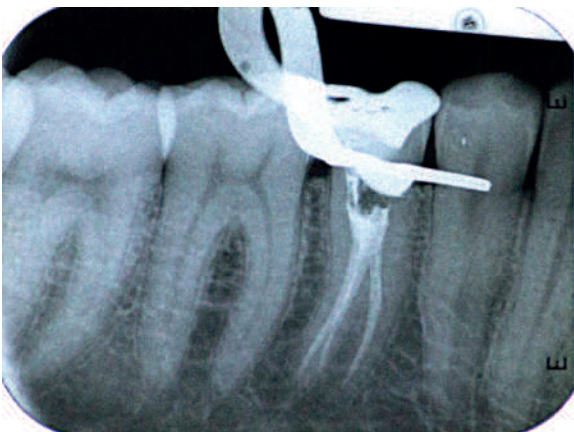morphology in tooth 34 was also noted in the Xray. After conducting clinical vitality tests, the diagnosis of acute irreversible pulpitis with apical periodontitis was made in 35. Root canal treatment was planned. Patient consent for the treatment was obtained. The tooth was anesthetized with 2% lidocaine solution by way of inferior alveolar nerve block on the left side. Subsequently, the tooth was isolated with rubber dam. The temporary restoration and remaining carious dentin was removed. Endodontic access was initiated with a high speed air-rotor handpiece and round diamond point. The canals were explored using size -08 K file (Dentsply Maillefer; Ballaigues, Switzerland). A mesial and a distal canal was promptly identified. Angulation of the file in the distal root seemed eccentric which necessitated further exploration. The exploration revealed that the distal root had two canals identified as distobuccal and distolingual (Fig 1B). The working length was determined with the help of an apex locator (Root ZX; Morita, Tokyo, Japan), which was confirmed with a radiograph. The canals were cleaned and shaped by the crown down technique with rotary ProTaper (Dentsply Maillefer, Ballaigues, Switzerland) with copious irrigation with 2.5% sodium hypochlorite and 17% EDTA. The canals were dried and a sterile cotton pellet was placed in the orifice and sealed with Cavit (Espe, Germany). One week later, the tooth was completely asymptomatic. The canals were irrigated with 17% EDTA and finally with 2.5% hypochlorite, dried and obturated with laterally condensed gutta-percha and AH Plus sealer (Dentsply, Maillefer). A final radiograph was taken to assess the quality of obturation (Fig 1C).



**Fig 1 A - Pre-operative radiograph**



**Fig 1 B - Three canals located**



**Fig 1 C - Obturation done with Guttapercha and AH PLUS sealer**

## Discussion

The root canal morphology of the mandibular second premolars can be highly variable and can often be challenging to the clinician even though it is typically described as a single rooted tooth with a single canal system<sup>3,4,5</sup>. Root canal studies by Vertucci et al reported that the mandibular second premolars had one root canal at the apex in 97.5% of the teeth studied and two canals in 2.5% ;the incidence of three root canals were scarce<sup>6</sup>. A literature review of eight anatomic studies of 4019 mandibular second premolar teeth by Cleghorn et al (2007) reported 99.6% with a single root, 0.3% with two roots and 0.1% with three roots which was rare and documented in case reports<sup>3</sup>. A review of eleven anatomic studies of root canal

systems comprising 3063 teeth show that 91% of teeth had one canal and two or more canals were present in 9% of the teeth<sup>3</sup>. Kottor J et al(2013) performed a systematic review and reported that 99.28% of mandibular premolars have a single root with a single canal (86.9%),two roots were found in 0.61% of the mandibular premolars studied.Variations were attributed to ethnicity of populations, gender predilections and possibly genetics<sup>5,7</sup>. In their review they enumerated the second premolar variations in thirty six cases stating that they presented with one root and 3,4,5 canals, 2 roots with 2,3,4 canals and a case with 4 roots with 4 canals. Only eleven out of the studied thirty six teeth had two roots and three canals as presented in this case. Various diagnostic methods were used in the case reports to assess the anatomy of root canals<sup>7</sup>.Simple, cost effective techniques like intraoral periapical radiographs to more sensitive techniques CBCT: cone beam computed tomography, Micro-CT: microcomputed tomography, SCT: spiral computed tomography have been used<sup>7,8</sup>. The present case was diagnosed by careful study of the intra oral radiograph and its interpretation of disappearing canal space to suspect more than one canal. Tactile exploration and clinical indications such as file direction in the canal helped in locating the canals. The use of rotary instruments helped in producing the final shaping of the canals<sup>9</sup>.

## Conclusion

Mandibular second premolar tooth with anatomic variations in the root canal system can be effectively diagnosed with high quality radiographs taken at different horizontal angulations and proper interpretation, visual inspection of the floor of the chamber and careful tactile exploration under good illumination. The use of magnification and aids such as CBCT, Spiral CT and Micro-CT can help in understanding the presence of anatomic variations to a great extent facilitating successful endodontic treatment.

## References

- 1) Sachdeva GS, Ballal S, Gopikrishna V, Kandaswamy D. Endodontic management of a mandibular second premolar with four roots and four root canals with the aid of spiral computed tomography: a case report. *Journal of Endodontics*. 2008;34(1):104-107
- 2) Hoen MM, Pink FE. Contemporary endodontic retreatments: An analysis based on clinical treatment findings. *J Endod* 2002;28:836-6
- 3) Cleghorn BM, Christie WH, Dong CCS. The root and root canal morphology of the human mandibular second premolar: a literature review. *Journal of Endodontics*. 2007;33(9):1031-1037.
- 4) Ingle JI, Bakland LK, Baumgartner JC. *Ingle's Endodontics*. 6th edition. Ontario, Canada: BC Decker; 2007.
- 5) Prakash R, Nandini S, Ballal S, Kumar S, Kandaswamy D. Two-rooted mandibular second

premolars: case report and survey. Indian Journal of Dental Research. 2008;19(1):70-73.

- 6) De Moor RJ, Calberson FL. Root canal treatment in a mandibular second premolar with three root canals. J Endod 2005;31:310-3.
- 7) Kottoor J, Albuquerque D, Velmurugan N, Kuruvilla J. Root anatomy and root canal configuration of human permanent mandibular premolars: a systematic review. Anatomy Research International. 2013;14 pages.
- 8) Denzil Albuquerque, Jojo Kottoor, and Mohammad Hammo. Endodontic and Clinical Considerations in the Management of Variable Anatomy in Mandibular Premolars: A Literature Review. Biomed Res Int. 2014; 512-574
- 9) Rödiger T, Hülsmann M. Diagnosis and root canal treatment of a mandibular second premolar with three root canals. International Endodontic Journal. 2003;36(12):912-919.

#### Hand Dryers or Paper towels?

When you visit a public toilet, do you dry your hand with warm air hand dryer or with lowly paper towels? You might be tempted to say "hand dryers" as they seem apparently clean. But you might be wrong. In a new study conducted in University of Leeds, employing a cleverly designed experiment, the investigators found that bacterial counts around Hand Dryers were 27 times higher than the counts in the air around paper towel dispensers. Even among the hand dryers, jet air hand dryer was much worse than warm air hand dryer. In addition, the bacteria were found to persist for up to 15 minutes in the air around hand dryers. So, next time you visit a public toilet, use paper towel to dry your hands. If you choose hand dryers, you might be inadvertently spreading the bacteria. (E.L. Best, P. Parnell, M.H. Wilcox. Microbiological comparison of hand-drying methods: the potential for contamination of the environment, user, and bystander. Journal of Hospital Infection, 2014; DOI: 10.1016/j.jhin.2014.08.002)

- Dr. K. Ramesh Rao