

# Original Article

## Analysis and relevance of electroencephalographic changes in intracranial Space Occupying Lesions (ICSOL)

Karthikeyan K V\*, Subramaniam K\*\*, Richard I\*\*\*

\* Associate Professor & Senior Consultant, Department of Neurosurgery,\*\* HOD & Chief Consultant, \*\*\* AHS Intern, Department of Neurology, Chettinad Super Speciality Hospital, Chettinad Academy of Research & Education, Kelambakkam, Chennai, Tamilnadu, India.



Dr.K.V.Karthikeyan has been working in the Department of neurosurgery of Chettinad Super Speciality Hospital since 2010 as Senior Consultant Neurosurgeon. He finished his MBBS and MCH Neurosurgery from the Madras Medical College in 2006. He is very well trained in Microneurosurgery and Endoscopic Neurosurgery. He is specialised in Skull base and cerebrovascular surgery with special interest in Paediatric Neurosurgery. He was awarded FMMC in 2010 from the prestigious Madras Medical College.

Corresponding author - : Dr. Karthikeyan K V (surgenn@gmail.com)

Chettinad Health City Medical Journal 2020; 9(1): 39 - 43

DOI: [https://doi.org/10.36503/chcmj9\(1\)-07](https://doi.org/10.36503/chcmj9(1)-07)

### Abstract

**Introduction:** The term "intracranial space occupying lesions" is defined as any neoplasm, benign or malignant, primary or secondary, as well as any inflammatory or parasitic mass lying within the cranial cavity. It also includes hematomas, different types of cysts, & vascular malformations. Widely available imaging techniques, Computed Tomography (CT) & Magnetic Resonance Imaging (MRI) are used to detect these lesions.

**Aim:** To analyse the role of Electroencephalographic changes and its relevance in Intracranial Space Occupying Lesion.

**Objective:** To Analyse the EEG changes in intracranial space occupying lesion patients and to identify those EEG changes that are specific to lesions and their location.

**Methods and Materials:** This is observational cross sectional study conducted among the patients who had ICSOL in a tertiary care hospital over a period of 6 months. Participants who were diagnosed with Radio-Imaging such as CT/MRI were recruited from the Neurosurgery OPD. Subjects are enquired about their history of diagnosis, family history, investigations & diagnostic tests such as electroencephalography.

**Results:** Out of 40 patients the prevalence of ICSOL is more common in Female gender than Male. ICSOL is more common in middle aged group of 31-50 years of age. Out of 40 migraine participants 25 had normal EEG waveforms, 14 had slow wave discharges, 1 had sharp wave discharges and no spike wave discharges. In the present study, EEG abnormality in patients with ICSOL is reported in 15(37.5%) patients. All 15 patients were reported to have slow wave discharges that are a part of their normal background activity. A greater proportion of the patients 25(62.5%) in spite of extensive and deep seated lesions has no focal or generalized abnormal wave forms added to their normal background activity.

**Conclusion:** In the present study although one third of the ICSOL patient had changes in EEG, they are nonspecific and their association is not statistically significant.

**Key words :** Space occupying Lesion- Electroencephalography- slow waves.

### Introduction

Intracranial space occupying lesions are found to be in brain and its associated structures that are at times fatal and morbid. According to the underlying pathology involved, probability of the site of origin and progression of the lesion in the cranial cavity is/are determined. It is highly notorious to state that ICSOLs are deadly due to poor prognosis and late diagnosis and to highlight this quote, the clinical examination of the participants to a greater extent

reported the only common Symptom<sup>1</sup> of Headache that has a greater differential diagnoses as well. They vary from congenital to acquired lesion and benign to malignant and many vascular lesions as well.<sup>2</sup> They commonly present as headache, seizure or any neurological deficits and are usually diagnosed with CT or MRI with contrast.

An electroencephalogram is a test used to evaluate the electrical activity in the brain.<sup>3-5</sup> EEG is generated by the nerve cells of the cerebral cortex which

line the surface of the hemispheres. The fluctuations of electrical potential recorded in the scalp, EEG reflect changes of a steady electrical charge on the cell membrane induced by impulses arriving from the other cells. The International 10-20 system of electrode placement provides uniform coverage of entire scalp. It uses the distance between bony landmarks of the head to generate a system of lines which run along and across the head and intersect at the intervals of 10 or 20 % of their total length. The standard set of electrodes for adults consist of 21 electrodes and one ground electrode. The recording electrodes are named with a letter and a subscript.

EEG used to be somewhat reliable in localizing lesions involving superficial portions of the cerebral hemispheres, though it is of limited value in deep-seated lesions. The role of EEG in detecting focal cerebral disturbances has undergone a significant change since the development of CT scan and MRI. EEG provides the only continuous measure of cerebral function over time and is the diagnostic test of choice regarding seizures and epilepsy which is common with brain tumors. This study is to evaluate the ICSOL on Neuro-imaging & correlate the electrophysiological (EEG) findings with the radiological assessment.

G.V. Iyer et al has made a detailed significant study on Electroencephalography in Intracranial Space Occupying Lesions and a Comparison of it with other Investigative procedures states that EEG has been recognized as one of the valuable non-traumatic diagnostic procedure for diagnosing ICSOL, particularly those in cerebral hemisphere.<sup>6</sup> This study inspired us to do EEG analysis in our patient.

## Methods and Materials

This is an Observational Cross Sectional Study and the objectives were to study the variations of pattern in electroencephalogram in intracranial space occupying lesions. There were a total of 40 participants. The participants were taken from Neuro-surgery unit of a tertiary care hospital. They were aged between 18-67 years old including both male and females. All the Patients who were diagnosed with ICSOL with Radio imaging study were included in this study. Patients who had seizures previously were excluded from this study.

Patients who fit in the selection criteria were explained about the study and a written consent was obtained from those who were willing to participate in the study. All the needed information was collected using a pre-tested semi structured questionnaire. Investigations were carried out in

each case. Data was entered into Microsoft excel data sheet and was analyzed using IBM-SPSS 21 version software. Categorical data was represented in the form of Frequencies and proportions. Chi-square was used as test of significance. Continuous data was represented as mean and standard deviation. Independent t-test was used as test of significance to identify the mean difference between two groups. p value <0.05 was considered as statistically significant.

## Results

The demographic characteristics such as gender distribution and age of the study population are shown in Figures 1&2, respectively. Among the 40 participants, 17(42.5%) were men and 23(57.5%) were women. Out of 40 participants, the maximum of participants lie between the age group of 31-50 years and minimum of the age of 11-20 years.

EEG changes were predominantly seen with meningiomas and least in adenomas (Fig 3). Fig 4 is Graphical representation of yield of EEG diagnosis with various ICSOL showing highest prevalence in females who suffers meningioma. Most of the EEG

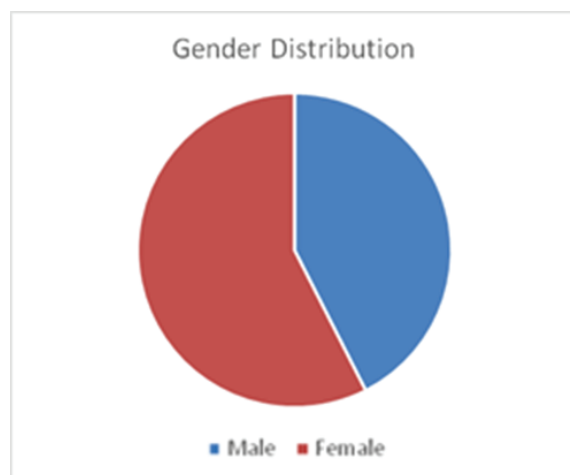


Figure 1: Pie chart representing the gender distribution

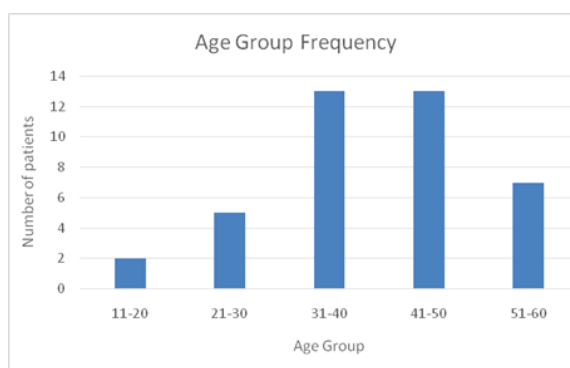


Figure 2: Represents Age group frequency

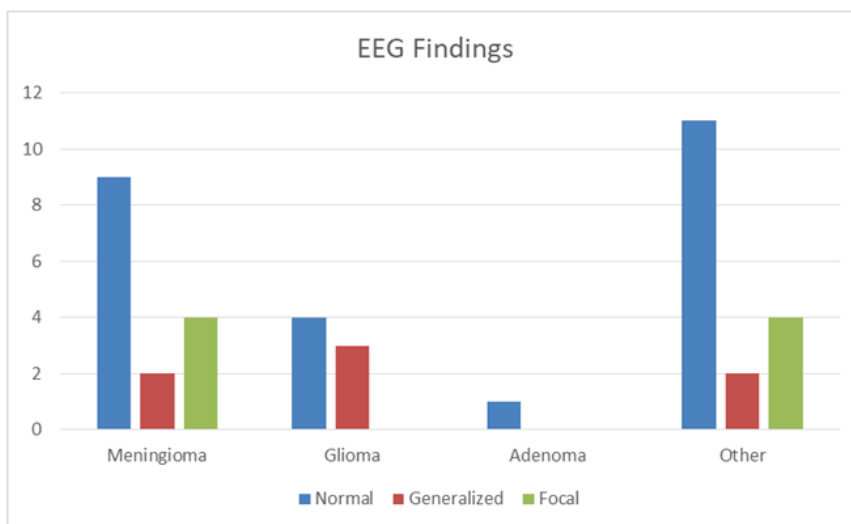


Figure 3: Graphical representation of EEG Findings in various ICSOL

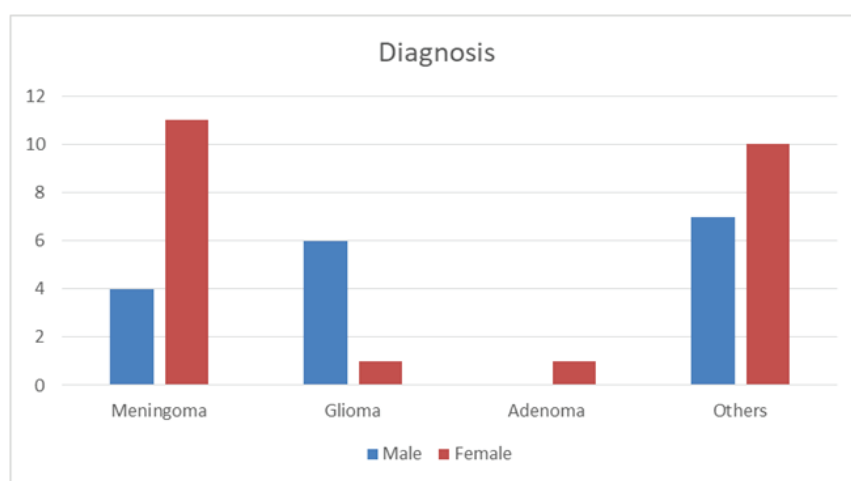


Figure 4: Graphical representation of yield of EEG diagnosis with various ICSOL

The diagnostic efficacy of the test is mentioned in Figures 5, 6, 7 & 8.

Test	Disease Present		Disease Absent		Total
	Present	n	Absent	n	
<b>Positive</b>	True Positive	a=15	False Positive	c=0	a + c = 15
<b>Negative</b>	False Negative	b=25	True Negative	d=0	b + d = 25
<b>Total</b>		a + b = 40		c + d = 0	

Figure 5: Data showing True-positive and False-negative representations

change we observed was diffuse non specific slow waves. Slow waves were predominantly seen in patients with Meningiomas. Patients with meningiomas and gliomas showed EEG changes than with adenoma and other lesions (Fig 3).

### Discussion

Out of the 40 patients predominantly female were seen and mostly middle aged persons were affected though the age range was from 10 to 60 were included in study. Various lesions were included in

Statistic	Formula	Value	95% CI
Sensitivity	$\frac{a}{a + b}$	37.50%	22.73% to 54.20%
Specificity	$\frac{d}{c + d}$		
Positive Likelihood Ratio	$\frac{\text{Sensitivity}}{1 - \text{Specificity}}$	0.38	
Negative Likelihood Ratio	$\frac{1 - \text{Sensitivity}}{\text{Specificity}}$		
Disease prevalence	$\frac{a + b}{a + b + c + d}$	100.00% (*)	91.19% to 100.00%
Positive Predictive Value	$\frac{a}{a + c}$	100.00% (*)	
Negative Predictive Value	$\frac{d}{b + d}$	0 (*)	
Accuracy	$\frac{a + d}{a + b + c + d}$	37.50% (*)	22.73% to 54.20%

Figure 6: Tabular representation of specificity and accuracy of 37.5%

**Test for one proportion calculator**

**Observed proportion**

Observed proportion (%):

Sample size:

**Null hypothesis value**

Null hypothesis value (%):

Figure 7: Represents null hypothesis value

**Results**

Z-statistic	2.905
Significance level	P = 0.0037
95% CI of observed proportion	22.73 to 54.20

Figure 8: Tabulation showing P value.

the study though Meningiomas were predominantly seen. Out of the 40 patients, 25 had a normal wave-form in EEG. They didnot show any abnormality whatsoever. Remaining 15 had abnormal EEG wave-forms of which 14 had slow wave discharges, 1 had sharp wave discharges and no spike wave discharges. In the present study, EEG abnormality in patients with ICSOL is reported in 15(37.5%) patients. All 15 patients were reported to have slow wave discharges that are a part of their normal background activity. A greater proportion of the patients 25(62.5%) in spite of extensive and deep seated lesions has no focal or generalized abnormal wave forms added to their normal background activity. The study shows significant p value of 0.0037.

Though EEG has been useful and show changes in tumors when they present with seizure. Surprisingly when the same pathological lesion at the same location presents without seizure and with other symptoms, there is no significant EEG abnormality.

## Conclusion

EEG changes are very well seen when intracranial lesion presents as seizures. In our study majority of the patients showed normal wave pattern. Though 40 percent of the patients showed abnormal changes in EEG they were more of non specific and didnot follow any specific pattern or related to tumor pathology or tumor location. Patient without seizure as presentation rarely shows any specific EEG changes. So we concluded that the relevance of EEG to intra cranial SOL is statistically not significant and may be a higher sample might give a detailed insight in this perspective.

## References

1. Garel C. MRI of the Fetal Brain. Springer2004.
2. Dastur DK, Lalitha VS, Prabhakar V. Pathological analysis of intracranial space-occupying lesions in 1000 cases including children. 1. Age, sex and pattern; and the tuberculomas. *J Neurol Sci.* 1968;6(3):575-592.
3. Fisch BJ. Fisch &Spehlmann's EEG Primer 3rd Edition: Basic Principles of Digital and Analog EEG 1999.
4. Soomro BA, Khalid S, Alvi S. Analytic study of clinical presentation of intracranial space-occupying lesions in adult patients. *Pakistan J Neurol Sci.* 2014;9(3):1-3
5. Ejaz BM, Saeed AK, Naseer AC, Qureshi GR. *Biomedica*Vol. 21, Jan.– Jun., 2005/Bio-6
6. Iyer GV, Raman PT, Taori GM. Electroencephalography in intracranial space occupying lesions and a comparison of it with other investigative procedures. *Acta Neurochir (Wien).* 1973;29(1):105-21.