

Case Report

Tuberous Sclerosis Masquerading as Febrile Seizure – A Case Report

Deepti Pandit*, Francis Reena F J**, Sujatha Sridharan***

*Senior resident, **Post Graduate Students, ***Professor, Department of Paediatrics, Chettinad Hospital & Research Institute, Chennai, India.



Dr. Deepti Pandit, completed her undergraduate training from Bangalore Medical College And Research Institute and her M.D. Pediatrics from All India Institute of Medical Sciences. She has presented papers and posters at national and international conferences. She is currently working as Senior Resident in Chettinad Hospital and Reseach Institute.

Corresponding author - Dr. Deepti Pandit (doc.deeptipandit@gmail.com)

Chettinad Health City Medical Journal 2016; 5(2): 84 - 87

Abstract

Tuberous sclerosis complex (TSC) is an inherited genetic disorder that has an autosomal dominant inheritance. It can affect almost all organ systems in the body but manifestations may vary widely among individuals. Here we discuss the case of a 11 month old infant who presented with fever and seizures, initially suspected to be febrile seizures. But a detailed head to toe examination revealed multiple hypomelanotic macules and brain imaging showed subependymal nodules and cortical tubers confirming the diagnosis of tuberous sclerosis. Through this case we would like to highlight the importance of a thorough clinical examination for neurocutaneous markers, having a high index of suspicion and neuroimaging in the early diagnosis of TSC.

Key Words: Tuberous Sclerosis, Seizures

Abbreviations:

TSC- Tuberous sclerosis complex

SEGA- Subependymal giant cell astrocytomas

mTOR- mammalian target of rapamycin

Introduction

Tuberous sclerosis complex (TSC) is an inherited autosomal dominant condition with variable expression. It is a disorder of cellular differentiation, proliferation, and migration early in development, resulting in a variety of hamartomatous lesions which affects the brain, skin, kidneys, heart and other organs. The incidence of TSC is estimated to be between 1/6000 to 1/10,000 live births and a population prevalence to be around 1 in 20,000^{1,2}.

The hallmark of TSC is central nervous system involvement, but any organ system can be affected. The well-known cutaneous manifestation of TSC is adenoma sebaceum, which is a cutaneous hamartoma and usually does not appear until early adolescence. In some, TSC may present in infancy with cardiac rhabdomyoma or seizures, while in other affected individuals it may be diagnosed only in adolescence or adult life. There is a striking variability of clinical expression and the diagnosis of TSC is occasionally difficult, especially in those with subtle findings³. The age dependent appearance of the characteristic clinical features in TSC, presents challenges for the diagnosis in infancy.

Here we present a case of TSC presenting in infancy with seizures and hypomelanotic macules that signifies the importance of having a high index of suspicion and neuroimaging for diagnosis of the condition in infancy.

Case Report

A 11 month old female infant, second born to non-consanguineously married couple, with normal developmental milestones presented to the paediatric casualty with 2 episodes of left sided focal seizures and history of fever for 2 days. The seizure was controlled with a single dose of midazolam and she recovered from the post ictal state within half hour. The vital parameters and neurological examination were within normal limits. Our initial diagnostic possibilities were febrile seizure and meningitis. Work up in the form of blood counts, serum electrolytes, blood glucose, cerebrospinal fluid analysis and electroencephalogram were within normal limits.

However a detailed head to toe examination of the baby revealed 8 hypomelanotic macules over the face, chest, thigh and buttocks with the largest measuring 3cm x 1 cm (Fig 1). Thus a possibility of a neurocutaneous syndrome was kept in mind and neuroimaging done. Non-contrast Computerized Tomography brain showed multiple subependymal calcified nodules adjacent to the bilateral lateral ventricles representing subependymal hamartomas, and hypointense areas in frontal areas suggestive of cortical tubers (Fig 2). MRI brain revealed multifocal, T2 hyperintense areas in the subcortical aspect of bilateral cerebral hemispheres representing cortical tubers (Fig 3). Child was diagnosed with Tuberous Sclerosis as 3 major criteria were fulfilled (cortical tubers, subependymal nodule, more than 3 hypomelanotic macules). Further investigations were undertaken to look for

involvement of other organ systems in the form of ultrasound abdomen, echocardiography, dental, skeletal and ophthalmological evaluation which did not reveal any abnormality. The child was started on oral valproate for seizure control and discharged with advice for regular follow up.

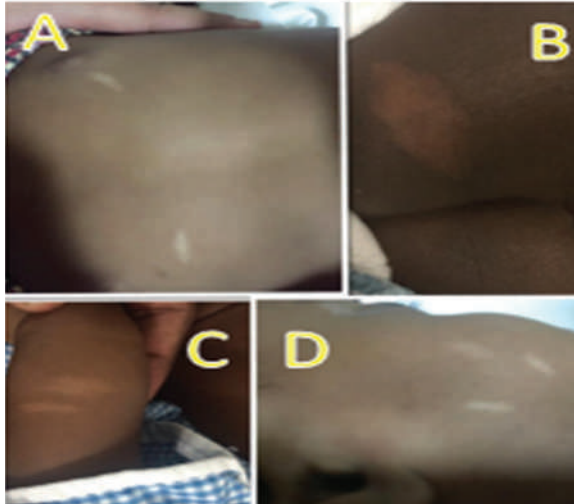


Figure 1 - Hypomelanotic macules noted over the chest(A) , Buttock (B), Arm (C) , Face (D)

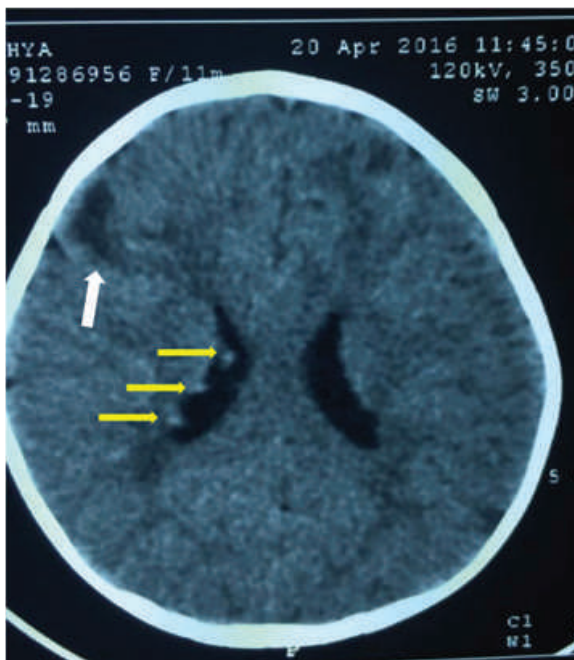


Figure 2 - CT Brain showing multiple subependymal nodules (yellow arrow) and cortical tuber (white arrow)

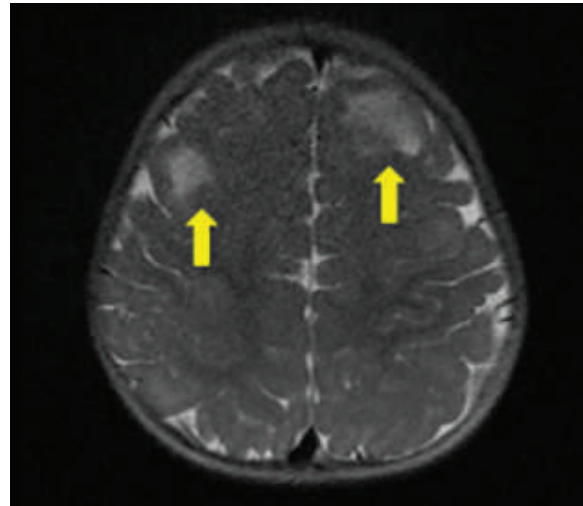


Figure 3 - MRI Brain showing T2 hyperintense areas in B/L subcortical region in frontal hemispheres.

Discussion

Tuberous sclerosis complex (TSC) is a progressive neurocutaneous disorder that involves multiple organs mainly brain, heart, kidney, lung, liver, skin and eye^{4,5}. It was first described as "sclerose tubereuse" by Bourneville in 1880. In 1908, Vogt described the triad of intractable epilepsy, mental retardation, and adenoma sebaceum. TSC is now known to be a genetic disorder that is inherited in an autosomal dominant manner.

Mutation in one of the two tumour suppressor genes is responsible for tuberous sclerosis: TSC1 on chromosome 9q34, which encodes the protein hamartin and TSC2 on chromosome 16p13.3 which encodes the protein tuberlin. Both of these proteins act together as a unit via mTOR signalling pathway⁶.

TSC is a heterogeneous disease with wide clinical spectrum even within the same family and individuals carrying same mutation. The age dependent appearance of various clinical features poses a challenge to early diagnosis, like in the index case. Diagnosis is based on the updated 2012 criteria⁷ as in table 1.

Table 1 - Updated diagnostic criteria for tuberous sclerosis complex 2012

A. Genetic diagnostic criteria

The identification of either a TSC1 or TSC2 pathogenic mutation in DNA from normal tissue is sufficient to make a definite diagnosis of tuberous sclerosis complex (TSC).

Note that 10% to 25% of TSC patients have no mutation identified by conventional genetic testing, and a normal result does not exclude TSC, or have any effect on the use of clinical diagnostic criteria to diagnose TSC.

B. Clinical diagnostic criteria	
Definite diagnosis:	Two major features or one major feature with 2 minor features
Possible diagnosis:	Either one major feature or 2 minor features
Major features	
	<ol style="list-style-type: none"> 1. Hypomelanotic macules (3, at least 5- mm diameter) 2. Angiofibromas (3) or fibrous cephalic plaque 3. Ungual fibromas (2) 4. Shagreen patch 5. Multiple retinal hamartomas 6. Cortical dysplasias 7. Subependymal nodules 8. Subependymal giant cell astrocytoma 9. Cardiac rhabdomyoma 10. Lymphangiomyomatosis (LAM) 11. Angiomyolipomas (2)
Minor features	
	<ol style="list-style-type: none"> 1. "Confetti" skin lesions 2. Dental enamel pits (>3) 3. Intraoral fibromas (2) 4. Retinal achromic patch 5. Multiple renal cysts 6. Non renal hamartomas

Central nervous system involvement is classical of TSC. Most common neurologic manifestations are epilepsy, cognitive impairment and autism⁸. Cortical tuber is the characteristic lesion best diagnosed in MRI. Subependymal nodules are usually asymptomatic lesions that are calcified and found projecting into the lateral ventricle, giving the 'candle dripping' appearance. But they can grow into subependymal giant cell astrocytoma (SEGA) that can cause hydrocephalus by obstruction. Studies show that neuroimaging resulted in a definitive diagnosis of tuberous sclerosis complex in 95% of patients in infancy⁹.

Skin manifestations include, Hypomelanotic macules, that usually appear at birth and are found in about 90% of individuals. Facial angiofibromas occur in about 75% of TSC patients between ages 2 and 5 years. Shagreen patches are commonly seen as large plaques on the lower back with a bumpy or orange-peel surface and is specific for TSC. Confetti skin lesions are numerous 1- to 3- mm hypopigmented macules scattered over the body. During adolescence or later, subungual fibromas may form⁷.

Cardiac rhabdomyoma may be the presenting sign of TSC in early infancy and is seen in 50% children. Around 50% of patients have ocular abnormalities in the form of retinal astrocytomas. Renal manifestations are seen in 75- 80% of children > 10 years of age in the form of angiomyolipoma which are usually benign. Pulmonary involvement occurs almost always in women aged 30 or older, in the form of multifocal micronodular pneumocyte hyperplasia, pulmonary cysts and lymphangiomyomatosis. Other manifestations include pitting of the dental enamel, bone cysts, hamartomas of stomach, intestine, and colon⁷.

Medical management with mTOR inhibitor, everolimus, is effective for Subependymal Giant Cell Astrocytoma, renal angiomyolipoma, lymphangiomyomatosis and facial angiofibroma. Routine follow up of affected individuals with MRI brain and renal MRI every 1 - 3 years, neurodevelopmental screening at key developmental stages, yearly dermatologic and ophthalmologic evaluation and bi - annual dental evaluation is recommended¹⁰.

In conclusion, we would like to emphasise the importance of a thorough general physical examination and having a high index of suspicion for neurocutaneous syndrome among primary care physicians and paediatricians in order to diagnose these disorders early. Care must be exercised in looking for neurocutaneous markers like café-au-lait spots, hypomelanotic macules, cutaneous hamartomas, axillary freckling, subungual fibromas, facial hemangioma, nevi, pigmentary changes etc in all children presenting with epilepsy. Neuroimaging should be done in all suspected cases as it is the preferred modality for diagnosing TSC in infancy. Early diagnosis and regular follow up would significantly improve the outcome and quality of life in these children.

Conflict of interest-The authors have no conflicts of interest relevant to this article to disclose.

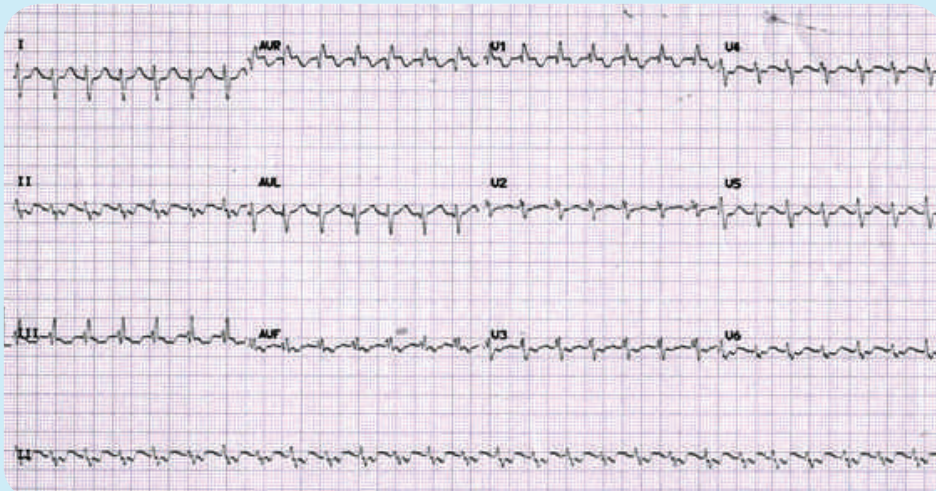
References

- 1) O'Callaghan F, Shiell A, Osborne J, Martyn C. Prevalence of tuberous sclerosis estimated by capture-recapture analysis. *Lancet*. 1998;352: 318-319.
- 2) Sampson J, Scahill S, Stephenson J, Mann L, Connor J. Genetic aspects of tuberous sclerosis in the west of Scotland. *J Med Genet*. 1989;26: 28-31.
- 3) Roach ES, Sparagana SP. Diagnosis of tuberous sclerosis complex. *J Child Neurol*. 2004;19:643-49.
- 4) Atalay, S, Aypar, E, Uçar, T, Altuğ, N, Deda, G, Teber, S, et al Fetal and neonatal cardiac rhabdomyomas: Clinical presentation, outcome and association with tuberous sclerosis complex. *Turk JPediatr*, 2010;52, 481-7

- 5) Franz, D N, Bissler JJ, McCormack. F X. Tuberous sclerosis complex: neurological, renal and pulmonary manifestations. *Neuropediatrics*. 2010; 41 (5), 199 - 208.
- 6) Nobukini T, Thomas G. The mTOR/S6K signalling pathway: the role of the TSC1/2 tumour suppressor complex and the proto-oncogene Rheb. *Novartis Found Symp*. 2004. 262:148-54.
- 7) Northrup H, Krueger DA. Tuberous sclerosis complex diagnostic criteria update: recommendations of the 2012 international Tuberous Sclerosis Complex Consensus Conference. *Pediatr Neurol*. 2013 Oct. 49 (4): 243 - 54.
- 8) Kliegman, Stanton, St. Geme, Schor, Behrman. *Nelson Textbook of Pediatrics*, 20 e. Elsevier. Saunders. 2016
- 9) Datta AN, Hahn CD, Sahin M. Clinical presentation and diagnosis of tuberous sclerosis complex in infancy. *J Child Neurol*. 2008 Mar;23(3):268-73
- 10) Krueger DA, Northrup H. Tuberous Sclerosis Complex Surveillance and Management: Recommendations of the 2012 International Tuberous Sclerosis Complex Consensus Conference. *Pediatr Neurol*. 2013 Oct. 49(4): 255-65

Diagnose the condition

A 26 year old female with complaints palpitations for 6 hours



Dr. M.Chokkalingam, Consultant Cardiology, CSSH.

Answer in page : 102