

Case Report

A Rare Combination of Stomatocytosis with Abnormal Blood Lipids and Gilbert's Syndrome

Vigneshwaran J*, Malligai E**, Rajasekaran D***, Mohammed Noor****

*Associate Professor, Department of General Medicine, **Professor & HOD, Department of Biochemistry, ***Professor & HOD, Department of General Medicine, ****Post-Graduate, Department of General Medicine, Chettinad Hospital & Research Institute, Chettinad Academy of Research & Education, Chennai, India.



Dr. J. Vigneshwaran did his MBBS from Stanley Medical College and DNB (General Medicine) from Madras Medical College, Chennai. He is at present working as Associate Professor in the Department of General Medicine, Chettinad Hospital & Research Institute, Chennai

Corresponding author - Vigneshwaran J (drvigneshwaran2003@gmail.com)

Chettinad Health City Medical Journal 2017; 6(1): 27 - 29

Abstract

Stomatocytosis is a rare hemolytic disorder occurring due to abnormal lipid bilayer of RBC membrane. In a suspected hemolytic disorder, unconjugated hyperbilirubinemia out of proportion to drop in hemoglobin suggests a probable underlying Bilirubin uptake/ metabolism problem in liver. Gilbert's syndrome is the commonest among them. Though genetic testing can be used to confirm it, it is generally a clinical diagnosis in a patient with indirect hyperbilirunemia and normal liver and hematological tests. Single dose Rifampicin test may be used for confirming the diagnosis. Association of abnormal serum lipids and RBC lipids have been found in Abetalipoproteinemia in which Acanthocytes (spur cells) are seen. Here we present a 25 years male who had abnormally low serum lipid levels and stomatocytes presenting as hemolytic jaundice.

Key Words: Stomatocytosis, Stomatocytes, Hemolysis, Hyperbilirubinemia, Gilbert's syndrome, Peripheral smear, Lipids

Introduction

Red Blood Cell (RBC) membrane is made of lipid bilayer, cytoskeletal proteins and carbohydrates. Abnormalities in the lipid bilayer cause alteration in RBC shape, fluidity and in its permeability to water and ions. Lipid bilayer is made of cholesterol and phospholipid in nearly equal proportions. Abnormalities in inner lipid layer produces stomatocytes while outer lipid layer produces Acanthocytes (spur cells) and Echinocytes (burr cells)¹. Stomatocytes are RBCs having a large wide central pallor resembling a transverse-slit or stoma. Acanthocytes are seen in patients with Abetalipoproteinemia, characterised by absent apo B lipoproteins and in patients with severe liver disease¹.

Hemoglobin Concentration (MCHC) – 32.7gm/dl, Red cell distribution width (RDW) – 14.8%, Total count (TC) 7200 cells per cu mm, Differential Count (DC) – Polymorphs - 67%, Lymphocytes- 27%, Eosinophils- 3%, Monocytes - 3%.

Peripheral Smear showed normocytic normochromic RBCs with multiple Stomatocytes (more than 40% of RBCs), as shown in Fig 1.

Liver function tests (LFT) -

Total Serum Bilirubin - 4.3 mg/dl, Direct Bilirubin - 0.13 mg/dl, SGPT - 35 IU, SGOT - 47 IU, SAP - 134 IU, GGT - 23 IU, Total protein – 7.8 g/dl, Serum Albumin – 4.4 g/dl, Globulin – 3.4 g/dl. Reticulocyte Count – 3.8, Reticulocyte Index - 3.2, LDH – 436, Serum Uric

Case Report

A 25 year old male presented with recurrent episodes of jaundice for past 6 years. He remembers a history of anemia with Hemoglobin around 9gm % in childhood. There was no history of high colored urine, clay colored stools or pruritus. There was no family history of recurrent anemia or jaundice. On examination, he had no pallor; Icterus was present and no pedal edema. He had no hemolytic facies. Vitals were stable. Respiratory and cardiovascular system examination was normal. Abdomen examination showed no organomegaly, but Traube's space was obliterated.

Investigations

The below mentioned investigations were done. Hemoglobin(Hb) – 12.8gm/dl, Mean Corpuscular Volume (MCV) – 92.3fl, Mean Corpuscular Hemoglobin (MCH) – 30.2pg/cell, Mean Corpuscular

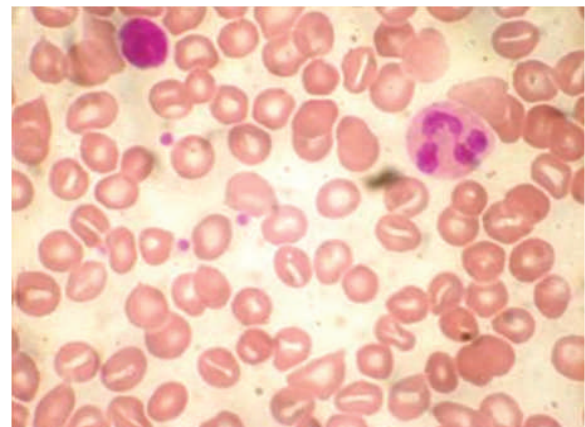


Fig 1 : Peripheral smear picture showing stomatocytes

acid – 7.8 mg/dl, Serum Haptoglobin – 0.171g/dl (0.3-2g/dl), Osmotic Fragility Test – normal, Coomb's test – negative, Hb electrophoresis – normal with HbF concentration – 0.5%, HbA2 Concentration – 2.6%.

USG Abdomen showed Moderate splenomegaly, no gallbladder calculi. Blood group A positive.

HBsAg, Anti HCV and HIV were Negative.

Lipid Profile - Total cholesterol -20 mg/dl, HDL - 0 mg/dl, TGL - 115mg/dl. Measured LDL level -21 mg/dl.

Apo lipoprotein levels - Apo A - 20.1 mg/dl (110-205mg/dl), Apo B - 39.9 mg/dl (55- 140 mg/dl). Lipid Electrophoresis - showed a faint band in VLDL area, no bands in any other area

Serum Bilirubin pre & post oral intake of 900 mg of Rifampicin

- Pre rifampicin - Total -3.4mg/dl, direct -0.16 mg/dl
- Post rifampicin - Total - 6.6mg/dl, direct - 0.64 mg/dl

Discussion

Recurrent jaundice from childhood due to unconjugated hyperbilirubinemia can be due to hemolytic jaundice or congenital hyperbilirubinemias. Gilbert's syndrome, common among the congenital indirect hyperbilirubinemia is a benign autosomal dominant condition occurring due to defect in uptake and conjugation of indirect bilirubin. Serum bilirubin always remains around 3mg/dl and commonly does not exceed 4 mg/dl unless there is a stressful state like fasting, intercurrent illness or if there is a hemolytic disorder in addition². Bilirubin elevation more than 1.5 mg/dl from the baseline, 4- 6 hours after administration of 900 mg of Rifampicin can be used as a diagnostic test for Gilbert's Syndrome³. On the other hand, Crigler - Najjar is a more serious disease having a much higher bilirubin levels which manifests as kernicterus in childhood.

In our patient, serum bilirubin was usually around 4 mg/dl and it increased from 3.4 to 6.6mg/dl, 6 hours after a single oral dose of 900 mg of Rifampicin suggesting the diagnosis of Gilbert's Syndrome.

Our patient also had evidence for hemolytic jaundice in the form of mild anemia, splenomegaly, elevated reticulocyte index, LDH and uric acid, reduced Haptoglobin and peripheral smear showing plenty of Stomatocytes.

A Bilirubin of 4.3mg/dL in a patient with Hb of 12.8g/dL suggested jaundice out of proportion to anemia. This suggested a combination of hemolytic jaundice due to stomatocytosis along with an underlying Gilbert's syndrome

Other causes of stomatocytosis like Rh null phenotype, RBCs with no Rh Ag namely (D,d,C,c,E,e) was ruled out⁴. Our patient had "A" positive blood group.

Another striking abnormality he had was grossly low lipid values. He had very low cholesterol levels -Total cholesterol -20 mg/dl, HDL - 0 mg/dl, TGL - 115 mg/dl. His measured LDL was 21. Such low lipid levels occur with rare inherited conditions like Abetalipoproteinemia, familial hypobetalipoproteinemia and familial combined hypolipidemia⁵. Among these low lipid conditions, RBC membrane defect namely Acanthocytes are described, as in Abetalipoproteinemia and Familial Hypobetalipoproteinemia. But Stomatocytes have not been described in such conditions.

Stomatocytosis have been described with absent and low HDL conditions like Tangier's Disease and Lecithin Cholesterol Acyl Transferase (LCAT) deficiency^{6,7}. These low HDL conditions are associated with deposition of cholesterol in various tissues like liver, spleen, tonsils etc. But these conditions have normal VLDL and LDL levels.

Lipid electrophoresis of our patient showed absent chylomicron band, a faint VLDL band, absent HDL band, absent LDL band and absent Lipoprotein (a) band and his apo protein levels namely Apo A and Apo B levels were low.

Such a combination of absent HDL and low/ absent LDL occurs in a condition called Familial Combined Hypolipidemia. This disorder occurs due to mutation in Angiotensin like Protein 3 gene (ANGPTL3) causing deficiency of this protein. This leads to increased activation of lipoprotein lipase and endothelial lipase causing increased catabolism of VLDL and HDL respectively causing decreased levels of LDL and HDL⁵.

Lipid abnormalities in our patient suggest that he has Combined Hypolipidemia. But there is no literature stating an association between combined hypolipidemia and stomatocytosis. Probably the absent HDL in this condition can cause stomatocytosis. We could not screen his other family members.

Further studies are needed to find out the clear association between low serum lipids, LDL/HDL and RBC membrane defects.

Conclusion

Low lipid levels are associated with RBC membrane defects. Acanthocytes occur with Abetalipoproteinemia, a condition with low chylomicrons, low VLDL and low LDL. Stomatocytes occur with low HDL conditions. Lowering lipids to very low levels with statins or the newer PCSK 9 inhibitors might have effects on RBC membrane and also in other lipid structures. Further studies are needed to confirm the findings.

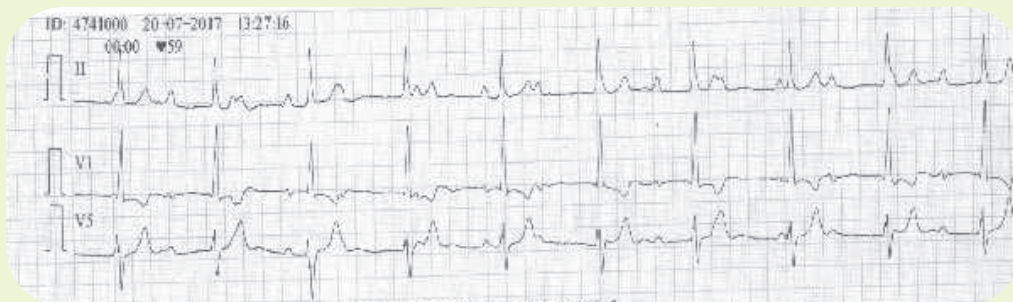
References

- 1) Gallagher PG. Disorders of the Red Blood Cell Membrane : Hereditary Spherocytosis, Elliptocytosis and related disorders. In: Beutler E, Kipps TJ, Seligsohn U, Kaushansky K, Prchal JT, editors. William's Hematology. 7th edition. McGraw Hill Medical; 2006 p. 580-7

- 2) Wolkoff A.W. The Hyperbilirubinemias. In: Kasper DL, Fauci AS, Hauser SL, Longo D.L, Jameson JL, Loscalzo J, editors. Harrison's Principles of Internal Medicine .19th ed. New York:Mc Graw Hill ; 2015. p. 2001
- 3) Murthy GD, Byron D, Shoemaker D, Visweswarai-ah H, Pasquale D. The utility of rifampin in diagnosing Gilbert's syndrome. Am J Gastroenterol. 2001;96(4):1150-4.
- 4) Qureshi A, Salman M, Moiz B. Rh null: a rare blood group phenotype. Journal of the Pakistan Medical Association, 60(11), 960-1.
- 5) Welty FK. Hypobetalipoproteinemia and abetalipoproteinemia. Curr Opin Lipidol. 2014;25(3):161-8.
- 6) Reinhart WH, Gössi U, Bütikofer P, Ott P, Sigrist H, Schatzmann HJ, Lutz HU SP. Haemolytic anaemia in an alpha-lipoproteinaemia (Tangier disease): morphological, biochemical, and biophysical properties of the red blood cell. Br J Haematol. 1989;72(2):272-7.
- 7) Miettinen H, Gylling H, Ulmanen I, Miettinen KK. Two Different Allelic Mutations in a Finnish Family With Lecithin:Cholesterol Acyltransferase Deficiency. Arterioscler Thromb Vasc Biol. 1995;15(4):460-7

INTERESTING ECG

15 year old asymptomatic boy with the following ECG



- Dr.G.Ashok, Consultant Cardiologist, CSSH.

Answer in page : 45