

Case Report

Papillary Cystadenoma of Minor Salivary Gland

*M. Devi, *D. Vijayalakshmi, *C. Sreeja, *K. Ramakrishnan, *S. Shabana, **I. Aesha

*Reader, Oral Pathology, Adhiparasakthi Dental College & Hospital, Melmaruvathur, Tamilnadu, India, **Lecturer, Oral & Maxillofacial Pathology, Chettinad Dental College & Research Institute, Kelambakkam, Chennai, India.



Dr. Devi M is a Reader in the Department of Oral Pathology, Adhiparasakthi Dental College and Hospital, Melmaruvathur, Tamilnadu, India.

Corresponding author - Dr. M. Devi (devident@rediffmail.com)

Abstract

Papillary Cystadenoma is a well-circumscribed, benign tumor that originates from the salivary glands, with the cystic cavities showing intraluminal papillary projections. Papillary tumors of the minor salivary glands are quite rare. Most of the lesions described in the literature under the heading 'papillary cystadenoma' histologically resemble an adenolymphoma without the lymphoid component.

Here we report a case of Papillary cystadenoma of minor salivary gland with special emphasis on the histomorphological features and differential diagnosis of this tumor.

Key Words: Papillary Cystadenoma, Palate, Benign Salivary Neoplasm.

Chettinad Health City Medical Journal 2014; 3(1): 18 - 21

Introduction

Papillary cystadenoma of salivary glands is a rare benign neoplasm. It constituted only 2% to 4.7%, respectively, of all minor salivary gland neoplasms, and 4% to 8.1% respectively, of all benign epithelial minor salivary gland neoplasms^{1,2}. This lesion has a tendency to recur if not appropriately excised¹. Papillary cystadenomas of the oral region are reported in literature^{1,2,3,4}, however, case reports of Papillary Cystadenoma arising from a minor salivary gland of palate are even rare^{5,6}. Characteristic histological features usually aid in diagnosis of salivary gland lesions. However, diagnosis of salivary gland pathology is not easy. Clinical and histological differential diagnoses have to take into account to support a diagnosis of Papillary cystadenoma.

Case Report

A 54-year-old man presented with an asymptomatic mass of the hard palate that was present for 3 years. Apart from being a known diabetic, his medical, family, dental history and review of systems were not significant. There was no history of nasal obstructive symptoms, discharge or pain in relation to the maxillary sinus areas.

Intraoral examination revealed a solitary, sessile, well-circumscribed, solid, round mass of about 4-cm in diameter (Fig 1) that was slow-growing. The mucosa overlying the mass showed no changes in colour. The surface of the swelling was smooth. There was no history of trauma, bleeding, discomfort from the swelling or pain during eating. The inspectatory

findings were confirmed on palpation and the swelling was firm in consistency, non-fluctuant, non-compressible and non-pulsative. Mobility of the adjacent teeth could not be demonstrated. No abnormalities were detected extraorally. No neck masses were palpated, and no synchronous pathology was observed in the oropharyngeal region. A provisional clinical diagnosis of Pleomorphic adenoma was made.

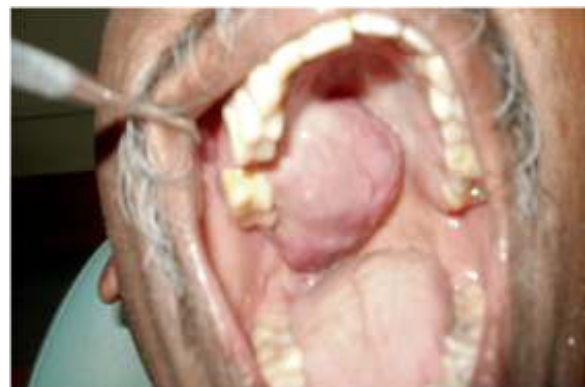

Fig. 1: 4-cm-diameter solitary, sessile, well-circumscribed, solid, round mass on the palate.

Investigations

Laboratory investigations, carried out as a routine preoperative procedure did not yield any remarkable findings. The swelling in the palate was close to the maxillary antrum. Hence a CT scan which is a superior imaging modality for delineating any bone involvement was chosen for radiological evaluation. CT scan revealed a well defined soft tissue swelling of the palate

with small extension into antrum but without erosion of antral floor or bony involvement (Fig. 2&3). Incisional biopsy was done under local anesthesia under the clinical suspicion of pleomorphic adenoma.

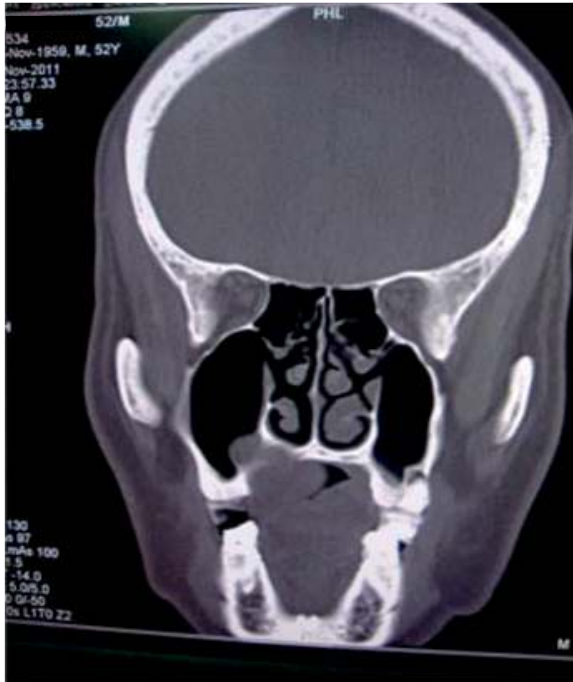

Fig. 2: A well defined soft tissue swelling of the palate with small extension into antrum but without erosion of antral floor or bony involvement

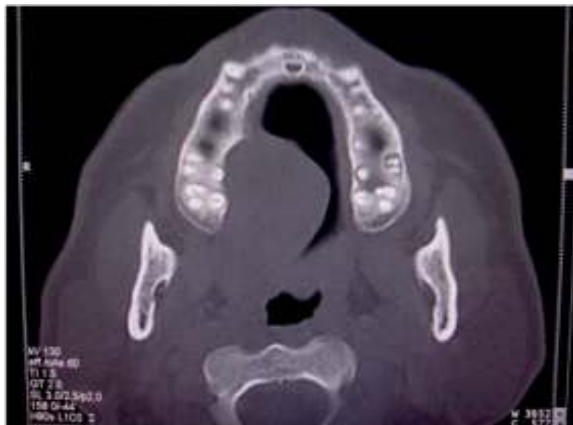

Fig. 3: A well defined soft tissue swelling of the palate with small extension into antrum but without erosion of antral floor or bony involvement

The histologic examination showed the tumor mass to be encapsulated by thick fibrous connective tissue and arranged in the form of lobules, sheets and ductal pattern. The mass was also composed of numerous cystic spaces lined by epithelium which are thrown into papillary projections and in few areas they were surrounded by thickened basement membrane. The lining epithelium comprised of cuboidal ductal cells with vesicular nuclei and showed no atypia. Thin fibrous connective tissue core admixed with few areas of haemorrhage and hyalinizations were seen. Final diagnosis was confirmative of Papillary cystadenoma of the minor salivary gland. (Fig 4, 5, 6).

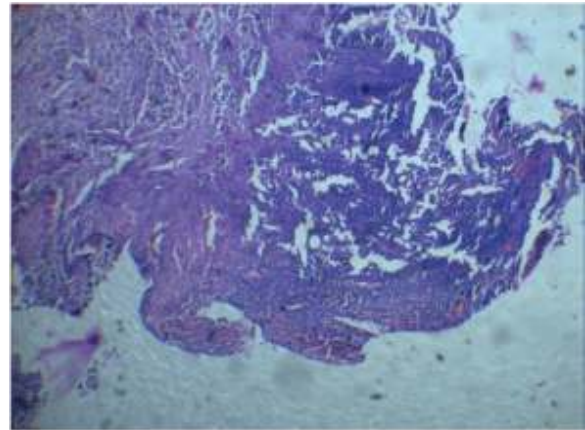


Fig. 4: The cystic space showing multiple papillary projections supported by fibrous connective tissue (H&E x4).

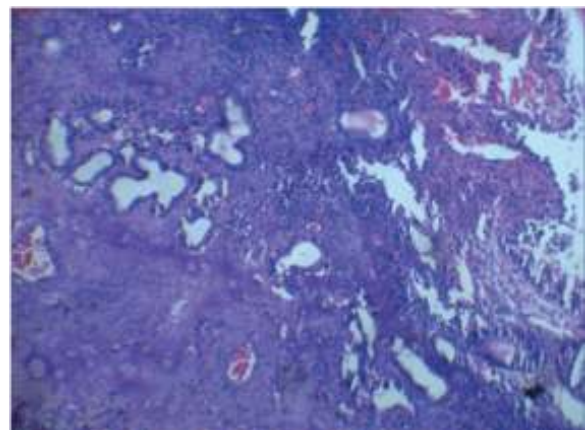


Fig. 5: The papillary projections are lined with cuboidal to columnar cells with ductal proliferation in the center of the lesion (H&E x4).

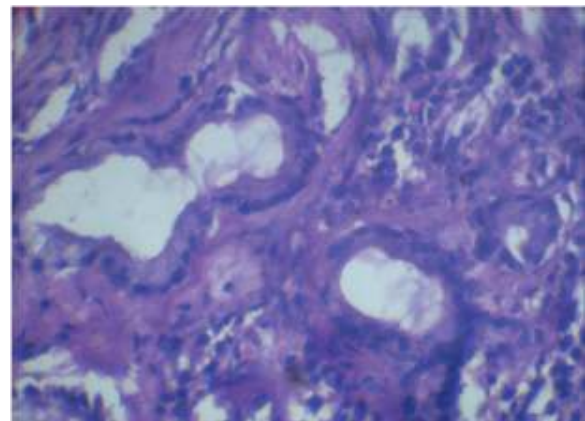


Fig. 6: The ducts comprised of cuboidal cells and partly by one to two layers of flattened cells with no cellular atypia. (H&E x40).

Differential diagnosis

Pleomorphic adenoma, Warthin's tumor, intraductal papilloma, canalicular adenoma, polymorphous low-grade adenocarcinoma, low-grade mucoepidermoid carcinoma, and the papillary cystic variant of acinic cell carcinoma were considered.

Treatment

A total excision of the tumour was planned. Under general anaesthesia with nasotracheal intubation the procedure was performed uneventfully. A clear acrylic surgical obturator, fabricated on a cast made prior to surgery, was given.

Outcome and follow-up

Postoperative period was uneventful. The patient was stable and afebrile. The patient was followed up for ten months and there was no evidence of recurrence.

Discussion

The Papillary cystadenoma (PC) is described as a cystic adenoma consisting of cystic spaces filled with papillary projections⁷, arising from undifferentiated epithelium of the intercalated duct of the glands¹ particularly the minor salivary glands. "A tumor contains multiple papillary projections and numerous types of epithelial lining cells with close resemblance to Warthin tumor and does not show any lymphoid elements" was the definition given by World Health Organization (WHO) for PC⁸. In this sense, we believe that salivary glands tumors are difficult to diagnose or interpret because there are many possible patterns of presentation. Tumors of minor salivary gland origin account for less than 25% of all salivary gland neoplasm⁹. In addition; Papillary cystadenoma of the minor salivary gland is rare⁵.

The Papillary cystadenoma appears to occur more frequently in women, older than 50 years of age, with several in their seventies¹⁰. The most common sites are the palate and buccal mucosa, however, tumors in the lip and tongue also have been reported¹¹. In our case, the tumor occurred in the palate of a 54-year-old man.

Lim et al¹² provided a cytological description of smears prepared from fine-needle aspiration of Papillary cystadenoma. The cytology could direct only to an interim diagnosis which is not definitive¹³. The ultimate histopathological diagnosis of this rare minor salivary gland neoplasm required the elimination of similar benign tumors such as Warthin's tumor, canalicular adenoma, intraductal papilloma, and malignant tumors such as low-grade mucoepidermoid carcinoma, cystadenocarcinoma, polymorphous low-grade adenocarcinoma, and papillary cystic variant of acinic cell carcinoma.

To rule out Warthin's tumor, we must check for presence of lymphoid aggregates containing germinal center, and a double-row epithelium with inner low cuboidal cell and outer tall columnar cells⁸. These histological features were not evident in our case. Canalicular adenomas also show large cystic spaces containing papillary proliferations. But the epithelium usually presents as a single-layered cord or columnar or cuboidal cells with deeply stained basophilic nuclei. The connective tissue stroma is loose in nature with prominent vascularity⁸. Intraductal papillomas are benign salivary gland tumors which are usually

unicystic containing intraluminal proliferations⁸. These incongruous features ruled out canalicular adenoma and intraductal papilloma. However in our case, solid areas (usually limited in extent) and cystic areas were evident. The papillae lined by cuboidal to columnar cells usually two layers thick were seen projecting into the cystic areas.

Low-grade mucoepidermoid carcinoma shows prominent cyst formation and relatively a high noncystic epithelial proliferations¹³. The cystic papillary projections are irregular and complex similar to that seen in intraductal papilloma. In addition to the above features low-grade mucoepidermoid carcinoma exhibits minimal cellular atypia with a mixture of epidermoid, mucous, and intermediate cells which were not apparent in the present case. Cystadenocarcinoma, polymorphous low-grade adenocarcinoma, and papillary cystic variant of acinic cell carcinoma were eliminated based on the solid growth pattern in certain areas, the invasive pattern, the degree of cytological atypia, destruction of the glandular architecture, as well as invasion into the adjacent tissues like adipose, muscle, or bone tissues¹⁴. None of these features was observed in the present case.

Oncocytic change in Papillary cystadenoma can be focal or marked. When histology showed a unilocular cystic lesion with multiple papillary fronds lined with oncocytic cells and focal metaplastic squamous cells Papillary oncocytic cystadenoma variant can be considered¹⁵. But our case did not show any oncocytic cell changes.

A final diagnosis of Papillary cystadenoma was arrived based on the insight of the pathologist. Most recent report of a case involving cytological analysis and review of the literature, reported that in the authors' best knowledge, theirs was only the 12th case of this tumor seen in the palate¹². Nevertheless, clinically and histologically, Papillary cystadenoma displays a benign behaviour with rare recurrence.

Conclusion

Papillary Cystadenoma is a benign tumor originating from the salivary glands, with the cystic cavities containing intraluminal papillary projections. Papillary Cystadenoma arising from a minor salivary gland is rare. Conservative surgical removal is the treatment of choice. This lesion has a tendency to recur if not appropriately excised. Based on both macroscopic and microscopic findings dentist must be familiar to diagnose the salivary gland neoplasm of accessory glands.

References

- 1) Alexis JB, Dembrow V. Papillary cystadenoma of a minor salivary gland. J Oral Maxillofac Surg 1995; 53: 70-2.
- 2) Waldron CA, El-Mofty SK, Gnepp DR. Tumors of the intraoral minor salivary glands: a demographic and histologic study of 426 cases. Oral Surg Oral Med Oral Pathol 1988; 66: 323-33.

- 3) Akin RK, Kreller AJ, Walters PJ. Papillary cystadenoma of the lower lip - report of a case. J Oral Surg 1973; 31: 858-60.
- 4) Cathoun NR, Cerine FC, Mathews MJ. Papillary cystadenoma of the upper lip. Oral Surg 1966; 21: 782-5.
- 5) Tsurumi K, Kamiya H, Yokoi M, Kameyama Y. Papillary oncocytic cystadenoma of palatal minor salivary gland: a case report. J Oral Maxillofac Surg 2003; 61: 631-3.
- 6) Mahler V, Schell H. Papillary cystadenoma- a rare tumor of the minor salivary glands. Eur J Dermatol. 1999; 5: 387-9.
- 7) Kameyama Y, Okada Y, Takehana S, Mizohata M, Nishio S, Enomoto M. Papillary cystadenoma. Int J Oral Surg 1985; 14:556-9.
- 8) Ellis GL, Auclair PL, Gnepp DR. Surgical Pathology of the Salivary Glands. Saunders WB; 1991.
- 9) Stathopoulos P, Gagari E. Papillary cystadenoma of the lower lip exhibiting ciliated pseudostratified columnar epithelium: report of a bizarre case and review of the literature. J Oral Maxillofac Surg 2012; 30:357.
- 10) Collins EM. Papillary cystadenoma of accessory salivary gland. Am J Surg 1958; 96:749-50.
- 11) Guccion J. G. Papillary cystadenoma of the palate: a case report and ultrastructural study. J Oral Maxillofac Surg 1997; 55: 759-64.
- 12) Lim CS, Ngu I, Collins AP, McKellar GM. Papillary cystadenoma of a minor salivary gland: report of a case involving cytological analysis and review of the literature. Oral Surg Oral Med Oral Pathol Oral Radiol Endod.2008; 105:28-33.
- 13) Sanjay Gupta, Pushpa Sodhani, Shyama Jain, Nita Khurana, Prem Narayan Agarwal. Oncocytic papillary cystadenoma of parotid gland: A diagnostic challenge on fine-needle aspiration cytology Diagnostic Cytopathology 2011; 39:627-630.
- 14) Ananthaneni A, Kashyap B, Prasad VR, Srinivas V. Cystadenoma: A perplexing entity with subtle literature. J Dr NTR Univ Health Sci 2012; 1:179-81.
- 15) Zhang S, Bao R, Abreo F. Papillary oncocytic cystadenoma of the parotid glands: a report of 2 cases with varied cytologic features. Acta Cytol. 2009; 53:445-8.

Not that sterile!

Until now, it was believed that placenta was a sterile organ supplying the much needed oxygen and nutrients to the foetus. That belief is no longer tenable if the results of a new study published in Science Translational Medicine (Aagaard, K. et al. Science Transl. Med. 6, 237ra65, 2014) are to be accepted. In that study, the investigators analysed 320 placentas for the presence of bacteria by shotgun metagenomic sequencing. The researchers found small number of diverse bacteria including *Escherichia coli*, *Prevotella tanneriae* and *Neisseria*. The latter two are normally found in mouth. The microbiome in placenta closely resembled the one found in normal oral cavity. This might explain the well-known link between the periodontal disease in mother and pre-term birth. This study establishes that even in normal pregnancy, there is a specific bacterial community within the placenta. Further study is required to understand the role of placental microbial community in pre-term birth.

- Dr. K. Ramesh Rao