

## Clinical Image

### Unusual cause of Brain Abscess in Paediatric Age Group

Karthikeyan K V

Senior Consultant and Associate Professor, Dept of Neurosurgery, Chettinad Hospital & Research Institute, Chennai, India.

Chettinad Health City Medical Journal 2019; 8(4):

DOI: [https://doi.org/10.36503/chcmj\\_8\(4\)-08](https://doi.org/10.36503/chcmj_8(4)-08)

A 2 yr old girl presenting with fever on and off for 7 days with sudden onset of seizure with unconsciousness. On admission baby is unconscious pupillary asymmetry with no response.

CT brain contrast showing contrast enhancing mixed dense lesion with thick capsule and surrounding edema.

Patient underwent emergency craniotomy and total removal of lesion done.

Histopathology showed thick walled abscess and Culture showed Pneumococci.

The common cause of brain abscess in paediatric age group is E.coli. But here the organism is Pneumococci which is very unusual. The reason may be due to the failure to give Pneumococcal vaccine for young children. This underlines the need for pneumococcal vaccine in young children.

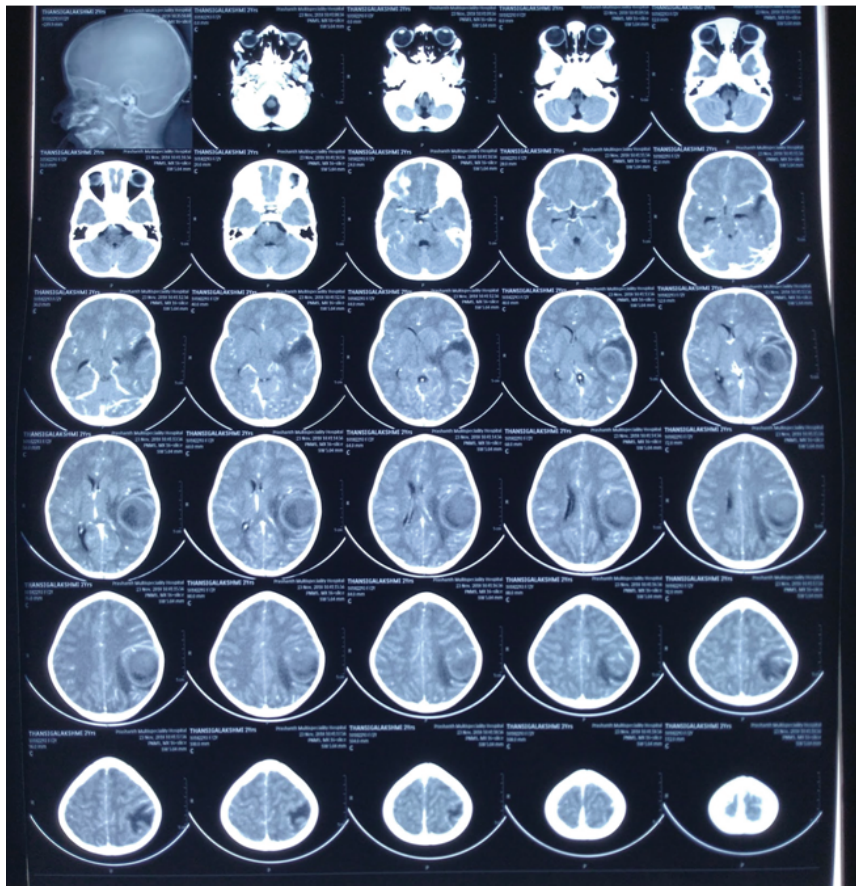


Figure 1: CT scan image showing brain abscess.