

Original Article

Non-Operative Management of Intussusception in Children: A Single Surgeon's Experience

Moorthy G

Associate Professor, Department of Pediatric Surgery, Chettinad Super Speciality Hospital, Chennai, India.



Dr. G. Moorthy graduated from IRT Perundurai Medical College and completed his MCh (Pediatric Surgery – 6 years) from All India Institute of Medical Sciences, New Delhi and DNB (Pediatric Surgery) from National board of Medical Sciences. He is a member of Royal college of Surgeons and National Academy of Medical Sciences. He is currently working as Senior Consultant at Chettinad Super Speciality Hospital and visiting consultant at major corporate hospitals in South Chennai. His areas of special interests are Pediatric Urology and Minimally Invasive Pediatric Surgery.

Corresponding author - [Moorthy G \(dr.moorthy@gmail.com\)](mailto:dr.moorthy@gmail.com)

Chettinad Health City Medical Journal 2016; 5(2): 60 - 63

Abstract

Background: Intussusception is one of the most common causes of acute abdomen in infants and preschool children. With the introduction of non-operative enema reduction into practice, the role of surgical management of intussusception in children is becoming narrower. Advantages of ultrasound guided saline enema reduction (USGSER) over fluoroscopic guided pneumatic reduction made it standard first line approach in majority of centers. Aim of this study is to analyze the results of intussusception cases managed by USGSER by a single surgeon. **Methods:** Retrospective review of all cases of intussusception from February 2010 to August 2016 was done. Demographics, clinical presentation, investigations, management and outcomes were reviewed. **Results:** Out of 59 intussusceptions managed during the study period, 5 cases taken for upfront surgery were excluded. All the remaining 54 cases have undergone USGSER and 51 (94%) were successfully reduced. **Conclusion:** In view of high success rate with very minimal complications, non-operative management should be the first line treatment for all uncomplicated cases of intussusception in children.

Key Words: Intussusception, ultrasound, saline enema.

Introduction

"Intussusception" is derived from the Latin words "intus" (within) and "suscipere" (to receive)¹ and it means invagination of proximal segment of bowel (intussusceptum) into the lumen of distal bowel (intussusciens)². It is one of the commonest causes of intestinal obstruction in infants and preschool children with a reported incidence of 1.5–4.3 per 1,000 live births³. Intussusception has been reported in prenatal period⁴ to very elderly age group⁵, but 3/4th of cases occur in less than 2 years of age with peak incidence between 4 and 10 months of life⁶. It has been classified into several types according to the area of involvement such as ileo-colic, ileo-ileo-colic, colo-colic, ileo-ileal and jejuno-jejunal with ileo-colic intussusception as the most common type (85%)⁷.

Even though Hirschsprung published his experience on hydrostatic reduction in 1876⁸, non-operative management of intussusception was not widely accepted till the later half of 20th century. In 1948, Ravitch reintroduced hydrostatic barium enema under radiologic guidance⁹, but pneumatic reduction under fluoroscopy became popular only from 1992¹⁰. Since fluoroscopic facilities are not widely available especially in developing countries, ultrasound guided saline enema reduction (USGSER) gained wide acceptance and became standard first line management for all uncomplicated cases of intussusception.

This study analyses the efficiency of USGSER done by a single surgeon for the management of intussusceptions in children.

Materials & Methods

With the objective to analyze the efficacy of USGSER as the primary management for intussusception in children, retrospective analysis of all cases of intussusception managed by a single surgeon from February 2010 to August 2016 was done. Inclusion criteria: All patients presenting with clinical diagnosis of intussusception and confirmed by ultrasound examination during the study were included.

Exclusion criteria: Patients taken for upfront surgical management for various indications were excluded. All patients were admitted once the diagnosis was confirmed by ultrasound. They were kept nil per mouth, adequately resuscitated with IV fluids and started on IV antibiotics. The parents were explained in detail about the etiopathogenesis, options of operative and non-operative management, advantages of non-operative treatment and the need for emergency surgery in cases of complications or failure and written informed consent was taken. Duty radiologist was informed and emergency operating room was kept ready as standby.

Injection midazolam (0.1 – 0.2 mg/kg) was given slowly through intravenous route at the start of the procedure; this makes the babies quiet and co-operative. A large Foley's catheter (22F or 24F) was inserted per rectally after adequate lubrication and balloon was inflated with 30 ml of normal saline. A saline bottle kept about 100 cm height was connected to the Foley's catheter through an IV drip set and free flow of saline into the rectum was monitored with

ultrasound. Saline gradually fills up the colon and pushes intussusceptum back towards cecum. Usually it takes some time for the proximal part of intussusceptum to get reduced through ileo-cecal valve and babies wake up and strain at that period. Due care to avoid excessive pressure while baby is straining and maintaining constant height of saline bottle on reduction are the keys to avoid perforation. Complete disappearance of mass and free flow of saline through ileo-cecal valve into the ileal loops were the markers of successful reduction which makes the babies become immediately comfortable. Filled saline was allowed to drain under gravity and Foley's catheter was removed. Cases that could not be reduced in the first attempt underwent the same procedure again at 5 minute interval. After successful reduction, babies were kept under monitoring and allowed orally once they passed greenish/yellowish stools. A check ultrasound after 24 hours of reduction to rule out any recurrence was done in all cases and they usually get discharged within 48 hours of procedure. Patients were taken up for emergency surgery if intussusception could not be reduced even after second attempt and in cases of complications.

Results

A total of 59 intussusceptions in 57 patients were managed during the study period. Of the 59, five cases taken up for upfront surgical management for various indications were excluded. Fifty four intussusceptions in 52 patients including one child with 2 episodes of recurrence were managed primarily by USGSR. There were 38 males and 14 females (Male: Female =2.7:1) and age ranged from 4 months to 5 years with 45 (86%) less than 2 years of age. Sudden onset of intermittent colicky abdominal pain was the commonest presenting symptom (96%) and abdominal mass on clinical examination was present only in 22 (40%) patients (Table 1). The diagnosis of intussusception was confirmed by ultrasound in all patients with classical "target sign" on axial view and "sandwich sign" on longitudinal view. The distal level of intussusception was at transverse colon in 18 (33%), at hepatic flexure in 8 (15%), at ascending colon in 26 (48%) and at cecum in 2 (4%) patients.

Clinical Feature	Number	Percentage
Pain abdomen	52	96%
Vomiting	37	68%
Bleeding per rectum	32	59%
Abdominal mass	22	40%

Table 1 - Clinical Features

Successful reduction of intussusception was achieved in 51 out of 54 cases (94%) and none of them had immediate recurrence within 24 hours of procedure. The amount of saline instilled for reduction varied from 300 to 800 ml and average duration of the procedure was about 15 minutes. One patient had perforation during the procedure, which was immediately noticed by ultrasound and underwent emergency laparotomy, manual reduction and resection of perforated bowel with end to end anastomosis. The perforation was at transverse colon and an enlarged edematous appendix and terminal ileum seems to be blocking the reduction. Patient had uneventful post-operative recovery and discharged. The other two patients who had failed reduction were also taken up for emergency manual reduction and no specific lead points were noted in both patients. Only one patient had 2 episodes of late

recurrence (6 months and 14 months after first procedure) and successfully reduced non-operatively on both episodes. None of the patients in this study had undergone delayed hydrostatic reduction.

Discussion

Intussusception is one of the most common surgical emergencies in children and has been described in detail by Hunter way back in 1793¹¹. Even though various treatment methods were reported in literature, surgical reduction was the mainstay of management till image guided hydrostatic or pneumatic reduction came into practice. In 1952, Ravitch and McCune used barium sulphate enema to diagnose as well as reduce intussusception, calling this "hydrostatic reduction" and reported 73.6 % success rate without mortality¹². But lack of fluoroscopic facilities made this technique almost unavailable in most of the developing countries. In the mean time, ultrasound became the investigation of choice to diagnose intussusception with 100% accuracy. In 1982, Kim et al¹³ reported the first successful ultrasound guided saline reduction of intussusception and it is followed by many articles confirming safety and high success rate of this technique^{14,15}.

Sudden onset of severe intermittent colicky abdominal pain which makes the babies cry with drawing up of their legs is the classical presentation of intussusception and it is usually associated with vomiting and blood and mucus (red currant jelly) stools (Fig 1). Clinical examination may reveal a sausage shaped mass with concavity towards umbilicus and blood stained fingers on per rectal exam will clinch the diagnosis. Confirmation of the diagnosis was done by picking up "target sign" (Fig 2) and "sandwich sign" (Fig 3) on high resolution (7.5 - 10 MHZ) ultrasound. Using color Doppler to check the blood flow of intussusceptum and identification of obvious lead points are the added advantages of ultrasound. None of our patients had compromised blood supply on Doppler and enlarged mesenteric nodes were present in most of the patients.

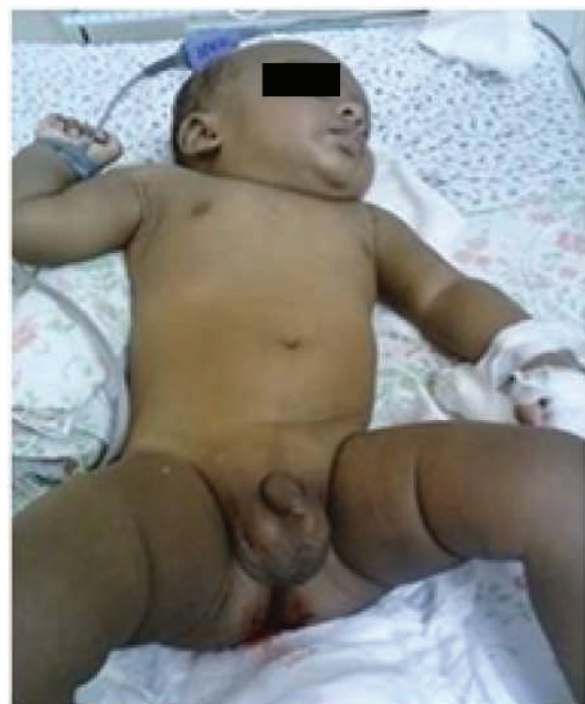

Fig 1 : Baby with Red currant jelly stools

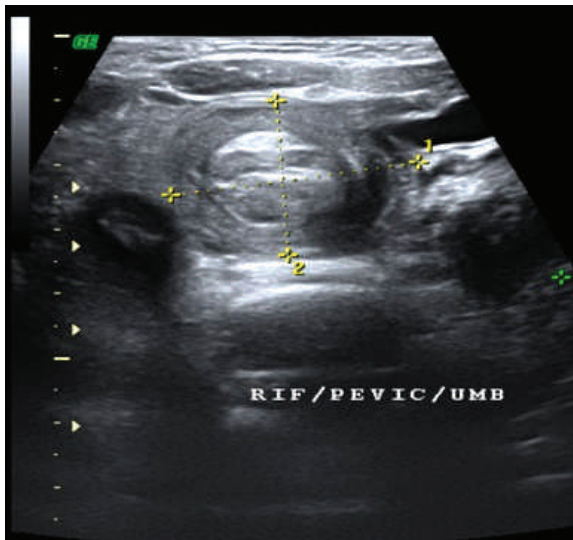


Fig 2 : Target Sign

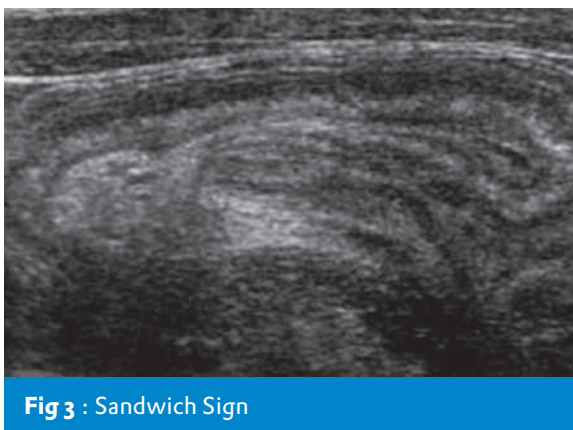


Fig 3 : Sandwich Sign

Once the diagnosis is made, patients should be adequately resuscitated and managed as early as possible as risk of bowel ischemia and perforation increases with time. In this study, we have corrected dehydration in all patients and one dose of IV antibiotics was given before the procedure to reduce the risk of sepsis. USGSER was used as the standard technique in all our patients and it has several advantages over fluoro-guided pneumatic reduction¹⁶ (Table 2).

Advantages of USGSER
<ul style="list-style-type: none"> • Readily available in most of the hospitals • No Radiation hazard • Simple, safe, effective, economical and less time consuming • Less morbidity and shorter hospital stay • Less complication and failure that can be diagnosed instantly • Recurrences can also be managed safely
Table 2 : Advantages of USGSER

Even though several advantages of USGSER were quoted in the literature, the author believes that the biggest advantage of this technique is its easy availability and it can be safely done even in small nursing homes with operation theater. Even in centers with facilities, pneumatic reduction under fluoro-guidance

disadvantage of exposing the patient and treating team to radiation. Daneman et al reviewed the hydrostatic reduction techniques of intussusception according to success rates, complication rates, advantages and disadvantages and concluded ultrasound guided techniques are superior¹⁷. High success rate of this technique has been verified by many authors and our study has also proved the same with 94% success rate.

Even though routine use of sedation was not mandatory for this procedure, many studies have used minimal sedation¹⁴. All our patients received a mild dose (0.1 – 0.2 mg/kg) of midazolam at the beginning of the procedure, which makes the children quiet and co-operative. None of the patients developed any complications related with sedation and we believe it is definitely beneficial for our increased success rate.

Intestinal perforation during USGSER reported in the literature is very low (0.26%)¹⁸ mainly because of uniform pressure delivered during saline flow (See Fig 4) unlike fluctuating pressures in pneumatic reduction. One our patient had perforation during USGSER, which could have been due to excessive pressures developing at the reduction of proximal most intussusceptum through ileo-cecal valve and patients invariably wakeup and strain during that part of procedure. Perforation was immediately recognized on ultrasound and the patient was immediately managed by surgical reduction. On surgery it was found that perforation was at transverse colon and an enlarged edematous appendix and terminal ileum seems to be blocking USGSER got easily reduced manually. Unlike chemical peritonitis during barium enema reduction or tension pneumoperitoneum during pneumatic reduction, peritoneal cavity was relatively clean and filled only with saline which is another advantage of USGSER. The only perforation in this study happened during the earlier part of the series and avoidance of excessive pressure while babies are straining is the key reason to stay away from this complication in rest of the patients. Even though this complication is exceedingly rare and instantly recognized, it should be managed immediately to avoid mortality. It stresses the importance of immediate availability of surgeon and operative room and the author strongly recommends that USGSER should be done preferably by Pediatric Surgeons.

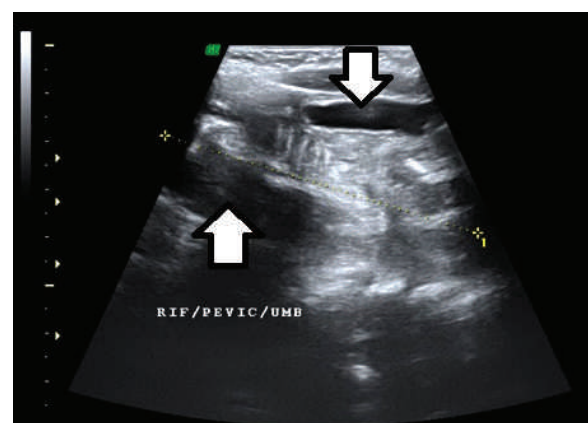


Fig 4 : Uniform flow of saline around intussusceptum

The remaining 2 failed patients were successfully managed surgically and no lead points were found to be the reason for failure (Fig 5). Only one patient in this study had 2 episodes of late recurrence (6 months and 14 months after first procedure) and successfully reduced by USGSER on both episodes. Even patients who have undergone previous surgical reduction were safely reduced by USGSER on recurrence⁹.

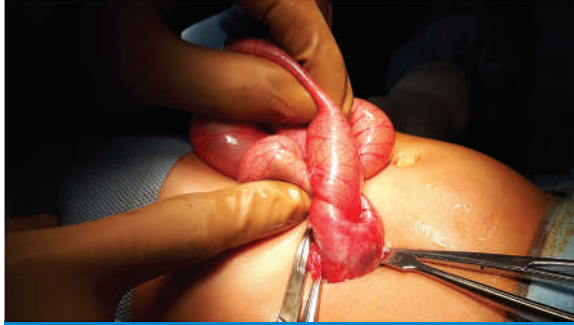

Fig 5 : Manual reduction

Conclusion

USGSER is simple, safe, effective, economical and quick with very few complications. It should be considered as the first line treatment for managing uncomplicated intussusceptions in children. This procedure should preferably be done by Pediatric Surgeons in view of serious risk of intestinal perforation.

References

- 1) Hamby LS, Fowler CL, Pokorny WJ: Intussusception. In Donnellan WL (ed): Abdominal surgery of infancy and childhood, 1996. Pg.no:1.
- 2) Vanessa MW, Intussusception. In Lewis S, Arnold GC, eds. *Rob & Smith's Operative Surgery, Pediatric Surgery*, 4th ed, London; Chapman & Hall Medical, 1994: 396-97.
- 3) Stringer MD, Pablot SM, Brereton RJ. Paediatric intussusception. *Br J Surg* 1992;79:867-76.
- 4) Mooney DP, Steinhorsson G, Shorter NA: Perinatal intussusception in premature infants. *J Pediatr Surg* 1996;31:695.
- 5) Israelit SH¹, Brook OR, Abbou B, Molner R, Duek SD, Krausz MM. Intestinal intussusception in elderly patients. *Maturitas*. 2009;62(2):124-26.
- 6) Young DG, Intussusception. In: Atwell JD, ed. *Paediatric Surgery*. Great Britain: Arnold, 1998:357-63
- 7) Sigmund H Ein, Alan Daneman: Intussusception. In Jay L Grosfeld, *Pediatric Surgery* 6th ed, Philadelphia, 2006: 1313-341.
- 8) Hirschsprung H: Tilfaelde af subakut tarminvagination. *Hospitals- Tilende* 1876;3: 321.
- 9) Ravitch MM, McCune RM Jr: Reduction of intussusception by hydrostatic pressure: An experimental study. *Bull John Hopkins Hosp* 1948;82(5):550-68.
- 10) Stein M, Alton DJ, Daneman A: Pneumatic reduction of intussusception: 5 year experience. *Radiology* 1992;183(3):681-4.
- 11) Hunter J: On intussusception. *Trans Soc Improv Med Surg Knowledge* 1793;1:103.
- 12) Ravitch, Mark M.; Morgan, Russell H: Reduction of Intussusception by Barium Enema. *Ann Surg*, 1952;135 (5): 596-604.
- 13) Kim YG, Choi BI, Yeon KM, Kim CW. Diagnosis and treatment of childhood intussusception using real-time ultrasonography and saline enema: Preliminary report. *JKorean Soc Med Ultrasound* 1982;1(1):66-70.
- 14) Wood SK, Kim JS, Suh SJ, Paik TW, Choi SO: Childhood intussusception: US-guided hydrostatic reduction. *Radiology*. 1992 Jan;182(1):77-80.
- 15) Riebel TW, Nasir R, Weber K. US-guided hydrostatic reduction of intussusception in children. *Radiology* 1993;188(2):513-6.
- 16) Krishnakumar, Shahul Hameed, Umamaheshwari. Ultrasound guided hydrostatic reduction in the management of intussusception. *Indian J Pediatr* 2006; 73(3):217-20.
- 17) Daneman A, Navarro O. Intussusception. Part 2: An update on the evolution of management. *Pediatr Radiol* 2004;34(2):97-108.
- 18) del-Pozo G, Albillos JC, Tejedor D, Calero R, Rasero M, de-la-Calle U, et al. Intussusception in children: current concepts in diagnosis and enema reduction. *Radiographics* 1999;19:299-319.
- 19) Tander B, Baskin D, Candan M, Başak M, Bankoğlu M. Ultrasound guided reduction of intussusception with saline and comparison with operative treatment. *Ulus Travma Acil Cerrahi Derg*. 2007 Oct;13(4):288-93.