

# Review Article

## Eye Manifestations of Diabetes Mellitus

Dr. Manoj Vasudevan

Assistant Professor of Ophthalmology, Department of Ophthalmology, Chettinad Hospital and Research Institute, Chennai, India



Dr. Manoj Vasudevan graduated from Stanley Medical College. He did his Postgraduation in Ophthalmology from Aravind Eye Hospital, Madurai, Corneal & Refractive Surgery Fellowship from John A. Moran Eye Center, University of Utah (USA). He is also an FICO (Fellow International Council of Ophthalmology) UK. Currently he is working as Assistant Professor Ophthalmology in Chettinad Hospital and Research Institute.

Corresponding author - Dr. Manoj Vasudevan (manojvasudevanms@gmail.com)

Chettinad Health City Medical Journal 2012; 1(4): 163 - 168

### Introduction

Diabetes Mellitus (DM) was first described about 3500 years ago and given its name about 2200 years ago by Demetrios of Apamaia. The word "Diabetes" derives from the Greek "Diabeinein" or "siphon", a word that captures its association with excess urination. Although DM has been primarily regarded as a disorder of glucose metabolism and homeostasis, it has more recently been viewed as a constellation of metabolic disturbances, including abnormalities of carbohydrate metabolism, adipose storage, lipid metabolism, and protein biochemistry. Commonly characterized as a disease of impaired skeletal muscle glucose uptake, DM adversely affects hepatic, muscle, adipose and vascular function. It is this last effect that represents the greatest mortality and morbidity hazard to this subset of population.

### Ocular Manifestations

DM affects all the parts of the eye from the lids to the retina and the cranial nerves. The part of the eye from the cornea to the posterior capsule of the lens forms the anterior segment of the eye and the structures behind the posterior capsule of the lens to the Optic nerve head and the retina forms the posterior segment of the eye.

#### Anterior segment manifestations

##### Lids and the adnexa

Hordeolum externum commonly called the styne is an acute suppurative inflammation of the eye lash follicle and its associated zeis glands. (Fig.1)

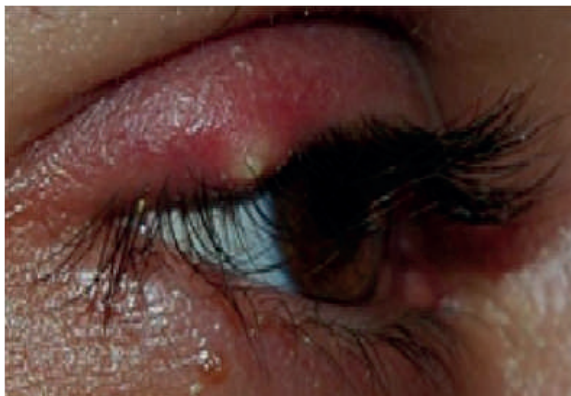

Fig 1. Hordeolum Externum

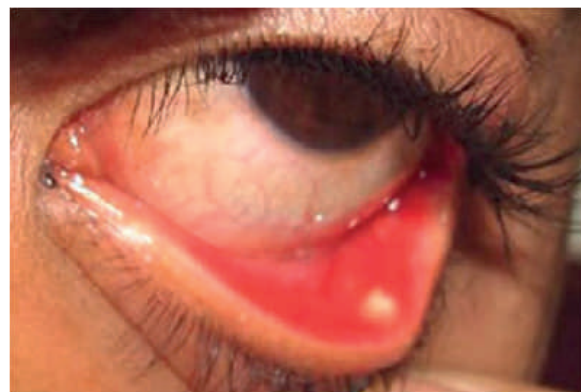

Fig 2. Hordeolum Internum

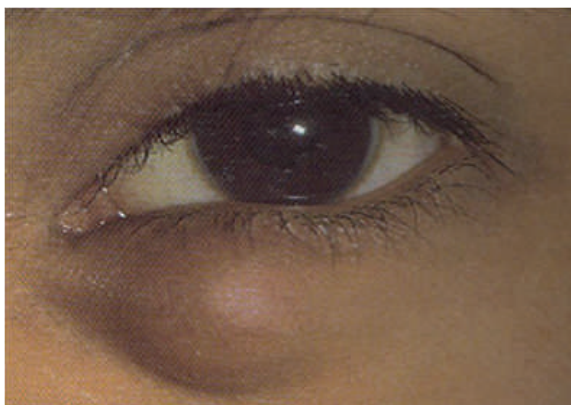


Fig 3. Chalazion

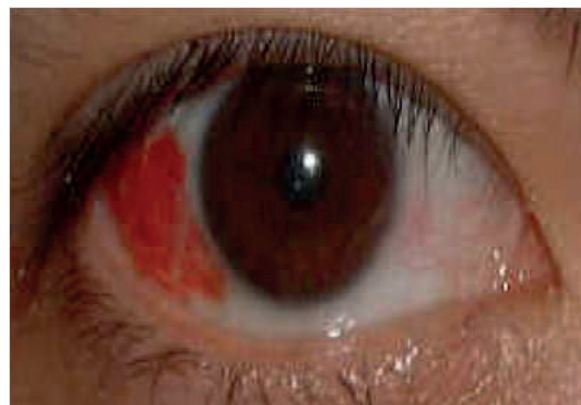

Fig 4. Sub conjunctival haemorrhage

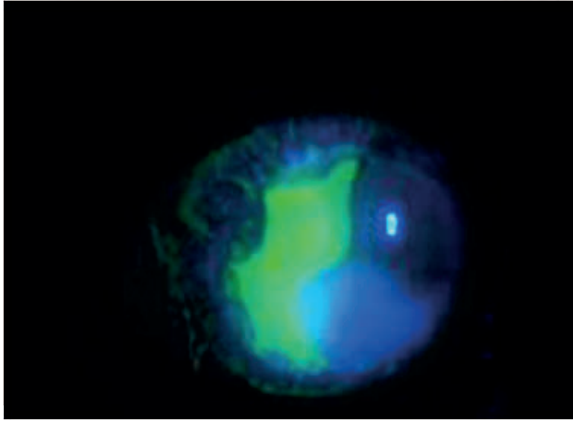


Fig 5. Fluorescein staining of the corneal epithelial defect

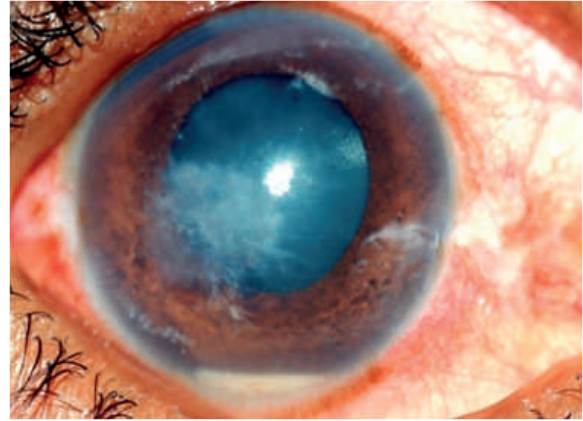


Fig 6. Fungal keratitis with hypopyon

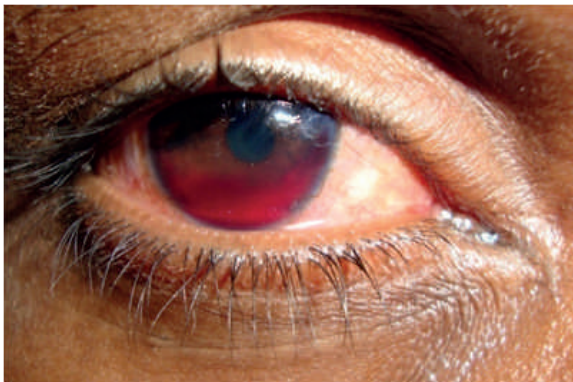


Fig 7. Hyphaema (Blood in the anterior chamber)

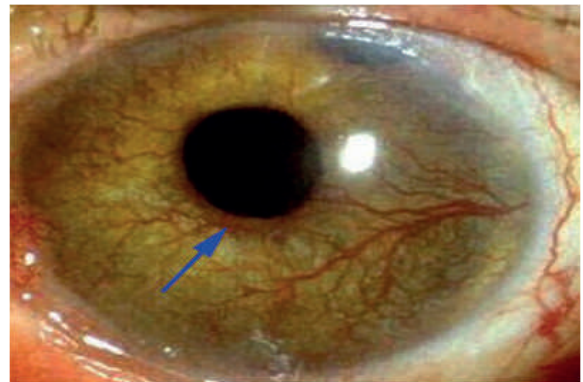


Fig 8. Ectropion uveae and rubeosis iridis

Hordeolum internum is an acute suppurative inflammation of the meibomian glands. (Fig.2)

Treatment of hordeolum externum and internum: Topical antibiotics, hot compresses, analgesics and if needed systemic antibiotics.

Chalazion is a chronic granulomatous inflammation of the meibomian glands. (Fig.3)

**Treatment:** Incision and curettage.

### Conjunctiva

Recurrent sub conjunctival haemorrhages (SCH) and dry eye or xerosis of the conjunctiva. (Fig.4)

**Treatment:** Control of DM, vitamin-c supplements and reassurance.

### Cornea

The cornea shows a decreased nerve fiber density and nerve conductivity causing decreased corneal sensation. Poor adherence of the epithelial basement membrane to the underlying stroma due to decreased number of hemidesmosomes leads the diabetics to develop recurrent corneal erosions even to trivial trauma and predispose them to bacterial and fungal keratitis and neurotrophic non healing corneal ulcers (Fig 5,6). In the early stages of uncontrolled or fluctuating levels of blood glucose in diabetics, cornea can become thick due to corneal edema causing blurred

vision and later due to recurrent erosions they might become thin with persistent epithelial defects. So in young diabetics the role of refractive surgeries like LASIK (Laser Assisted In-Situ Keratomileusis) or PRK (Photorefractive Keratectomy) to correct refractive error becomes difficult and is associated with higher rates of complications. Same holds good for the use of contact lens in these individuals. They also have altered endothelial cell morphology so any intra ocular surgery like cataract surgery can cause corneal edema which might take days to resolve.

**Treatment:** Infective keratitis is appropriately treated with anti microbials and cycloplegics. Lubricant eye drops for dry eyes, corneal epithelial defects and recurrent erosions.

### Anterior Chamber And The Angle

Many studies suggest a direct correlation between diabetes and Primary open angle glaucoma (POAG). Neovascular glaucoma (NVG) develops in patients having proliferative diabetic retinopathy (PDR) and advanced diabetic eye disease due to the development of neovascular membrane at the angle of the anterior chamber. These patients might sometime present with hyphaema. (Fig.7)

**Treatment:** Control of intra ocular pressure (IOP) with anti glaucoma medications. If not controlled filtering surgery with or without shunt and Mitomycin-C. If the eye is already blind diode cyclo-photocoagulation can be helpful to control the IOP.

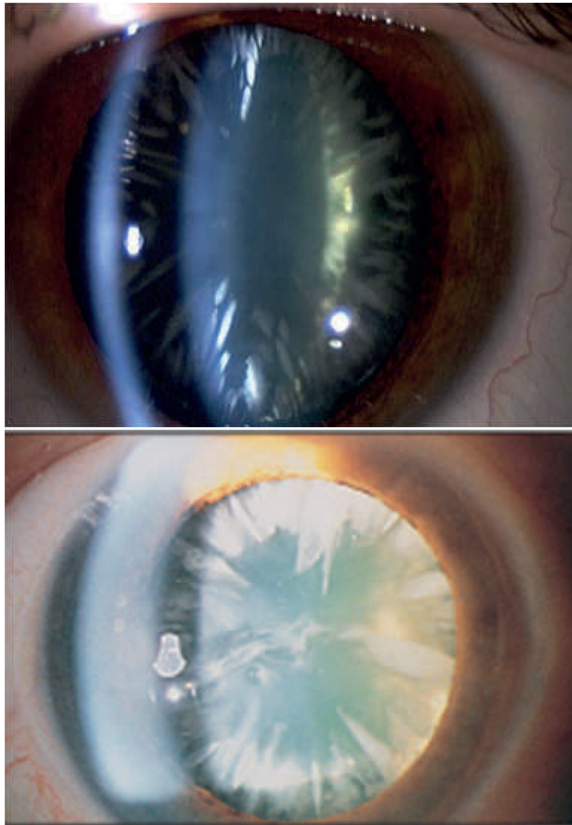


Fig 9. True diabetic cataract also called as snow flake cortical cataract.

## Iris

The development of new vessels at the iris can be seen in patients with PDR. These are called as rubeosis iridis. (Fig.8) These patients also have a typical appearance of the iris at the papillary margin called as ectropion uveae.

Treatment: Treat the underlying PDR with Laser pan retinal photocoagulation if the media is clear or retinal cryopexy if the media is hazy to reduce the release of vascular endothelial growth factors (VEGF) which causes rubeosis and NVG

## Pupil

Diabetics generally have a smaller pupil and show latency to dilatation with instillation of mydriatics during examination.

## Lens

Transient fluctuating myopia occurs due to hyperglycemia induced change in the refractive index of the lens due to osmosis. Diabetics are at risk of developing cataract earlier compared to non diabetics and it depends on the glycemic control and the duration of the DM. The most common type is the cortical cataract and the posterior sub capsular cataract. (Fig.9)

Treatment: If visually significant, cataract surgery with intra ocular lens implantation is recommended.

## Posterior Segment Manifestations

### Vitreous

Asteroid hyalosis (Benson disease) is commonly seen in DM patients but not proven. These are calcium pyrophosphate globules collected within the vitreous gel.

Treatment: Generally visually insignificant. If it affects vision a optical vitrectomy is done.

Vitreous haemorrhage is commonly associated with proliferative diabetic retinopathy.

### Retina

The prevalence of Diabetic retinopathy (DR) is probably up to 40%. It is more common in type 1 DM than in type 2 DM and sight threatening disease is seen in up to 10%

### Risk Factors

1. Duration of DM is the most important risk factor.
2. Poor control of DM.
3. Pregnancy is associated with rapid progression of DR.
4. Hypertension.
5. Nephropathy.
6. Hyperlipidemia.
7. Other risk factors are obesity, smoking, complicated cataract surgery and anaemia.

## Pathogenesis Of Diabetic Retinopathy<sup>1</sup>

DR is predominantly a microangiopathy in which small blood vessels are vulnerable to damage from hyperglycemia. The general pathophysiology described earlier is applicable to retina and retinal vasculature damage as well. Along with this there is capillaropathy and neovascularization. Capillaropathy is characterized by death of pericytes, thickening of capillary basement membrane, loss of vascular smooth muscle cells, and proliferation of endothelial cells. Neovascularization is caused by capillary non perfusion which leads to retinal hypoxia and stimulation of angiogenic factors like VEGF.

## Classification of DR

Early treatment diabetic retinopathy study (ETDRS)/ the Modified Airlie House classification<sup>10</sup>

1. Non proliferative diabetic retinopathy (NPDR)
  - I. No DR
  - II. Mild NPDR

Retinal microaneurysm/retinal haemorrhage with hard or soft exudates in one quadrant of retina.



### III. Moderate NPDR

Retinal haemorrhage/microaneurysm with hard or soft exudates in 1-3 quadrants of retina.

### IV. Severe NPDR (Fig. 10,11)

The 4-2-1 rule; one or more of :

- a. Severe haemorrhages in all 4 quadrants of retina
  - b. Venous beading in 2 or more quadrants
  - c. Moderate Intraretinal microvascular abnormalities (IRMA) in 1 or more quadrant
- V. Very Severe NPDR  
2 or more of the criteria for severe NPDR

## 2. Proliferative diabetic retinopathy

### I. Early PDR

New vessel on the disc (NVD) or new vessel elsewhere (NVE) but insufficient to meet the high risk criteria

### II. High Risk PDR

- a. NVD about 1/3 of the disc area
- b. Any NVD with vitreous or pre retinal haemorrhage
- c. NVE greater than 1/2 disc area with vitreous or pre retinal haemorrhage

### III. Advanced Diabetic Eye Disease

- a. Pre retinal or vitreous haemorrhage
- b. Tractional retinal detachment (TRD) (Fig.12)
- c. Rubeosis iridis

## 3. Diabetic maculopathy

### I. Focal maculopathy

Well circumscribed retinal thickening associated with complete or incomplete rings of exudates

### II. Diffuse Maculopathy

Diffuse retinal thickening with exudates

### III. Ischemic Maculopathy

Macula may look normal with variable signs with decreased vision, confirmed with fundus fluorescein angiography

### IV. Clinically Significant Macular Oedema (CSME/CSMO)

- a. Retinal thickening within 500 microns of the center of the macula.
- b. Exudates within 500 microns of the center of the macula, if associated with retinal thickening which may be outside the 500 microns
- c. Retinal thickening one disc area (1500 microns) or

larger, any part of which is within one disc diameter of the center of the macula.

## Management of DR

### Investigations

Regular follow up a DM patient with fasting and post prandial blood glucose levels and others like HbA<sub>1c</sub>, Hb, serum electrolytes and calcium, fasting lipid profile, serum blood urea nitrogen and creatinine on a periodical basis.

FFA is indicated to rule out PDR and for follow up after treatment for both PDR and maculopathy. Optical Coherence Tomography (OCT) helps in the follow up of patients with maculopathy before and after treatment as it is non invasive.

## Treatment

### Medical treatment<sup>8</sup>

NPDR just needs adequate glycemic control with control of other co morbid conditions like hypertension and dyslipidemia.

PDR needs pan retinal laser photocoagulation<sup>7</sup> (PRP) so as to convert a hypoxic retina into an anoxic retina in order to reduce the stimulus for the production of the angiogenic growth factors.

It can also be combined with intra vitreal injection of Bevacizumab<sup>5,6</sup> (Avastin), Ranibizumab (Lucentis) or Pegaptanib sodium (Macugen) which are the available anti-VEGF at present.

Maculopathy is treated with Focal or Grid Laser photocoagulation with or without additional use of intra vitreal steroids like Dexamethasone (Posurdex), Triamcinolone<sup>4</sup> (Tricort) or anti- VEGF injections.

### Surgical Treatment

Advanced diabetic eye diseases and patients with PDR/Maculopathy following ineffective medical management needs Pars plana vitrectomy<sup>9</sup>, endo laser photocoagulation and retinal re-attachment surgeries. (Fig. 14,15)

### Follow Up

The most important part of treatment in DR is the follow up which is very crucial for the preservation of useful visual acuity in these patients.

Mild NPDR	Every year
Moderate NPDR	Every year
Severe NPDR	Every 6 months
Very severe NPDR	Every 4 months
PDR & advanced eye diseases	Every 2 months

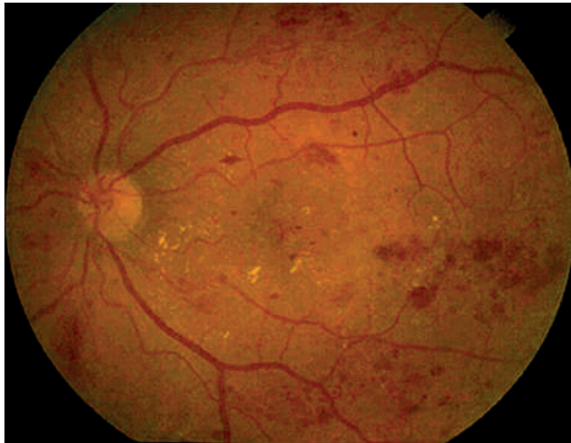


Fig 10. Severe NPDR

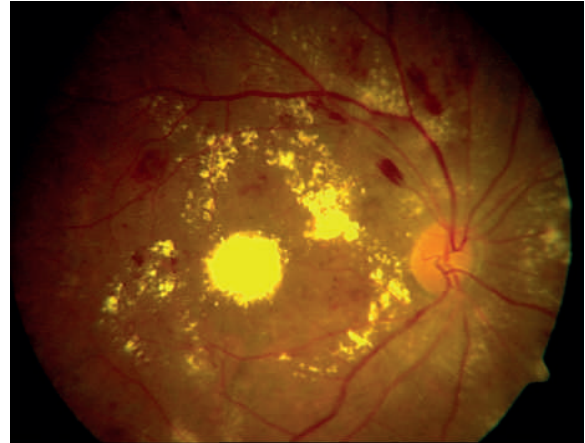

Fig 11. Severe NPDR with CSME

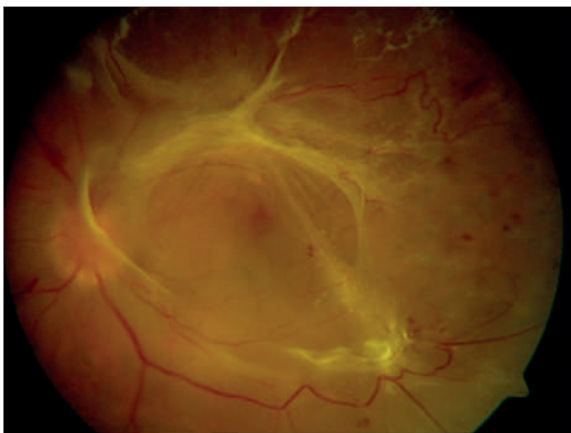


Fig 12. Advanced diabetic eye disease with TRD

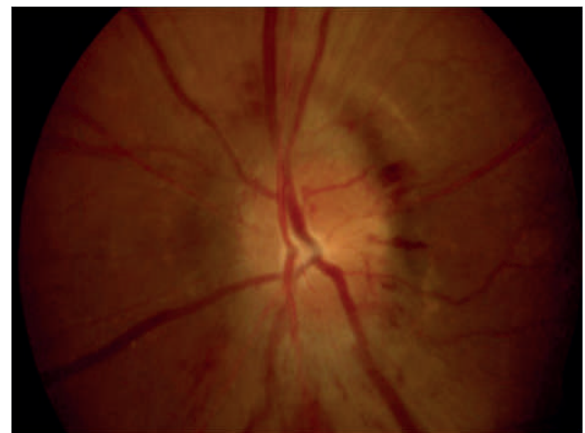


Fig 13. Diabetic papillopathy

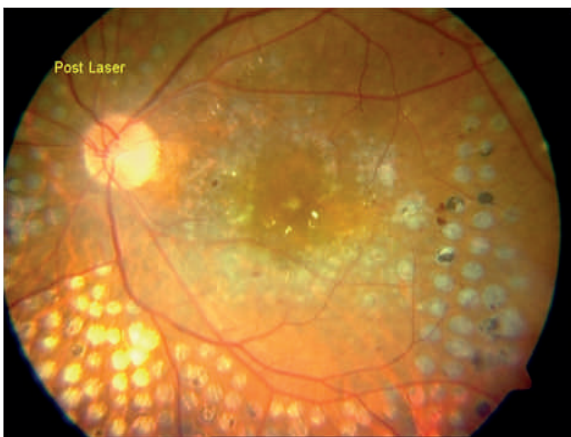


Fig 14. Post PRP Laser PHC

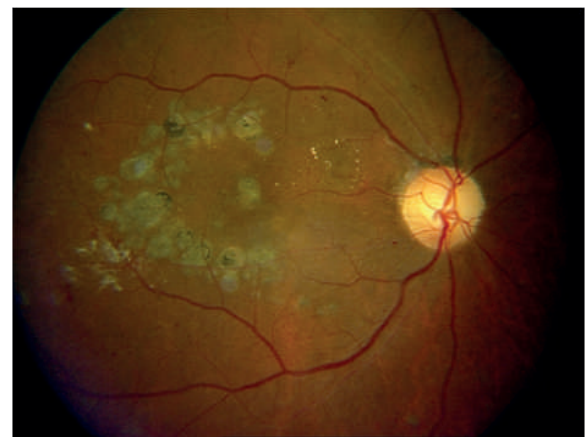

Fig 15. Post Focal Laser PHC for maculopathy

### Neuro-Ophthalmic Manifestations Of DM

Some of the common neuro ophthalmological conditions seen associated with uncontrolled DM are

1. Non arteritic type of anterior ischemic optic neuropathy (NAION).
2. Diabetic papillopathy.
3. Cranial nerve palsies (Oculomotor and Abducens) and ophthalmoplegia.
4. Bilateral light near dissociation.

5. Orbital apex and superior orbital syndromes.

### Conclusion

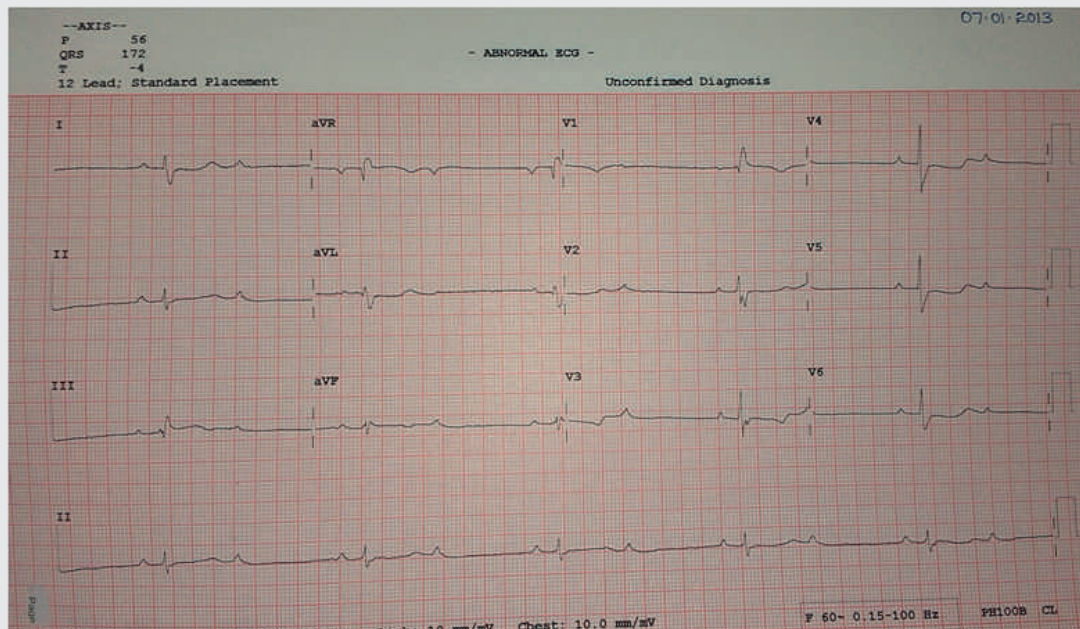
Creation of awareness for a prompt follow up of all patients with DM and other systemic diseases which affects the eyes and the vision is absolutely essential to prevent these patients ending up with PDR from the time a diagnosis of DM is made by the physician to avoid blindness and other ocular morbidities.

## References

- 1) Jack J Kanski & Brad Bowling, Clinical ophthalmology; 7th edition.
- 2) Joshua A Beckman, Cardiology; December 2004, Volume 8, Issue 10.
- 3) Capellini VK et al, Current Vascular Pharmacology, 2010 July, 8(4); 526-44.
- 4) Jonas JB, Dev Ophthalmol, 2007, 39; 96-110.
- 5) Ushida H et al, Ophthalmic research, 2012 September, 49(1); 30-36.
- 6) Ushida H et al, Ophthalmic research, 2012 September, 49(1); 30-36.
- 7) Zhao LQ, British Journal of Ophthalmology, 2011 September, 95(9); 1216-22.
- 8) Zein WM, Retina, 2006 Feb, 26(2); 137-42.
- 9) Chistiakov DA, Diabetes Metab Syndr Diabetes, 2011 Jul-Sep, 5(3); 165-72.
- 10) Flynn HW Jr et al, Ophthalmology, 1992 Sep, 99(9); 1351-7.

## Diagnose the Condition

80 year old male, known case of type 2 diabetes mellitus with chronic renal failure admitted with history of occasional giddiness. ECG taken in the ICU.



Answer in page no: 176

- Dr. M.Chokkalingam, Consultant Cardiologist, CSSH.