

# Case Report

## An Innovative Combined Three Dimensional Augmentation of Alveolar Ridge using Titanium Mesh, PRF and Autogenous Bone Graft with Implant Placement

Dr.Vinayak S Gowda\*, Dr.B.Meena Priya\*\*

\*Professor, Department of Periodontics, VS Dental College and Hospital, Bangalore, \*\*Senior Lecturer, Department of Periodontics, Chettinad Dental College and Research Institute, Chennai.



Dr.Vinayak S Gowda completed his under graduation from VS Dental College and Hospital, Bangalore in 1997 and post graduation from SDM Dental College and Hospital, Dharwad in 2002. He completed his Diplomate in Implantology from ICOI. He did his Fellowship in implants from International Institute of Implantology, Nuremberg under Professor Dr.Manfred Lang in 2006. He has many publications in national and international journals to his credit. He has given guest lectures in many implantology conferences and conducted preconference programmes. His area of interest is periodontal regeneration, implantology and peri implantitis.

Corresponding author - Meena Priya. B (drmeenapriya@yahoo.com)

### Abstract

Alveolar bone augmentation is mandatory in deficient ridges prior to implant placement but ridge defects require regenerative membranes and bone grafts to achieve and particularly vertical bone augmentation which still remains a challenge to be proven. The aim of this case report is to propose a treatment modality for three dimensional augmentation of alveolar ridge using autogenous symphseal graft, PRF membrane, Titanium mesh and bone morselizer.

**Key words :** Ridge augmentation, PRF, Titanium mesh, autogenous graft.

Chettinad Health City Medical Journal 2013; 2(4): 137 - 141

### Introduction

Alveolar bone augmentation for dental implant rehabilitation is one of the greatest challenges. In order to place the implant in ideal anatomic position, adequate alveolar ridge dimensions should be present. Alveolar ridge defects are most commonly seen after periodontal infection and tooth extraction. Placement of implants in such defective sites could compromise the functional and aesthetic results. However adequate bone quality and quantity is mandatory prior to implant placement<sup>1</sup> because patients with loss of alveolar bone height or width may require reconstructive procedures including vertical ridge augmentation which remains a challenge in the reconstruction of the atrophic maxilla and mandible<sup>2</sup>.

The use of barrier membranes along with bone grafts and bone substitutes has been proposed and tested for the partial and full augmentation of the alveolar process prior to implant surgery<sup>3</sup>. The use of titanium mesh for reconstruction of the atrophic alveolus was first introduced by Dr. Philip Boyne et al. in 1985<sup>4,5</sup>. The use of titanium mesh along with bone grafts has been shown to be successful in both vertical and horizontal bone defects. The combination of rigid osteoconductive scaffold(titanium mesh) along with autogenous bone grafts would increase the possibility of vertical augmentation and esthetic results and decrease the post operative morbidity.

Platelet Rich Fibrin contains high concentration of platelets and growth factors which is found to stimulate the osteoblasts and periodontal ligament cells which fastens the wound healing and repair of the ridge defects<sup>6</sup>. The aim of this case report is to present a

combined surgical approach for a three dimensional augmentation of alveolar ridge using titanium mesh, Platelet rich fibrin and autogenous graft prior to implant placement.

### Case Report

A 23 year old female patient reported to the Department of Periodontics with the chief complaint of loose upper front tooth for the past 3 months. Patient also had a complaint of sensitivity in upper front & lower back teeth for 2 days. Patient underwent scaling 2 years before she reported as she had severe bleeding from gums.

**Clinical examination :** Extraorally no abnormality was detected .The gingiva was erythematous, soft and edematous in consistency which was generalized and diffuse, with loss of stippling in attached gingiva (Fig 1). Generalised enlargement of marginal gingiva and interdental papilla and bleeding on probing was present. Periodontal examination revealed the presence of generalized periodontal pocket. Grade II mobility was seen in 21 and 11 with pathologic migration and exudation in relation to 21. There was no discoloration of the involved teeth. Bimaxillary protrusion of teeth was present. Blood investigations were normal.

**Radiographic Interpretation:** Generalised horizontal bone loss extending till the junction of middle third and apical third and vertical bone loss extending till the apical third was observed in 21 and 11(Fig 2 & 3).

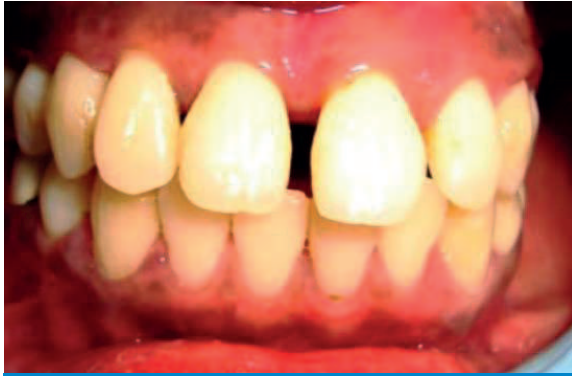

Figure - 1

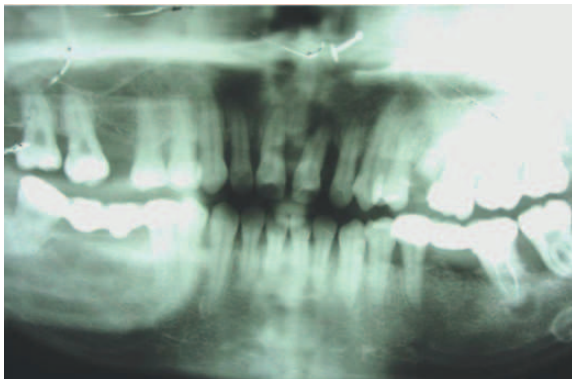


Figure - 2

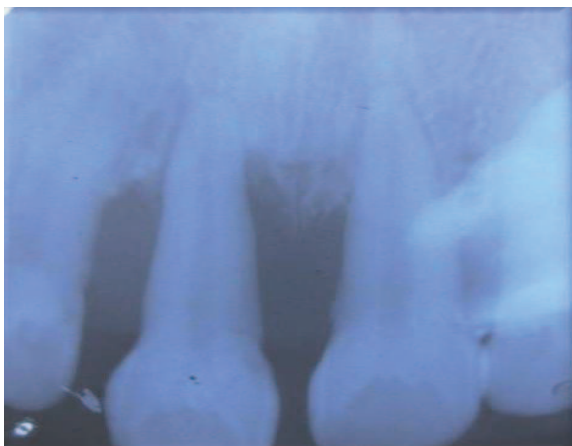


Figure - 3

**Management:** Scaling, root planing and curettage was carried out initially to reduce the inflammation. The patient was recalled after a month and periodontal flap surgery was carried out to control the inflammation and to prevent bacterial translocation in the defect area where the ridge augmentation was planned. In the maxillary anterior teeth, sulcular incisions followed by vertical incisions were placed distal to the line angles of 11 and 21. The flap was elevated and extraction of 21 was carried out as there was increase in the grade of mobility and pathologic migration of the teeth. The area was thoroughly debrided. Ridge mapping was at 3mm and 6mm away from the crest of the ridge which revealed a ridge width of 4 mm approximately<sup>7</sup>. The vertical defect area was measured corresponding to the CEJ of the adjacent tooth using UNC 15 probe (Fig 4).

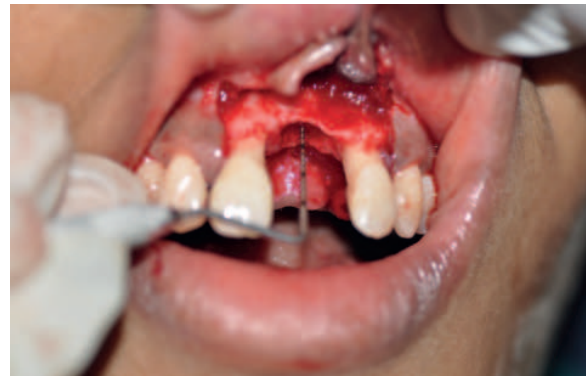

Figure - 4

Autogenous bone graft was harvested from mandibular symphysis using trephines (Fig 5) and the harvested bone was triturated using bone morselizer (Fig 6). The triturated bone was mixed with blood. The donor site was decorticated using round bur to induce bleeding. The titanium mesh of thickness 0.5 mm was contoured around the alveolar ridge so that there was a gap of 2mm above the crest of the alveolar ridge and sharp edges were removed. The mesh was adapted on both the buccal and lingual aspects of the ridge. The titanium mesh was stabilized using titanium screws (Fig 7). The morselized bone blend was placed under the mesh (Fig8).

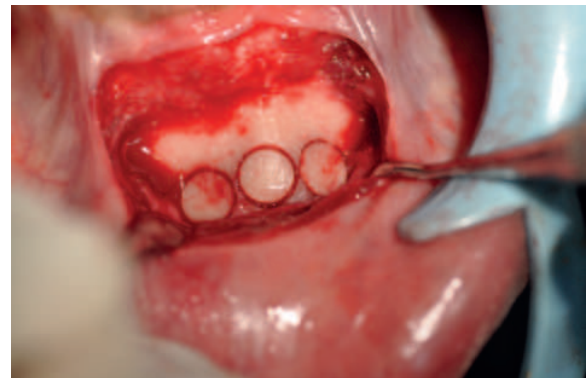


Figure - 5



Figure - 6

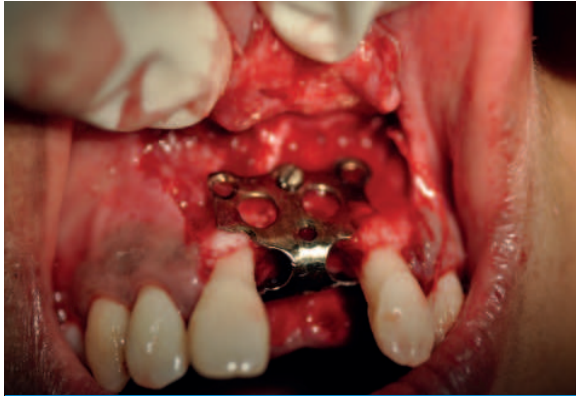

Figure - 7

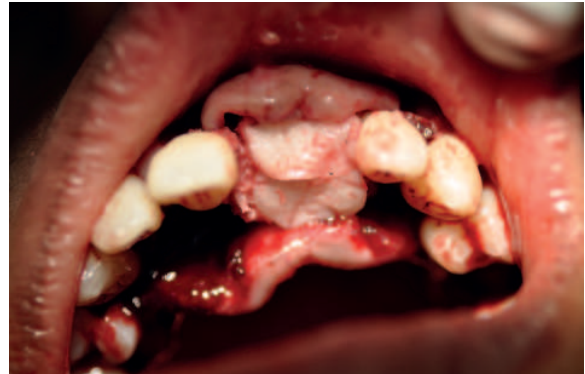

Figure - 9

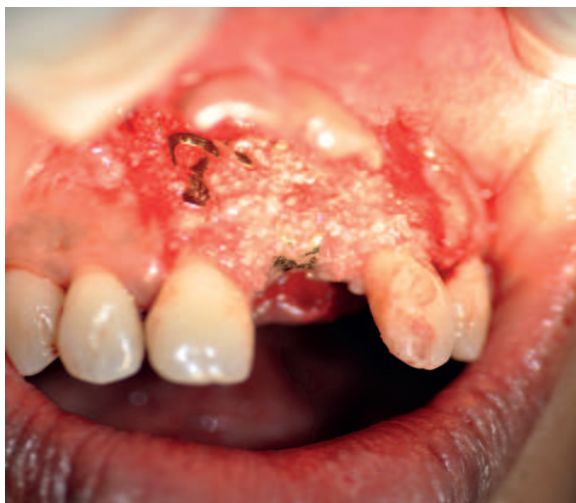

Figure - 8

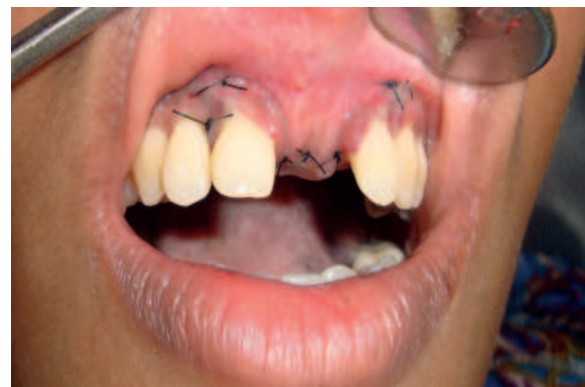

Figure - 10

PRF was prepared following the protocol developed by Choukroun et al<sup>8</sup>. The procedure of PRF preparation consisted of withdrawing 10 ml of intravenous blood from the antecubital fossa. The blood was transferred into 10 ml sterile tube without anticoagulant and immediately centrifuged at 3000 rpm for 10 minutes. Fibrin clot formed in between the acellular plasma on top and the red blood cells at the bottom was separated using sterile tweezers and scissors. The PRF membrane is placed over the titanium mesh and black silk 3-0 sutures were placed. (Fig 9 & 10)

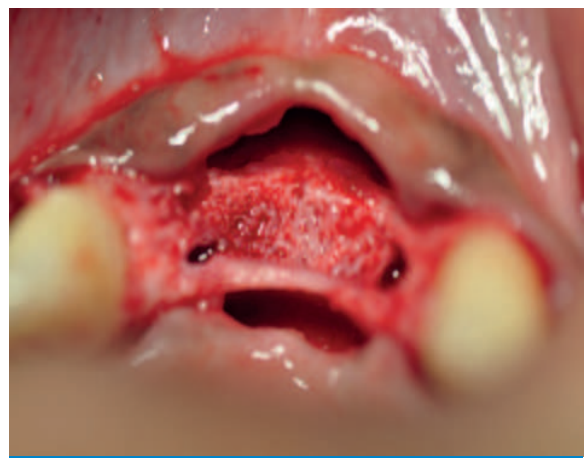

Figure - 11

The titanium mesh was removed at the end of 4 months as there was a slight exposure of the mesh. A crestal incision was placed and the buccal and lingual flaps were elevated. Then the screws were loosened and the titanium mesh was removed from the bone. There was an increase in a ridge width of 2 mm and height by 4-5 mm (Fig 11 & 12). The flap was sutured after removal of the mesh. At the end of six months the patient was recalled and subsequently 11 was also extracted and implants of dimension 3.25 X 13mm were placed in relation to 11, 21 (Fig 13). PRF was placed subsequently around the implants to enhance the regeneration (Fig 14) and sutures were placed.

Subsequently healing collars were placed after 6 months. After obtaining a sufficient emergence profile, impressions were made and the final prosthesis was given. (Fig 15)

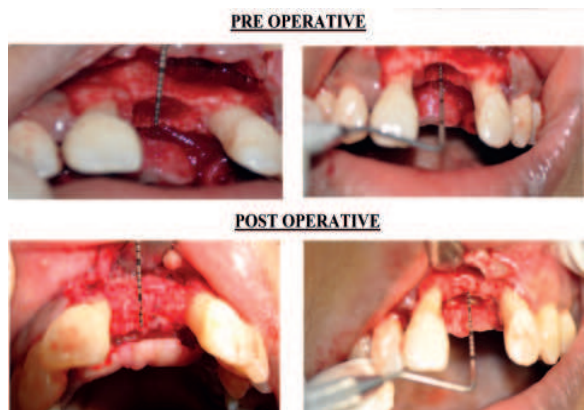


Figure - 12

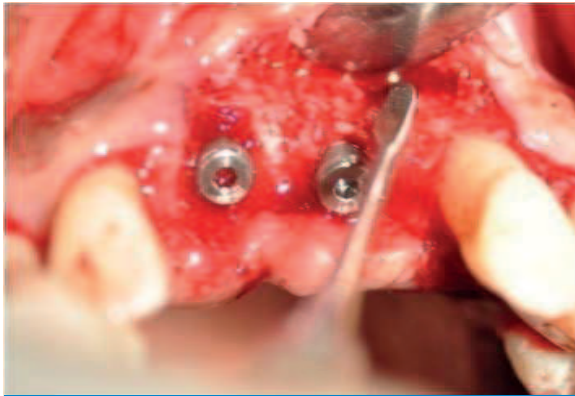


Figure -13

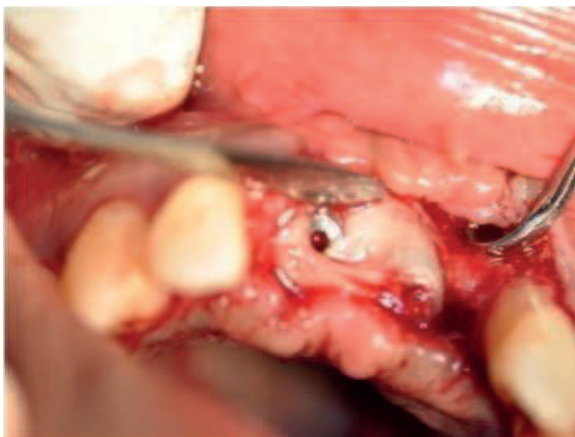


Figure -14

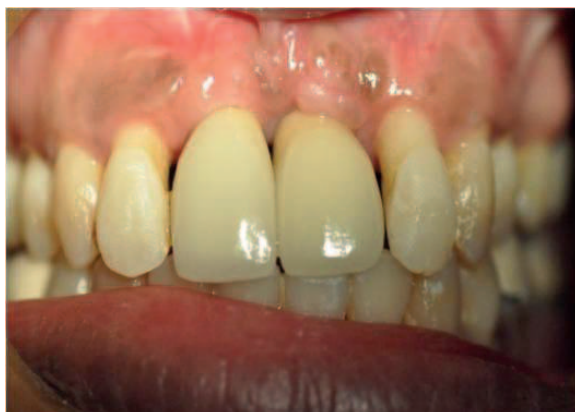

Figure -15

## Discussion

The use of barriers made of titanium macro-mesh in combination with bone grafts and bone substitutes has been proposed and tested for the partial and full augmentation of the alveolar process in implant surgery. The regeneration of localized alveolar ridge following extraction of chronic defects has been the goal of clinicians and researchers. Bone loss occurs in chronic inflammation, and in post extraction cases where no socket preservation procedure was attempted which results in difficulty for patients wearing a conventional prosthesis or being restored with dental implants. Severe alveolar bone loss can result in malnutrition, poor self-esteem, multiple dental visits for failed prosthesis, and jaw fracture.

Vertical and horizontal bone augmentation can be successfully performed to gain bone height and width that is essential for ideal implant positioning and esthetic outcomes using variety of techniques.

Titanium mesh has some distinct advantages as a barrier membrane. Its rigidity resists deformation by the overlying soft tissue. Because it is non-resorbable it is present throughout the healing phase of the graft. Last, it causes little soft tissue reaction even when it is exposed. This is important because all membranes can become exposed during healing, and this can be especially common for titanium mesh. A layer of pseudo periosteum is constantly observed under the mesh. Though titanium mesh exposure was reported in 51.11%, the success of bone grafting was not reduced, owing to the success rate of 97.72%<sup>9</sup>.

In this patient, though the prognosis was hopeless in both 21 and 11, initially only 21 was extracted, as the bone loss was maximum around 21 and required augmentation. The titanium mesh can be beneficial only in isolated areas of ridge defects than wide defects.

In the present case there was titanium mesh exposure at the end of 4 months and hence the decision to remove the mesh was made. Von Arx, et al. reported 10 out of 20 patients had exposure of the mesh. Of those patients only three had less than 10% of the graft volume lost. However, implants were successfully placed in 19 of the 20 patients<sup>5</sup>. Torres, et al, in a prospective study, showed a benefit of using platelet-rich plasma (PRP) to reduce mesh exposure<sup>10</sup>. In the present case we used Platelet rich fibrin to prevent the mesh exposure.

Currently, PRF has been successfully tested in a number of procedures including maxillofacial surgery, periodontal surgery, and implantology. In a previous study, the authors were able to demonstrate that PRF could stimulate new bone formation in areas that were previously deficient of the amount of bone required for implant placement<sup>11</sup>. The biomaterial acts by releasing high-concentration growth factors to the wound site, thereby stimulating healing and new bone formation<sup>12</sup>.

A clinical and radiographic study demonstrated significant bone regeneration with mean horizontal and vertical augmentation of  $3.71 \pm 1.24$ mm and  $4.16 \pm 0.59$  mm respectively<sup>13</sup>. Histologic studies have demonstrated the presence of woven bone adjacent to lamellar which is indistinguishable from normal bone architecture<sup>3</sup>.

## Conclusion

The case report illustrated the successful combined surgical approach for three dimensional augmentation of alveolar ridge using autogenous bone graft, titanium mesh and Platelet Rich Fibrin prior to implant placement.

## References

- 1) Keller EE, Tolman DE. Surgical prosthodontic reconstruction of advanced maxillary bone compromise with autogenous onlay block bone grafts and osseointegrated endosseous implants: a 12 year study of 32 consecutive patients. *Int J Oral Maxillofac implants* 1994;14:197-209.
- 2) Louis PJ. Vertical ridge augmentation using titanium mesh. *Oral Maxillofac Surg Clin North Am.* 2010 Aug;22(3):353-68
- 3) Jihad Khamees, Mohammed Ated Darwiche et al. Alveolar ridge augmentation using chin bone graft, bovine bone mineral, and titanium mesh: Clinical, histological, and histomorphometric study. *Journal of Indian Society of Periodontology* Apr – Jun 2012; Vol 16(2): 235-240.
- 4) Boyne PJ, Cole MD, Stringer D, et al: A technique for osseous restoration of deficient edentulous maxillary ridges. *J Oral Maxillofac Surg* 43: 87, 1985.
- 5) Louis PJ. Vertical ridge augmentation using titanium mesh. *SROMS* 19.1:1-14
- 6) Mishal Piyush Shah and Sheela Kumar Gujjari. Alveolar ridge augmentation utilizing platelet rich fibrin in combination with demineralized freeze-dried bone allograft – a case report. *International Journal of Basic and Applied Medical Sciences* 2013; Vol. 3 (1) :18-23.
- 7) Anshul Chugh, Poonam Bhinsoi, Divya Kalra, Sarita MAggi, Virendra Singh. Comparative evaluation of 3 different methods for evaluating alveolar ridge dimension prior to implant placement: an in vivo study. *Journal of Dental implants* 2013; 3(2): 101-110.
- 8) Choukroun J, Diss A and Simonpieri A. Platelet-rich fibrin (PRF): a second-generation platelet concentrate. Part V: histologic evaluations of PRF effects on bone allograft maturation in sinus lift. *Oral Surgery Oral Medicine Oral Pathology Oral Radiology Endod* 2006;101: 299-303.
- 9) Louis PJ, Gutta R et al. Reconstruction of maxilla and mandible with particulate bone graft and titanium mesh for implant placement. *J Oral Maxillofac* 2008; 66:235-245.
- 10) Torres J, Tamimi F, Alkhraisat MH, et al: Platelet-rich plasma may prevent titanium-mesh exposure in alveolar ridge augmentation with anorganic bovine bone. *J Clin Periodontol* 2010; 37: 943
- 11) Mazor Z, Horowitz R, Corso M, Prasad H, Rohrer M and Ehrenfest D (2009). Sinus floor augmentation with simultaneous implant placement using Choukroun's platelet-rich fibrin as the sole grafting material: a radiologic and histologic study at 6 months. *Journal of Periodontol* 80 2056-2064.
- 12) Kang Y, Jeon S and Park J. Platelet-rich fibrin is a Bioscaffold and reservoir of growth factors for tissue regeneration. *Tissue Engineering* 2011; 17: 349-359.
- 13) Francesco Pieri, Giuseppe Corinaldesi et al. Alveolar Ridge Augmentation With Titanium Mesh and a Combination of Autogenous Bone and Anorganic Bovine Bone: A 2-Year Prospective Study. *J Periodontol* 2008;79:2093-2103.

### Informed Consent

According to a report published in the February 20 issue of the *New England Journal of Medicine (NEJM)*, the leading experts on bioethics are of the opinion that the full informed consent is not required for certain types of health research. They have argued that the time consuming process is not only unnecessary for patient protection but may even be harmful if it acts as a hindrance to gaining the new knowledge that might benefit the patient. They have suggested the inclusion of patients in large numbers on the Ethics committees. The two situations where the experts feel Informed consent is unnecessary are: 1) research that is determined to have no negative effects on clinical or other outcomes or values that matter to patients and will proceed without consent but with "public notification" to the patient community in the healthcare system; 2) research determined to have minor but still Meaningful effects on patients' interests, will proceed with specific notification to affected patients, who will have an option to decline participation. (<http://www.news-medical.net/news/20140221/Informed-consent-is-not-required-for-certain-health-research-saybioethics>)

- Dr. K. Ramesh Rao