

Case Report

An Interesting Case of Salbutamol Overdose

Sreelatha B*, SurjakantaThounaojam **

*Senior Resident, **Junior Resident Department of Pediatrics, Vinayaka Mission's Medical College, Karaikal, Puducherry, India



Dr. Sreelatha completed her undergraduation from Govt. Kilpauk Medical College, Chennai and Post graduation from Govt. Stanley Medical College, Chennai. She is currently working as Senior Resident in the Department Of Pediatrics at Vinayaka Mission's Medical College & Hospital, Karaikal. Her areas of interest are developmental pediatrics and pediatric infectious diseases.

Corresponding author - Sreelatha B (sreelathavenkat@gmail.com)

Chettinad Health City Medical Journal 2016; 5(2): 92 - 93

Abstract

Accidental ingestion of salbutamol respiratory solution has not been reported in children. The case reported here had junctional tachycardia, hypertension with wide pulse pressure and hypokalemia following ingestion of 1.25mg/kg of salbutamol two doses at 6 hours interval. The child improved completely with gastric decontamination and oral propranolol.

Key Words: Hypertension, Hypokalemia, Junctional tachycardia, Propranolol, Salbutamol

Introduction

Salbutamol is commonly used as rescue medication in the treatment of childhood asthma. Lower concentrations are available as oral medication in syrup (1-2mg/5ml) or tablet (2-4mg) formulations and as metered dose inhalational medication (100mcg/puff). Higher concentrations are seen in respirator solutions (5mg/ml) which are delivered using nebulizers. The respirator solutions are available commercially in respules and small volume bottles. Accidental overdose of salbutamol is reported in children^{1,2}. Toxicity occurs after ingestion of more than 1mg/kg/dose³. Common symptoms and signs of overdose are agitation, vomiting, tachycardia, widened pulse pressure, hyperglycemia, low serum carbon dioxide and hypokalemia³. Fever⁴ and metabolic acidosis⁵ are infrequently reported and hypertension has not been reported in salbutamol overdose.

Case Report

A 9yrs old female child, an intermittent seasonal wheezer presented to the casualty early in the morning with palpitation of three hours duration. The child is a known case of intermittent asthma since 3yrs of age. She was not on any preventive therapy or any alternative medicine for her illness. She was prescribed rescue dose of oral salbutamol in a dose of 0.1mg/Kg to be used at six hours interval during previous episodes of acute exacerbations. For the present exacerbation, the mother had accidentally given the same volume of salbutamol respirator solution (5ml=25mg) two doses 6 hours apart instead of oral syrup (5ml=2mg). The total dose ingested was 2.5mg/Kg over 6 hours.

At the time of presentation, the child was conscious, dizzy, tremulous without pallor, icterus, cyanosis or clubbing. Pulse rate was 170/min without variation when observed with a cardiac monitor, regular, normal volume. Respiratory rate was 21/min abdominothoracic without intercostal or subcostal retractions. Blood pressure was

21/min abdominothoracic without intercostal or subcostal retractions. Blood pressure was 126/78mmHg in right upper limb and 124/78mmHg in left upper limb in supine posture without significant fall in standing position. Temperature was 98.9°F recorded orally. She weighed 20Kg and her height was 129cms. Systemic examination revealed tachycardia, normal heart sounds, without any cardiomegaly or murmurs. Respiratory system examination did not reveal any rhonchi or rales. Abdominal examination was normal without tenderness or distension. Bowel sounds were normally heard. Nervous system examination was normal except for fine tremors of both hands. There was no ataxia or nystagmus. Romberg's sign was negative. Basic investigations revealed normal complete blood count, random blood glucose, urea, creatinine. Serum potassium was low- 2.1mEq/L. Other electrolytes including sodium, chloride were within normal limits. ECG (Figure 1 and 2) showed paroxysmal junctional tachycardia with poorly delineated P wave and narrow QRS.

The child was admitted, clinical parameters, vital signs and ECG were continuously monitored. Blood glucose and serum potassium were monitored 2nd hourly. As the child presented within one hour of ingestion of the second dose and had not vomited previously, she was given single dose of 20g of activated charcoal followed by propranolol 0.25mg/Kg (5mg) two hours after charcoal as the junctional tachycardia persisted. The same dose was repeated once 8 hours later with which the ECG changes reverted. Blood pressure fell to 108/64mmHg at 2 hours after the first dose of propranolol which was maintained for 72 hours without a precipitous fall after the second dose. Hypokalemia was asymptomatic all through and serum potassium was 3.6mEq/L 18 hours after the second dose of propranolol. Blood glucose remained within normal limits throughout the course of hospital stay. There was no wheezing after propranolol use. Child was discharged after 72 hours when her vital signs and ECG were normal.

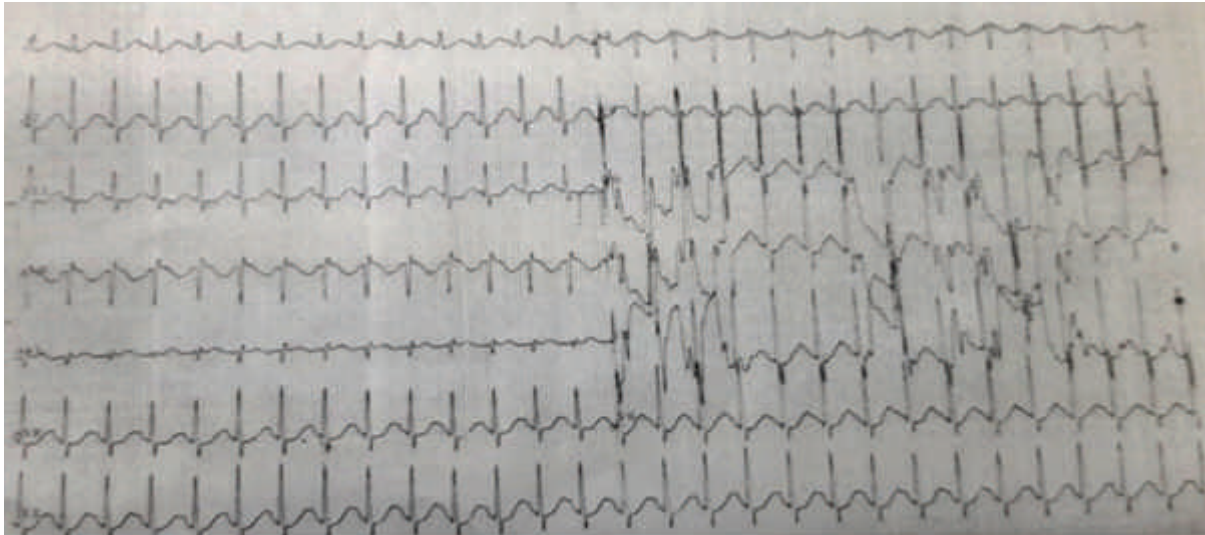


Figure 1 - Ecg Showing Tachycardia , Absent P Waves, Narrow QRS Complexes

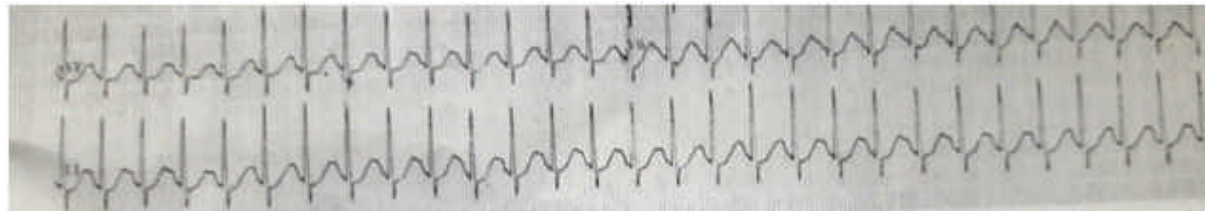

Figure 2 - Rhythm Strip Showing Junctional Tachycardia

Discussion

Salbutamol poisoning is less common in children because of low concentrations in commercially available oral preparations. Use of β -adrenergic blockers has been suggested as helpful in patients with severe toxicity. But it is very rare that a child with salbutamol ingestion will ever need β -blocker administration⁶. Junctional tachycardia and hypertension are hitherto unreported in salbutamol overdose in children. Heart rates less than 180 beats per minute need to be differentiated from simple sinus tachycardia as junctional rhythms require treatment and sinus tachycardia due to salbutamol overdose needs only monitoring until the drug is eliminated from the body. The lack of variation of heart rate with time and respiration and typical superimposed "p" waves in ECG suggested junctional rhythm in the present case. Hypertension reported in this case is not a direct effect of salbutamol but could be a response to maintain the peripheral vascular resistance. Propranolol is superior to atenolol in alleviating the cardiovascular and hypokalemic effects of salbutamol overdose⁷ despite the risk of bronchospasm in asthmatic children. The benefit of propranolol in reverting arrhythmia outweighed the risk of bronchospasm and hence used in this case. But there was no bronchospasm as feared. Hypokalemia though was severe did not present with symptoms. Correction was not attempted as there were no symptoms or signs of hypokalemia clinically and shift of intracellular potassium to the extracellular compartment was expected. In the presence of tachyarrhythmia, supplementation of oral potassium may also be hazardous. Higher concentration solutions and similarity between various drug delivery formulations predispose to unintentional poisoning in children.

References

- 1) Spiller HA, Ramoska EA, Henretig FM, Joffe M A two-year retrospective study of accidental pediatric albuterol ingestions. *Pediatric emergency care* 9:6 1993 Dec pg 338-40
- 2) M Riordan, G Rylance, K Berry Poisoning in children 3: Common medicines *Arch Dis Child* 2002;87:400-402
- 3) Wiley, James F. II MD; Spiller, Henry A. RN, MS; Krenzel OK, Edward P. PharmD; Borys, Douglas J. BS Pharm. Unintentional albuterol ingestion in children. *Pediatric Emergency Care*: 1994;10:193-196.
- 4) Yilmaz, HL, Kucukosmanoglu O, Hennes H, Celik T. Salbutamol intoxication: is salbutamol a drug-inducing fever? A case report and treatment strategy. *Eur J Emerg Med*. 2002;9:179-182.
- 5) R P S Tomar, Lt Coland R. Vasudevan, Col, Metabolic acidosis due to inhaled salbutamol toxicity: A hazardous side effect complicating management of suspected cases of acute severe asthma *Med J Armed Forces India*. 2012 Jul; 68(3): 242-244.
- 6) Gupta S, "common drug poisoning" *Indian Journal of Practical Pediatrics* 2009; 11(1): 35
- 7) Minton, N., Bair AR & Henry, Modulation of the effects of salbutamol by propranolol and atenolol *J.A. Eur J Clin Pharmacol* (1989) 36: 449-453.