

Case Report

An Unusual Cause of Hemifacial Spasm

Rahul Nimmakayala*, Natarajan V**, Subramaniyan K***, Devprasad M***

*DM Post Graduate, **Professor & HOD, ***Associate Prof, Department of Neurology, Chettinad Super Speciality Hospital, Chettinad Academy of Research & Education, Chennai, India.



Dr. Rahul Nimmakayala is pursuing his postgraduation in D.M Neurology at Chettinad Hospital & Research Institute. He completed his M.D (Gen.Med) at B.T.G.H Gulbarga.

Corresponding author - Dr. Rahul Nimmakayala - (drrahulnimmakayala@gmail.com)

Chettinad Health City Medical Journal 2017; 6(1): 33 - 34

Abstract

Hemifacial spasm is a hyperactive rhizopathy of the seventh cranial nerve. It is usually ascribed to vascular compression of the facial nerve at the root exit zone. Tumors, vascular malformations are unusual causes of hemifacial spasms. We report one young adult presenting with hemifacial spasms as a sole manifestation. On imaging it was found to be having large cerebellopontine angle epidermoid cyst and was managed surgically. He had good relief of hemifacial spasms after surgery. Hemifacial spasms as a sole presentation of cerebellopontine angle epidermoid cyst is relatively rare. Only few cases are reported in the literature. Patients with hemifacial spasms should have imaging to exclude structural causes at the cerebellopontine angle and brainstem.

Key Words: Hemifacial Spasm, Cerebellopontine Angle Tumour, Epidermoid Cyst

Introduction

Hemifacial Spasm is the most common hyperactive cranial rhizopathy characterized by involuntary contractions of the muscles (spasms) on one side of the face (hemifacial). It is generally the result of vascular loop compression of the facial nerve at its root exit zone from the brainstem. It may also be associated with other organic lesions like tumors, aneurysms, vertebral artery dolichoectasia, cerebral infarctions, multiple sclerosis plaques, etc. Although the occurrence of tumor compression causing hemifacial spasms was recognized, cerebellopontine angle epidermoid cysts have rarely been described^{1,2}. Herein, we report one such case with a cerebellopontine angle epidermoid cyst having hemifacial spasms as the sole presenting complaint.

Case report

A 28-year male was admitted to the hospital with the complaint of intermittent twitching of the muscles on the right side of his face. These involuntary spasms occurred repetitively within 1-2 hrs intervals for a day. The spasms were also observed during physical examination. There was no alteration of consciousness or associated involuntary movements of any other body parts of his body during the spasms. He had no history of convulsion, neurotrauma or developmental delay in childhood. There was no family history of neurological disease. The neurological examination was normal.

Magnetic resonance imaging (MRI) of the brain was requested. It revealed a well-demarcated cyst [hypointense on T1-weighted imaging and hyperintense on T2-weighted imaging] in the right cerebellopontine cistern. To differentiate between epidermoid cyst

and arachnoid cyst, diffusion-weighted imaging (DWI) was done. It was hyperintense on DWI. (Fig 1).

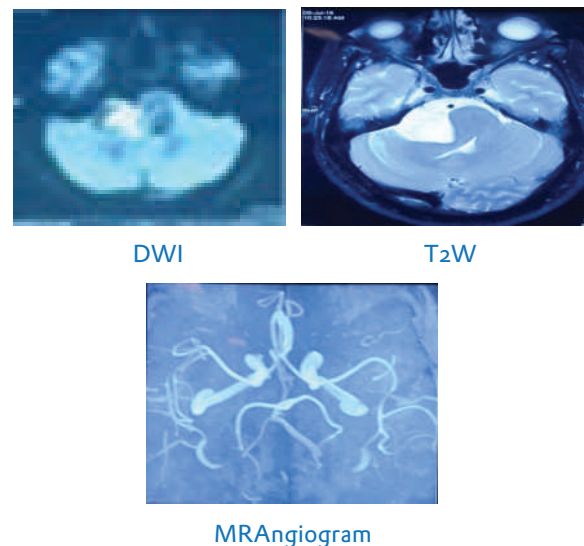


Fig 1 : Evaluation by different imaging modalities

The results of the laboratory tests including hemogram, biochemical tests were normal. The patient was informed about his disease and advised to have neurosurgery treatment option. He was operated with the retrosigmoid (lateral suboccipital) approach in neurosurgery department. The diagnosis was also confirmed histologically. Hemifacial spasm completely disappeared after the surgery.

Discussion

Hemifacial Spasms is a hyperactive rhizopathy of the seventh cranial nerve. Hemifacial Spasms are frequently caused by vascular compression at the root exit zone of the facial nerve. Besides compressive neurovascular structures, it can also be caused by other organic lesions like tumors. The incidence of tumor - related Hemifacial Spasms is very low (0.3–2.5%)^{1,3-5}. The main tumors found in cistern of the cerebellopontine angle are vestibular schwannomas, meningiomas, and epidermoid cysts. The epidermoids represent 0.2-1.8% of all primary intracranial tumors, and approximately 5% of all masses encountered in cerebellopontine angle⁶.

Typical MRI appearance of an epidermoid tumor is hypo to slight hyperintense on T1W images, iso to hyperintense on T2W images, and hyperintense on DWI.^{7,8} Arachnoid cysts appear as hypointense on T1W images and hyperintense on T2W images. However, DWI is an important technique to differentiate epidermoid cysts and arachnoid cysts. In case of an arachnoid cyst, DWI reveals a hypointense lesion, which is isointense to CSF. However, epidermoid cysts appear hyperintense on DWI as in our case⁸. It is due to T2 shine-through which refers to high signal on DWI that is not due to restricted diffusion, but rather to high T2 signal which shines through to the DWI and because of long T2 decay time.

Clinicians need to be aware that patients with Hemifacial Spasm should be scanned for brainstem lesions. MRI studies are essential to detect the vascular structures running adjacent to the root exit zone that might distort the facial nerve and compress the brain stem around the root exit zone, and to exclude other organic causes like tumors, Multiple Sclerosis plaques or cystic lesions. As in our case, an epidermoid cyst in cerebellopontine cistern, compressing the pons, which contains the nuclei and root exit zone of the facial nerve, may present with Hemifacial Spasms as the sole symptom.

References

- 1) Glocker FX, Krauss JK, Deuschl G, Seeger W, Lücking CH. Hemifacial spasm due to posterior fossa tumors: The impact of tumor location on electrophysiological findings. *Clin Neurol Neurosurg.* 1998;100(2):104–11.
- 2) Kobata H, Kondo A, Iwasaki K. Cerebellopontine angle epidermoids presenting with cranial nerve hyperactive dysfunction: Pathogenesis and long-term surgical results in 30 patients. *Neurosurgery.* 2002;50(2):276–85.
- 3) Han H, Chen G, Zuo H. Microsurgical treatment for 55 patients with hemifacial spasm due to cerebellopontine angle tumors. *Neurosurg Rev.* 2010;33(3):335–9.
- 4) Nagata S, Matsushima T, Fujii K, Fukui M, Kuromatsu C. Hemifacial spasm due to tumor, aneurysm, or arteriovenous malformation. *Surg Neurol.* 1992;38(3):204–9.
- 5) Felício AC, Godeiro-Junior Cde O, Borges V, Silva SM, Ferraz HB. Bilateral hemifacial spasm: A series of 10 patients with literature review. *Parkinsonism Relat Disord.* 2008;14(2):154–6.
- 6) Liu P, Saida Y, Yoshioka H, Itai Y. MR imaging of epidermoids at the cerebellopontine angle. *Magn Reson Med Sci.* 2003;2(3):109–15.
- 7) Kallmes DF, Provenzale JM, Cloft HJ, McClendon RE. Typical and atypical MR imaging features of intracranial epidermoid tumours. *AJR Am J Roentgenol.* 1997;169(3):883–7.
- 8) Bonneville F, Sarrazin JL, Marsot-Dupuch K, Iffenecker C, Cordoliani YS, Doyon D, et al. Unusual lesions of the cerebellopontine angle: A segmental approach. *Radiographics.* 2001;21(2):419–38.